

Diffuse normolipemic plane xanthomas in a healthy male infant

Maryam Emad, MD ¹
Fatemeh Sari Aslani, MD ¹
Nasrin Saki, MD ¹
Dorna Motevalli, MD ¹
Forugh Saki, MD ²

1. Skin Research Center, Dermatology Department, Shiraz University of Medical Sciences, Shiraz, Iran
2. Pediatric Department, Shiraz University of Medical Sciences, Shiraz, Iran

Corresponding Author:
Nasrin Saki, MD
Skin Research Center, Dermatology Department, Shiraz University of Medical Sciences, Shiraz, Iran
Email: nasrinsa85@yahoo.com

Conflict of interest: none to declare

Received: 14 August 2011
Accepted: 5 September 2012

Diffuse normolipemic plane xanthoma is characterized by the presence of yellowish-orange plaques on the eyelids, neck, upper trunk, buttocks and flexural surfaces of the extremities in patients with a normal lipid profile. It mainly affects adults of both sexes. Diffuse normolipemic plane xanthomas are usually associated with reticuloendothelial system disorders, such as multiple myeloma and monoclonal gammopathies. We report a case of diffuse plane xanthomas in an otherwise healthy 1-year-old male infant who developed multiple disseminated non-inflammatory yellowish-orange macules and patches that were not associated with any other symptoms.

Keywords: diffuse plane xanthoma, histiocytosis, infantile, serum lipid

Iran J Dermatol 2012; 15: 137-140

INTRODUCTION

Diffuse normolipemic plane xanthoma refers to the presence of yellowish-orange plaques on the eyelids, neck, upper trunk, buttocks and flexural surfaces of the extremities but in such cases, the levels of serum lipids are usually normal ^{1,2}.

Diffuse normolipemic plane xanthoma was first described by Altmann and Winkelmann in 1962 and has been associated with reticuloendothelial system diseases, such as multiple myeloma and monoclonal gammopathies (approximately one-half of all patients), lymphoproliferative diseases, including acute myeloid leukemia (M5), chronic myeloid leukemia, lymphoma, Sezary syndrome, Waldenstrom's macroglobulinemia, Castleman's disease, cryoglobulinemia, lymphosarcoma, histiocytosis X and amyloidosis ³⁻⁶. According to the literature, only a minority of cases are reported

as idiopathic, which may be due to neglecting idiopathic cases by the authors ⁷⁻⁹.

Treatment for diffuse plane xanthomatosis includes excision or ablative laser therapy, chemabrasion, and dermabrasion. Sussane Lorenz et al, reported a 23-year-old lady with diffuse plane xanthomas of the face and neck that was removed by Erbium: YAG laser ¹⁰.

Normolipemic plane xanthoma usually occurs in adulthood. To Our knowledge, only one pediatric case has been reported in literature, who was a 9-year-old boy without any lipid disorders.

CASE REPORT

A 1-year-old male infant presented to the dermatology center of Faghihi Hospital (Shiraz University of Medical Sciences) in December 2010 with a 3-month history of multiple disseminated

non-inflammatory yellowish-orange macules and patches that were not associated with any other symptoms (Figure 1,2). The lesions were mostly located on the abdomen, back, neck, and face.

There was no family history of hyperlipidemia, liver disease, gammopathies or lymphoproliferative disorders. The patient’s physical examination was completely normal. The baseline lab data including complete blood count, blood urea nitrogen, creatinine, electrolytes, erythrocyte sedimentation rate (ESR), liver function tests, and immunoglobulin profile were also normal. The patient is under follow up; yet, no other lab or clinical abnormality has been observed within the 1-year follow-up.

The patient had no past history of medical problems. He was breast fed with a negative history of taking any medications.

A 4mm punch biopsy was taken from one of the

lesions on the abdomen. Microscopic examination showed normal epidermis and varying sized aggregates of foamy histiocytes in the entire dermis between collagen bundles and around pilosebaceous structures. No foreign body or Touton giant cells were present. There was no perivascular inflammation or fibrosis. Also, there was no evidence of lymphoreticular hyperplasia. The histologic picture was in favor of plane xanthoma. (Figure 3,4)

These findings were consistent with diffuse normolipemic plane xanthoma. It is necessary to perform further follow-up for patients with diffuse plane xanthomatosis because normolipemic plane xanthomas are often accompanied by myeloproliferative disorders such as leukemia, paraproteinemia, or lymphoma which may appear even years after skin manifestations. Therefore, our patient is under long-term clinical follow-up.

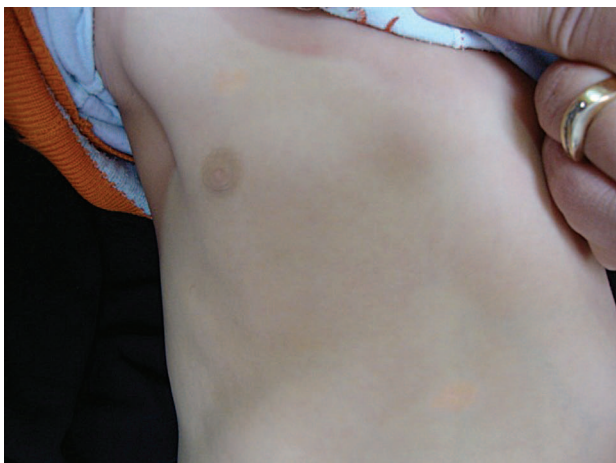

Figure 1. Two plane xanthomas on the abdomen and above nipple.

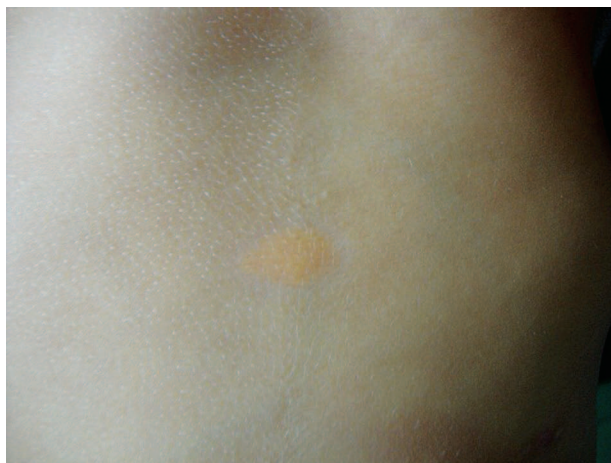

Figure 2. Larger view of the plane xanthoma on the abdomen

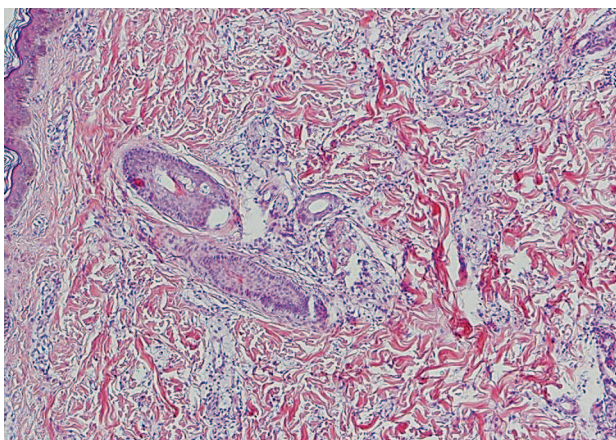


Figure 3. Normal epidermis and several aggregates of foamy histiocytes throughout the dermis (H&E x100).

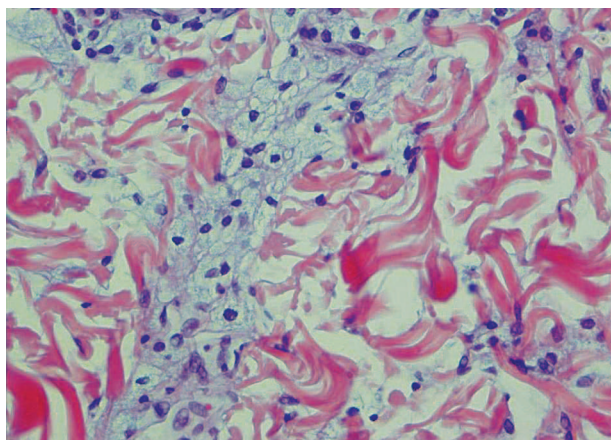


Figure 4. Aggregate of histiocytes with abundant vacuolated cytoplasm and central vesicular nuclei (xanthoma cells) between collagen bundles (H&E x400).

DISCUSSION

Diffuse plane xanthomatosis is an uncommon type of xanthomatosis that mostly occurs in adults of both genders and is characterized by generalized yellowish-orange plaques in patients with normal lipid profiles.

Xanthomatous lesions usually appear on the eyelids, neck, upper trunk, buttocks and flexural surfaces of the extremities and are usually symmetrically distributed. However, the lesions can involve any part of the body.

Age of onset depends on the underlying disease and may vary from 40 to 60 years and very rarely occurs in other age groups³⁻⁵. Our case is an otherwise healthy 1-year-old male infant who developed multiple disseminated non-inflammatory yellowish-orange macules and patches that was not associated with any other symptoms.

Generally, diffuse plane xanthoma can be categorized into two groups: group 1 includes patients with elevated serum lipoprotein levels whereas the second group has a normolipid profile which can be further classified into 3 subtypes:

- idiopathic diffuse plane xanthomas
- associated with multiple myeloma, monoclonal gammopathies and other underlying lymphoproliferative disorders
- associated with abnormalities of the structure and content of lipoproteins¹¹.

Regarding this classification, our patient was a case of idiopathic diffuse plane xanthoma. According to Parker's classification, Normocholesterolemic xanthomatosis can be grouped into three categories. Type I includes patients with an altered lipoprotein content or structure. Type II is associated with underlying lymphoproliferative disorders and type III includes those patients without identifiable lipoprotein abnormalities or associated underlying systemic diseases but in these patients, local tissue alterations (local tissue lipid synthesis, trauma and inflammation of the skin) seem to play a role in xanthoma formation¹². Our patient did not match with the characteristics of any types of Parker's classification.

Diffuse plane xanthomatosis has been linked to many disorders such as monoclonal gammopathy, cryoglobulinemia, and myeloproliferative disorders⁷. The pathogenesis of normolipemic plane xanthomas has not been defined clearly

but in cases of multiple myeloma, it is shown that lipoprotein-paraprotein complexing in some patients may be the result of auto-antibody activity of the myeloma protein against serum lipoprotein; immune complexes that interfere with normal lipoprotein catabolism and therefore bring about xanthomas with normolipemia or hyperlipemia¹³. Some authors have postulated that the infiltration of leukemic cells in the skin predisposes the tissue for xanthomatization¹⁴.

Histologically, plane xanthomas are characterized by infiltration of foamy macrophages in the entire dermis with distinct perivascular localization. Oil Red O and scarlet red stains are used for confirmation of the presence of neutral fat¹⁵.

The treatment options in the literature are excision or ablative laser therapy, chemabrasion and dermabrasion¹⁰. Since cosmetic problems were not considered medically necessary, we did not recommend excisional surgery or ablative laser therapy for our patient.

Only a minority of cases is regarded as idiopathic and most of the reports have described diffuse normolipemic plane xanthoma in adults. To our knowledge, there is only one report of a pediatric case with diffuse plane xanthomatosis, a 9-year-old boy with disseminated, flat, yellow-brown plaques without any systemic involvement or lipid disorders⁸. Our patient is under regular clinical follow-up and periodic laboratory examinations because diffuse plane xanthomatosis can precede the occurrence of an associated disease, especially myeloproliferative disorders, such as leukemia, paraproteinemia, or lymphoma. In our patient, there is no evidence of any underlying diseases or new problems after 1 year.

REFERENCES

1. Altman J, Winkelmann RK. Diffuse normolipemic plane xanthoma. Generalized xanthelasma. *Arch Dermatol* 1962;85:633-40.
2. Jordon RE, McDuffie FC, Good RA, et al. Diffuse normolipemic plane xanthomatosis. An abnormal complement component profile. *Clin Exp Immunol* 1974;18:407-15.
3. Lynch PJ, Winkelmann RK. Generalized plane xanthoma and systemic disease. *Arch Dermatol* 1966;93:639-46.
4. Buezo GF, Porras JI, Fraga J, et al. Coexistence of diffuse plane normolipemic xanthoma and amyloidosis in a patient with monoclonal gammopathy. *Br J Dermatol* 1996;135:460-2.

5. Akhyani M, Daneshpazhooh M, Seirafi H, et al. Diffuse plane xanthoma in an otherwise healthy woman. *Clin Exp Dermatol* 2001;26:405-7.
6. Bragg J. Diffuse plane xanthomata. *Dermatol Online J* 2005;11:4.
7. Marcoval J, Moreno A, Bordas X, et al. Diffuse plane xanthoma: Clinicopathologic study of 8 cases. *J Am Acad Dermatol* 1998;39:439-42.
8. Hofmann M, Zappel K, Trefzer U, et al. Diffuse normolipemic plane xanthoma in a 9-year-old boy. *Pediatr Dermatol* 2005;22:127-9.
9. Silva DM, Chacha JJ, Wiziack et al. Diffuse plane idiopathic normolipemic xanthoma with hypersplenism. *An Bras Dermatol* 2010; 85:73-6.
10. Lorenz S, Hohenleutner S, Hohenleutner U, et al. Treatment of diffuse plane xanthoma of the face with the Erbium:YAG laser. *Arch Dermatol* 2001;137:1413-5.
11. Daoud MS, Lust JA, Kyle RA, et al. Monoclonal gammopathies and associated skin disorders. *J Am Acad Dermatol* 1999;40:507-35.
12. Parker F. Xanthomas and hyperlipidemias. *J Am Acad Dermatol* 1985;13:1-30
13. Taylor JS, Lewis LA, Battle JD Jr, et al. Plane xanthoma and multiple myeloma with lipoprotein-paraprotein complexing. *Arch Dermatol* 1978;114:425-31.
14. Vail JT Jr, Adler KR, Rothenberg J. Cutaneous xanthomas associated with chronic myelomonocytic leukemia. *Arch Dermatol* 1985;121:1318-20.
15. Broeshart JH, Prens EP, Habets WJ, et al. Normolipemic plane xanthoma associated with adenocarcinoma and severe itch. *J Am Acad Dermatol* 2003; 49:119-22.