

# Sclerotherapy: a bloodless approach in treatment of pyogenic granuloma in children

Manjunath M Shenoy, MD  
Amina Asfiya, MD \*  
Malcolm Pinto, MD

*Department of Dermatology,  
Venereology and Leprosy, Yenepoya  
Medical College, Yenepoya University*

*\*Corresponding author:  
Amina Asfiya, MD  
Department of Dermatology,  
Venereology and Leprosy, Yenepoya  
Medical College, Yenepoya University,  
Deralakatte, Mangalore, India  
Tel: +91 9902335103  
Email: asfiya89@gmail.com*

*Received: 6 February 2020  
Accepted: 26 February 2020*

Pyogenic granuloma (PG) is a common, acquired tumor-like growth occurring on skin/mucous membranes. It is prevalent in the pediatric age group. It is benign in nature and is caused by chronic low grade trauma. It presents as pink to red elevated pedunculated or sessile mass. There are various treatment modalities including surgery, cryotherapy, laser, electrocautery, etc. However, the therapeutic effects are limited with high recurrence rates. The use of sclerotherapy for the treatment of pyogenic granuloma in children is not commonly reported. We present a case of PG on the scalp successfully treated with intralesional injection of sodium tetradecyl sulfate.

**Keywords:** pyogenic granuloma, sclerotherapy, children

Iran J Dermatol 2020; 23: 76-79

## INTRODUCTION

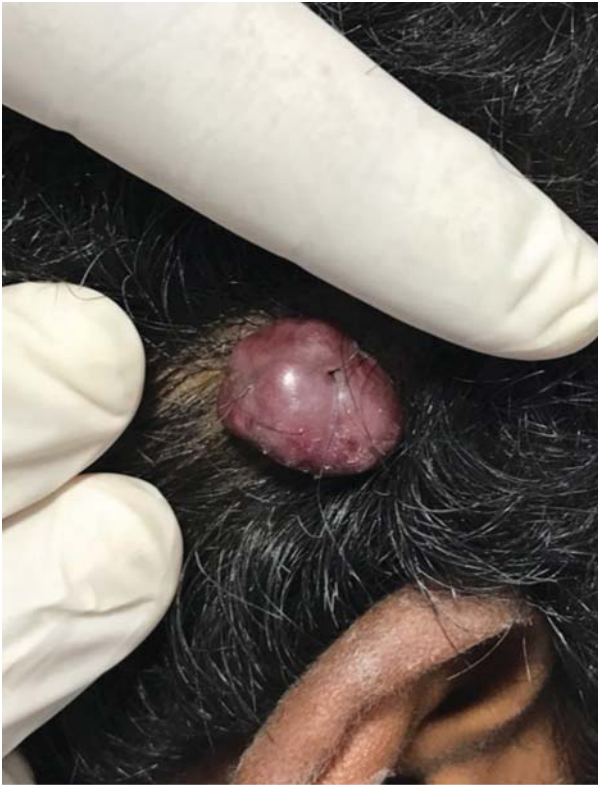Pyogenic granuloma (PG) is a benign vascular tumor, which can present on the skin or mucous membranes. The name is a misnomer, since it does not have an infective etiology nor does it contain granulation tissue. PG grows rapidly to form a red papule or exophytic nodule which has a tendency to bleed profusely on minor trauma. The surface of the lesion is susceptible to bleeding and ulceration<sup>1</sup>. The exact etiology of PG is unknown. It is believed that an unknown stimulus triggers endothelial proliferation and angiogenesis, leading to rapid growth<sup>2</sup>. Various treatment modalities are available, however, none of them is effective. Sclerotherapy is defined as the targeted elimination of small vessels, varicose veins and vascular anomalies by the injection of a sclerosant<sup>3</sup>. Since PG involves the proliferation and growth of blood vessels, sclerotherapy was tried as a treatment modality. Accordingly, we report a case of PG occurring on the scalp in a child successfully treated with sclerotherapy.

## CASE PRESENTATION

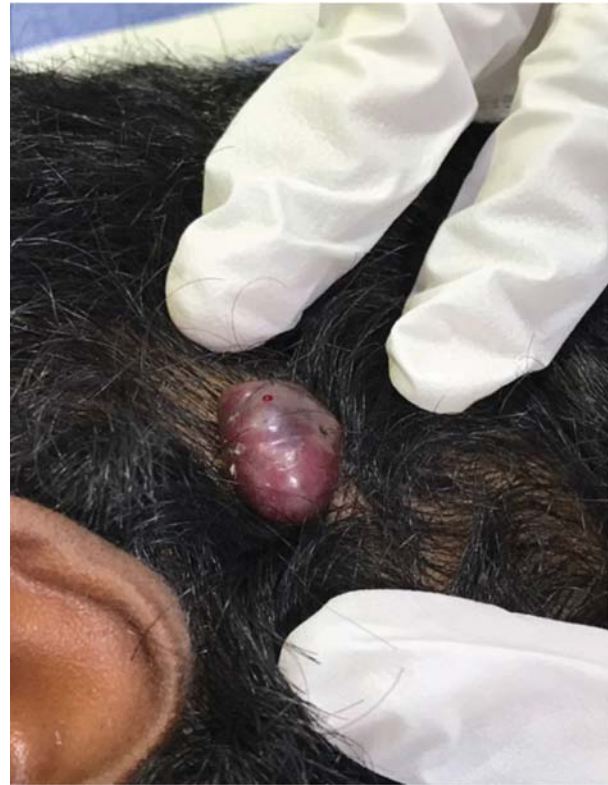A 12-year-old boy presented to the outpatient department with chief complaint of a proliferating lesion over the scalp since 3 months. At the beginning, it started as a small reddish nodule, which progressed rapidly to the present size. It was associated with bleeding on trivial trauma. The bleeding was profuse and stopped only after applying firm pressure for several minutes. There was no history of trauma prior to the onset of the lesion. No history of similar lesions in the past or elsewhere in the body was noted. The patient had not taken treatment elsewhere.

On examination, a single exophytic growth measuring approximately 4 × 4 cm was present over the right temporal scalp. The lesion was pinkish red in color with soft and edematous consistency. Surrounding skin was normal, and the lesion was not attached to the underlying bone (Figure 1).

Based on the history and clinical examination, a provisional diagnosis of pyogenic granuloma was made. The patient was treated with cryotherapy for three sittings; however, there was minimal



**Figure 1.** Pyogenic granuloma at the first visit.



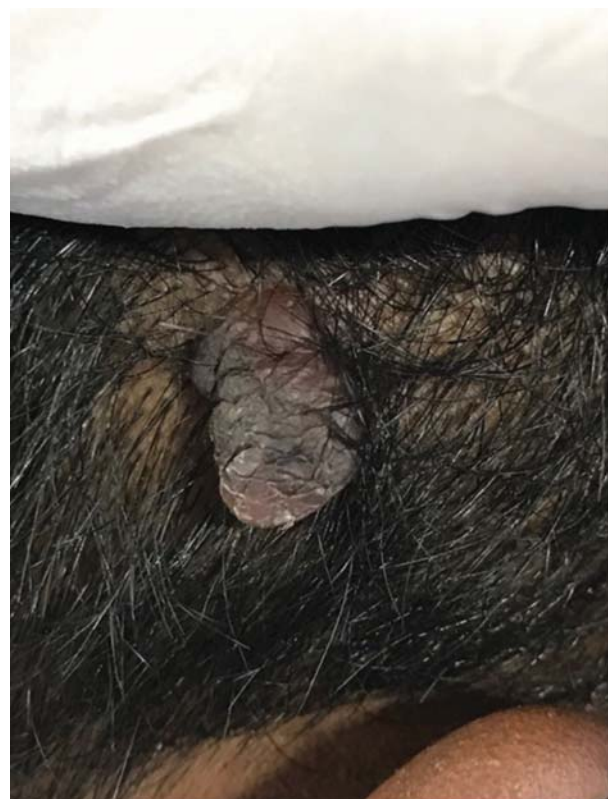
**Figure 2.** Visible blanching after sclerotherapy.

improvement.

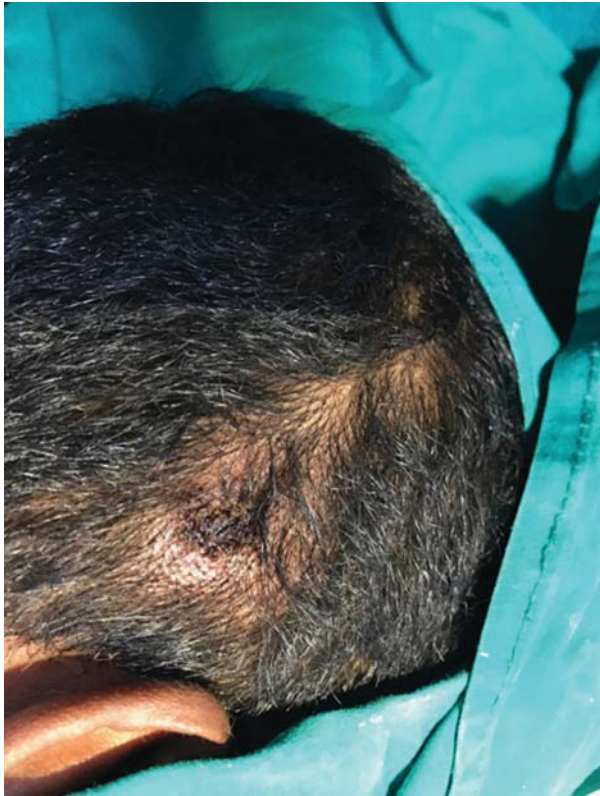Regarding the vascular nature of the lesion, sclerotherapy with sodium tetradecyl sulfate was considered a treatment modality. Informed consent was obtained. The area was cleaned with antiseptic. The procedure was carried out without any local anesthesia. The sclerosant used was 3% sodium tetradecyl sulfate diluted with sterile water in a ratio of 1:4 and injected into the lesion with the help of an insulin syringe. It was given until there was visible blanching of the lesion (Figure 2). Thereafter, pressure was applied with gauze for 3-4 minutes. Minimal bleeding was noted during the procedure. The patient tolerated the procedure well. The injection was repeated at 2 weekly intervals for 4 sittings. The lesion significantly decreased in size at the end of 2 months (Figure 3). No complication was noted after the procedure. Electrocautery was performed to remove the shriveled PG lesion (Figure 4). No recurrence of the lesion was seen even at 6-month follow-up.

## DISCUSSION

Poncet and Dor for the first time described



**Figure 3.** Significant decrease in size after 2 months.



**Figure 4.** Complete resolution of the lesion.

pyogenic granuloma (PG) in 1897<sup>4</sup>. It was earlier known as 'botryomycosis hominis'. Hartzell, in 1904, coined the term 'pyogenic granuloma' (PG) or 'granuloma pyogenicum'; it is also known as Crocker and Hartzell's disease, lobular capillary hemangioma, and granuloma gravidarum (GG) in pregnant women<sup>5</sup>.

Pyogenic granuloma has a worldwide distribution. Although, they occur in any age group, they are more prevalent in children and adolescents. It accounts for 0.5% of all childhood skin nodules. The mean age of onset is 6.7 years in children; with 42% of cases occurring by 5 years of age<sup>6</sup>.

A higher frequency is seen in the second and third decade of life, with a peak prevalence in women. The commonest locations are the lips, tongue, buccal mucosa, gingiva, and palate. Extra-oral sites include the skin of the upper and lower extremities, scalp, face, mucous membrane of the nose, eyelids, and genitalia<sup>7</sup>.

Clinically, it begins as a red solitary lesion, which grows rapidly over weeks to months and then stabilizes in size. It can be pedunculated or sessile and rarely exceeds 1 cm in diameter. PG

can present on the skin or mucosal surface and has a characteristic acanthotic base known as the "epithelial collarette." The lesion is painless, but it can grow rapidly and can bleed on minor trauma<sup>1</sup>.

Although the diagnosis is basically clinical, some differential diagnoses include keratoacanthoma and other epithelial neoplasms, inflamed seborrheic keratoses, melanocytic naevi, melanoma, Spitz nevi, viral warts, molluscum contagiosum, angioma, glomus tumour, eccrine poroma, Kaposi sarcoma and metastatic carcinoma<sup>8</sup>. On histopathological examination, lobular proliferation of small vessels is seen erupting through a break in the epidermis to produce a globular pedunculated tumor<sup>9</sup>. Various treatment modalities include curettage and cauterization, coagulation of the base with diathermy, excision and sutures, cryotherapy with liquid nitrogen or nitrous oxide and lasers<sup>9</sup>. Although sclerotherapy is not a very popular procedure to treat PG, this procedure has been tried with success regarding the vascular nature of the lesion.

The commonly used sclerosants are polidocanol and sodium tetradecyl sulfate owing to their efficacy and safety profile<sup>10</sup>. Some of the complications of sclerotherapy include hyperpigmentation, transient burning pain, telangiectatic matting, cutaneous necrosis, ulceration, thrombophlebitis, pulmonary embolism or inadvertent arterial injection, which are mostly seen with varicose veins and haemorrhoids<sup>11</sup>. Although sclerotherapy is a relatively safe procedure, Nicolau syndrome is a potentially catastrophic complication<sup>12</sup>.

## CONCLUSION

The authors found that sclerotherapy was a novel method to treat pyogenic granuloma and was relatively safe. The technique is painless, bloodless, and economical, requires minimal surgical expertise and can be done as an outpatient procedure. There is no need for local anaesthesia or any dressings after operation. It can be used as an alternative to conventional methods such as surgery, lasers, radiofrequency ablation and electrodesiccation<sup>3</sup>. The method can be employed in the treatment of PG in children, patients with comorbidities, and as an initial treatment for large PG in order to shrink the size of the tumor. Hence, we conclude that sclerotherapy may be tried as treatment modality

in patients with pyogenic granuloma more so in the pediatric population.

**Conflict of Interest:** None declared.

## REFERENCES

1. Gowda D, Owens C. Pyogenic granuloma in an unusual site. *Glob Pediatr Health*. 2017;4:2333794X17704607.
2. Rahman H, Hadiuzzaman. Pyogenic granuloma successfully cured by sclerotherapy: A case report. *J Pakistan Ass Dermatol*. 2014;24 (4):361-4.
3. Sacchidanand S, Purohit V. Sclerotherapy for the treatment of pyogenic granuloma. *Indian J Dermatol*. 2013; 58(1): 77-8.
4. Fekrazad R, Nokhbatolfoghahaei H, Khoei F, et al. Pyogenic granuloma: surgical treatment with Er:YAG laser. *J Lasers Med Sci*. 2014;5(4):199-205.
5. Purwar P, Dixit J, Sheel V, et al. "Granuloma gravidarum": persistence in puerperal period an unusual presentation. *BMJ Case Rep*. 2015;2015:bcr2014206878.
6. Leung AKC, Barankin B, Hon KL. Pyogenic granuloma. *Clin Mother Child Health*. 2014;11(1):e106.
7. Ibrahim A, Asuku ME. Nodular swelling on the lower lip; pyogenic granuloma. *Eplasty*. 2014;14:ic45.
8. Calonje E. Soft-tissue tumours and tumour-like conditions. In: Griffiths C, Barker J, Bleiker T, et al (Eds). *Rook's Textbook of Dermatology*. Edinburgh: Wiley-Blackwell, 2016. 137.26.
9. Chandra B S, Rao P N. Two cases of giant pyogenic granuloma of scalp. *Indian Dermatol Online J*. 2013;4(4):292-5.
10. Khunger N, Sacchidanand S. Standard guidelines for care: sclerotherapy in dermatology. *Indian J Dermatol Venereol Leprol*. 2011;77(2):222-31.
11. Grover C, Khurana A, Bhattacharya SN. Sclerotherapy for the treatment of infantile hemangiomas. *J Cutan Aesthet Surg*. 2012;5(3):201-3.
12. Nirmal B, Segu SS, Sacchidanand SA, et al. Nicolau syndrome following sclerotherapy for pyogenic granuloma. *Indian J Dermatol Venereol Leprol*. 2014;80(5):484.