Frontal fibrosing alopecia: a clinicopathological study of 22 cases from Shiraz, Southern Iran

Fatemeh Sari Aslani, MD [1,2]
Nasrin Saki, MD [1,3]
Mohammad Sasannia, MD [4*]

1. Molecular Dermatology Research Center, Shiraz University of Medical Sciences, Shiraz, Iran
2. Pathology Department, Shiraz University of Medical Sciences, Shiraz, Iran
3. Dermatology Department, Shiraz University of Medical Sciences, Shiraz, Iran
4. Student Research Committee, Shiraz University of Medical Sciences, Shiraz, Iran

*Corresponding author:
Mohammad Sasannia
Student Research Committee, Shiraz University of Medical Sciences, Shiraz, Iran
Phone: +989172615690
Fax: +987132331634
Postal code: 7134845794.
Email: mohammadsasannia@gmail.com

Received: 15 March 2020
Accepted: 11 May 2020

Background: Since its recognition, frontal fibrosing alopecia (FFA) has increasingly been studied globally in terms of its diverse aspects. Having found no studies describing this condition in Southern Iran, we examined the different clinicopathological features of patients with FFA who referred to Faghihi Hospital, Southern Iran, between 2013 and 2018.

Methods: We searched the archives of the Pathology Department of Faghihi Hospital for the cases with a diagnosis of FFA. Due to its similar histopathologic features with lichen planopilaris, the final diagnosis was made using clinical correlations.

Results: Twenty-two patients were enrolled; all were female. Fifteen (68.2%) presented with the disease before menopause. Besides frontal and/or temporal hairline involvement in all the patients, eyebrow alopecia, eyelash loss, body hair loss, and facial papules were present in 81.8%, 27.3%, 50%, and 68.2% of them, respectively. Dermoscopic findings included follicular opening loss (100%), honeycombing of the scalp (81.8%), multiple white dots (77.3%), perifollicular erythema (63.6%), and perifollicular scales (59.1%). The histopathologic examination revealed follicular dropout (95.4%), perifollicular lymphocytic infiltration in the infundibulum and isthmus of the follicles (81.8%), perifollicular fibroplasia (77.3%), intact interfollicular epidermis (59.1%), mild perivascular lymphocytic infiltration in the upper dermis (54.5%), and apoptotic keratinocytes in the infundibulum and isthmus (50%). The most common comorbidity was hypothyroidism (40.9%).

Conclusions: The diagnosis of FFA should be considered in both premenopausal and postmenopausal women. Eyebrow alopecia, eyelash loss, body hair involvement, and facial papules are helpful clues in the diagnosis. The coexistence of hypothyroidism with FFA suggests immunological involvement in the pathogenesis.

Keywords: hair, lichen planus, eyebrows, dermoscopy, pathology

Iran J Dermatol 2020; 23: 112-119

DOI: 10.22034/ijd.2020.111548

INTRODUCTION

Frontal fibrosing alopecia (FFA) is a scarring type of alopecia affecting the hairline in the frontotemporal region [1]. This condition is not limited to the scalp, often involving the eyebrows and, less frequently, eyelashes, beard, and body hair [2-4]. Some patients simultaneously have facial papules [3,5]. It predominantly affects postmenopausal women, yet men and premenopausal women could also be inflicted [2-4].

Frontal fibrosing alopecia shares common

histopathologic features with lichen planopilaris (LPP), making them indistinguishable by pathology [6,7]. These features include: lichenoid interface dermatitis at the level of the follicular infundibulum and isthmus; perifollicular fibroplasia; apoptosis of the external root sheath keratinocytes; and hair follicle destruction [8].

Frontal fibrosing alopecia is associated with various autoimmune disorders, among which thyroid disorders share the highest rate of association [4,5,9]. Other related autoimmune disorders are psoriasis, inflammatory bowel disease, Sjögren syndrome, vitiligo, celiac disease, lichen planus (LP), rheumatoid arthritis (RA), systemic lupus erythematosus, scleroderma, and rosacea [4,5,9].

No definite cure is available for FFA. A range of therapies are provided to control the disease with different outcomes ranging from no effect on disease progression to halting hairline recession and promoting hair regrowth [2]. Such treatments include corticosteroids (systemic, topical, or intralesional), 5-alpha-reductase inhibitors, hydroxychloroquine sulfate, topical calcineurin inhibitors, doxycycline, and mycophenolate [2,4].

Since the introduction of FFA in 1994 by Kossard, a growing body of research has developed describing the different aspects of this relatively new entity, increasing our knowledge about this condition and, thus, decreasing the number of undiagnosed patients [1,5,9-11]. However, we did not find any studies describing the clinicopathological features of this bothersome condition in Southern Iran, which made comparisons of its potential similarities and differences in this area in relation to other parts of the world impossible. Therefore, in this study, we aimed to describe the demographic, clinical, dermoscopic, and histopathologic features of the FFA among patients referred to Faghihi Hospital, Shiraz University of Medical Sciences, Shiraz, Southern Iran, from 2013 to 2018. It was anticipated that this study would add to our growing knowledge of this entity and introduce helpful clues that facilitate better and earlier diagnosis.

PARTICIPANTS AND METHODS

In this observational descriptive study, we searched the archives of the Pathology Department of Faghihi Hospital (Shiraz, Iran), with appropriate keywords and found 42 patients whose histopathologic examinations were suggestive of FFA from March 2013 to October 2018. Due to the indistinguishable histopathologic features of FFA, LPP, and fibrosing alopecia in a pattern distribution (FAPD) [6,7,12], we called the 42 patients to be visited at the Dermatology Clinic by our dermatologist regardless of whether they were on treatment or not (since no curative treatment has yet been introduced for this condition as mentioned earlier) [2]. Ultimately, 25 patients attended the clinic and were evaluated for FFA using the updated diagnostic criteria, consisting of two major and four minor features. Major criteria included (i) scarring alopecia of the frontal and/or temporal areas without follicular keratotic papules on the body, and (ii) bilateral diffuse alopecia of the eyebrows. In addition, minor criteria for the diagnosis of FFA consisted of typical trichoscopic findings (perifollicular erythema and hyperkeratosis), histopathologic features in favor of FFA and LPP, the involvement of other FFA areas (occipital, facial, sideburn, or body hair), and, finally, the presence of non-inflammatory facial papules. Patients with 2 major criteria or having 1 major plus 2 minor criteria were diagnosed as FFA [13]. A lack of willingness to participate in the study was considered as the only exclusion criterion. Accordingly, 22 patients were diagnosed with FFA, all of whom were cooperative and provided written informed consent. Demographic information, comorbidities (such as hypothyroidism, atopy, and diabetes mellitus), symptoms (trichodynia; pruritus; burning sensation), physical examination findings (such as facial papules, body hair involvement, and eyelash loss), and the dermoscopic findings of the patients obtained using a dermatoscope (DermLite III (DL3), Dermlite, USA) were collected. Furthermore, the pathology slides were reviewed by a dermatopathologist.

Due to the descriptive nature of the study, the only statistical analysis conducted was the application of Fisher's exact test using SPSS software version 23 to assess independence between the variables (presence/absence of facial papules in pre/postmenopausal women) given that more than 20% of the expected values were less than five. A p-value of less than 0.05 was considered statistically significant.

This study was in accordance with the ethical standards of the Ethics Committee of the School of Medicine, Shiraz University of Medical Sciences

(approval ID: IR.SUMS.MED.REC.1397.231).

RESULTS

This study included 22 patients, all of whom were female. The onset of the disease was prior to menopause in 15 (68.2%) of the women, while the presentation occurred after menopause in the remaining seven (31.8%). The patients had a mean age of 42.3 years at the onset of the disease, ranging from 20 to 63 with a standard deviation (SD) of 12.4. Furthermore, the subjects had a mean age of 46 years (range: 30-64, SD: 11.13) at the time of diagnosis. On average, the disease had been diagnosed 3.7 years (range: 0-21, SD: 4.61) after its onset. The postmenopausal women had an average age of 50 years (range: 47-52, SD: 2.2) at menopause (Table 1).

At the time of the study, all patients had hairline recession at the frontal and temporal regions except one of them who had isolated frontal involvement. One of the patients had patchy frontotemporal involvement with irregular alopecic plaques (Figure 1). Apart from hairline recession, 18 (81.8%) of the patients had eyebrow loss, 6 (27.3%) had eyelash loss, 11 (50%) had body hair loss, and one (4.5%) had a loss of facial hair (Table 2). Moreover, 15 (68.2%) cases featured facial papules, including almost all the premenopausal women (12 out 13) and only a third (n = 3) of the postmenopausal women; the difference between these two groups for this characteristic was significant ($P = 0.007$).

Dermoscopy was performed for all patients, yielding the following results: all (100%) had absence of follicular openings, 13 (59.1%) featured perifollicular scaling, 14 (63.6%) possessed perifollicular erythema, 18 (81.8%) showed honeycombing of the scalp, and 17 (77.3%) had multiple white dots in the involved areas of hairline recession (Table 2).

Scalp biopsies had been taken for all patients, the findings of which are summarized in Table 3. The interfollicular epidermis was intact in 13 (59.1%) of the patients, while non-specific changes such as mild hyperkeratosis and mild acanthosis were present

Table 1. Demographic characteristics of the patients

Characteristic	Value
Mean age (yrs.) at the time of the study (range)	47.7 (33-69)
Mean age (yrs.) at the onset of symptoms (range)	42.3 (20-63)
Mean age (yrs.) at diagnosis (range)	46 (30-64)
Mean age (yrs.) at menopause (range)	50 (47-52)
Menstrual status at the time of study; n (%)	
Premenopausal	13 (59.1)
Postmenopausal	9 (40.9)
Menstrual status at the onset of the symptoms; n (%)	
Premenopausal	15 (68.2)
Postmenopausal	7 (31.8)

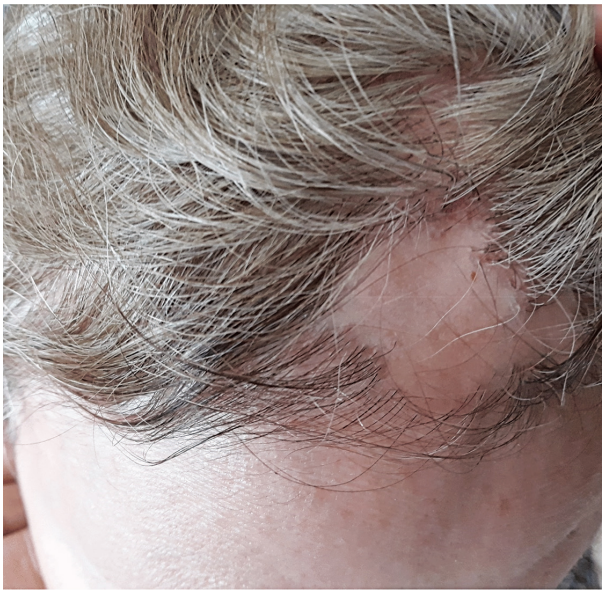

Figure 1. A frontal irregular alopecic plaque in a 56-year-old woman with patchy involvement of the frontotemporal hairline by frontal fibrosing alopecia

Table 2. Clinical and dermoscopic findings of the patients

Finding	Frequency (%)
Clinical findings	
Frontal involvement	22 (100)
Temporal involvement	21 (95.4)
Eyebrow loss	18 (81.8)
Eyelash loss	6 (27.3)
Body hair involvement	11 (50.0)
Facial papules	15 (68.2)
Loss of facial hair	1 (4.5)
Trichodynia	4 (18.2)
Pruritus	16 (72.7)
Burning sensation	3 (13.6)
Urticaria	2 (9.1)
Dermoscopic findings	
Loss of follicular openings	22 (100)
Perifollicular scaling	13 (59.1)
Perifollicular erythema	14 (63.6)
Honeycombing of the scalp	18 (81.8)
Multiple white dots	17 (77.3)

Table 3. Histopathologic findings of the scalp biopsies of the patients

Finding	Frequency (%)
Follicular dropout	21 (95.4)
Perifollicular lymphocytic infiltration involving infundibulum/isthmus	18 (81.8)
Concentric, lamellar perifollicular fibroplasia with artifactual clefting between follicular epithelium and stroma	17 (77.3)
Intact interfollicular epidermis	13 (59.1)
Mild perivascular lymphocytic infiltration in upper dermis	12 (54.5)
Apoptotic keratinocytes in infundibular/isthmic portions of follicular epithelium	11 (50.0)
Mild pigment incontinence in upper dermis	8 (36.4)
Mild hyperkeratosis and mild acanthosis	7 (31.8)
Lichenoid interface dermatitis in infundibular and isthmic portions of follicular epithelium	6 (27.3)
Eccentric thinning of follicular epithelium	4 (18.2)
Perifollicular inflammation in reticular dermis	3 (13.6)
Free hair shafts with foreign body giant cell reaction	2 (9.1)
Focal parakeratosis around ostia of hair follicles	1 (4.5)
Spongiosis and exocytosis of lymphocytes into epidermis	1 (4.5)
Increased catagen/telogen follicles	1 (4.5)

in 7 (31.8%). Lichenoid interface dermatitis was seen at the level of the infundibulum and isthmus of the hair follicles in 6 (27.3%) of the patients and eccentric thinning of the follicular epithelium was observed in 4 (18.2%). In addition, apoptotic keratinocytes were seen at the level of infundibular and isthmic portions of the follicular epithelium in 11 (50%) of the patients. Perifollicular lymphocytic infiltration at the level of the infundibulum and isthmus was recognized in 18 (81.8%) cases and concentric, lamellar perifollicular fibroplasia with artifactual clefting between the follicular epithelium and the stroma was noted for 17 (77.3%) patients. In addition, 12 (54.5%) of the specimens revealed a mild perivascular lymphocytic infiltrate in the upper dermis, while 21 (95.4%) samples featured various degrees of follicular loss (follicular dropout) (Figure 2).

Also, the facial papules of four of the patients had been biopsied, providing the following results: intact interfollicular epidermis (3 of 4); lichenoid interface dermatitis in the follicular epithelium (1 of 4); mild perivascular lymphocytic infiltration (2 of 4); perifollicular lymphocytic infiltration (4 of 4), and follicular dropout (4 of 4).

In addition to FFA, the patients had various comorbidities, with hypothyroidism being the most common (9 of 22; 40.9%), followed by arterial hypertension and atopy (allergic rhinitis and asthma), which each featured in four (18.2%) cases. Next were diabetes mellitus and prediabetes, ischemic heart disease, and dyslipidemia, each reported by three (13.6%) patients (Table 4).

In our series of patients, only one (4.5%) individual mentioned a family history of FFA in their niece.

The patients had received different treatments to control the disease. Hydroxychloroquine sulfate was the most popular treatment (n = 10; 45.4%), followed by finasteride, which was used by nine (40.9%). Topical minoxidil and intralesional corticosteroids (triamcinolone acetonide) were each used by eight (36.4%) of the patients. Less commonly used therapies included prednisolone (n = 5; 22.7%) and topical tacrolimus (n = 2; 9.1%), as well as single (4.5%) reports of mycophenolate, azathioprine, oral tacrolimus, isotretinoin, topical clobetasol, intramuscular (IM) hydrocortisone, and

Table 4. Concurrent comorbidities of the patients

Condition	Frequency (%)
Hypothyroidism	9 (40.1)
Arterial hypertension	4 (18.2)
Atopy (allergic rhinitis and asthma)	4 (18.2)
Dyslipidemia	3 (13.6)
Ischemic heart disease	3 (13.6)
Diabetes mellitus or prediabetes	3 (13.6)
Rheumatoid arthritis	2 (9.1)
Lichen planus	2 (9.1)
Psychiatric disorders	2 (9.1)
Hysterectomy	1 (4.5)
History of herpes zoster	1 (4.5)
Iron deficiency anemia	1 (4.5)
Prophylactic mastectomy	1 (4.5)
Duodenal ulcer	1 (4.5)
Cholecystectomy	1 (4.5)
Migraine	1 (4.5)
Irritable bowel syndrome	1 (4.5)

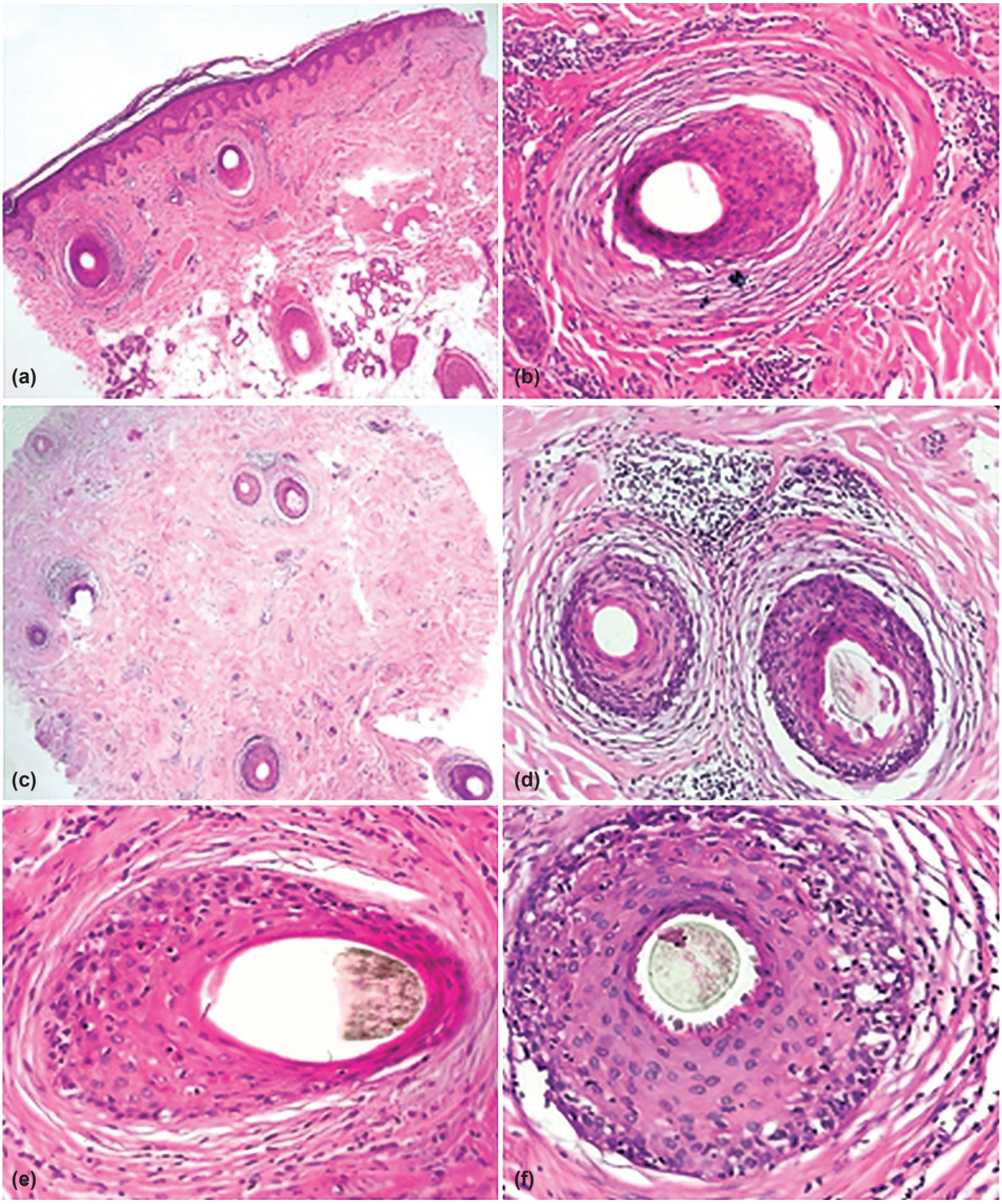

Figure 2. (a, b) Perifollicular concentric, lamellar fibroplasia with artifactual clefting between the follicular epithelium and the stoma, perifollicular and perivascular lymphocytic infiltration, and eccentric thinning of the follicular epithelium in the vertical section (H & E, a: ×100, b: ×400). (c, d) Perifollicular concentric, lamellar fibroplasia with artifactual clefting between the follicular epithelium and the stoma, perifollicular lymphocytic infiltration, interface dermatitis involving the follicular epithelium, and burnout follicles in the horizontal section at the papillary dermal level (H & E, c: ×40, d: ×400). (e) Perifollicular fibroplasia, eccentric thinning of the follicular epithelium, and some apoptotic keratinocytes scattered throughout the follicular epithelium (H & E ×400). (f) Perifollicular lamellar fibroplasia with lymphocytic infiltration, interface dermatitis involving the follicular epithelium, and few scattered apoptotic keratinocytes (H & E ×400).

IM methylprednisolone use. Most patients had undertaken multiple treatments.

DISCUSSION

Frontal fibrosing alopecia is a type of cicatricial alopecia predominantly affecting postmenopausal women, as reported in most studies [2-5,9,14]. In contrast, most of the women (68.2%) in our series developed the disease before menopause. Correspondingly, the mean age at onset of the disease in our patients (42.3 years) was lower than that reported in most previous studies (55-68 years) [2-6,9,14]. However, our findings were similar to those of a study conducted in South Africa, where most of the women were premenopausal with a comparable mean age of disease onset (42 years) [10]. In addition, we did not have any reports of FFA in men in the mentioned time range, which can be due to its low incidence rate in men or the minimal clinical suspicion of FFA as a relatively new entity [15]. In accordance with previous studies, our patients were diagnosed after a period of 3.7 years [4,5]. In our study, there was no report of early menopause (≤ 45 years), which contrasts with some studies describing the coexistence of FFA with premature ovarian failure [3,14].

As seen in this study, the typical findings in patients with FFA were frontal and/or temporal hairline involvement with homogeneous recession [5]. However, an interesting variant has been reported with frontal and/or temporal involvement by irregular alopecic plaques [16]. This rare presentation of patchy involvement of the frontotemporal region was seen in one of our patients.

Frontal fibrosing alopecia affects non-scalp areas as well; it is often accompanied by eyebrow loss [2-4]. Our study also supported this association (81.8% of the patients). In some cases, scalp involvement is preceded by eyebrow alopecia [3], as one of our patients had suffered from this issue for 10 years before the onset of scalp alopecia. Due to the strong association of FFA with eyebrow loss, eyebrow involvement has been introduced as a major criterion for the diagnosis of FFA [13]. Despite eyebrow loss, fewer patients are affected by eyelash loss; this is in accordance with our findings [2,3,5]. Another finding associated with FFA is the presence of facial papules with variable frequencies (0-33.8%) in different studies [3,5,10,14,17]. Nevertheless, in our study, a higher frequency (68.2%) of facial papules was observed, which could be explained by the higher proportion of premenopausal women, since it was reported in a study conducted by Mervis *et al.* on 91 patients with FFA that facial papules were more prevalent in premenopausal women than postmenopausal ones [17]. Supporting their finding, our analysis indicated that premenopausal women presented facial papules significantly more than postmenopausal women. Another interesting finding regarding facial papules is that one of the patients had first sought medical attention due to her facial papules, but the dermatologist incidentally noticed her mild frontal hairline recession. This experience could highlight the importance of detecting facial papules, which can occur ahead of the development of alopecia [18], in the early diagnosis of FFA, particularly in younger women in whom facial papules are more common. This could be achieved through precise examination of the hairline and additional body sites that FFA can affect, particularly by dermoscopy or even biopsy and histopathological studies. Eyelash loss, facial papules, and body hair involvement are related to increased disease severity, comprising helpful findings in determining the prognosis and deciding better choices of treatment for the patients [3]. None of our patients had nail alterations cited in the setting of FFA including ridging, fissuring, superficial fragility, atrophy, and scarring with pterygium formation [19].

We evaluated all our patients by dermoscopy. Dermoscopy can aid in ruling out other differential diagnoses, as well as assessing disease activity [20-22]. According to the fact that perifollicular erythema has been mentioned as a sign of disease activity [22], 14 (63.6%) of our patients were in the active phase of the disease at the time of the study.

Although scalp biopsies had been performed for all our patients and four of them had biopsies from their facial papules, histopathologic confirmation is not necessary for all cases as it is considered a minor criterion for the diagnosis of FFA [13]. The histopathologic findings of FFA are similar to those of LPP and FAPD, making clinical correlations necessary for distinguishing between the diseases [6,7,12]. A brief comparison of the clinical and histopathological features of the three entities is presented in Table 5 [12]. Accordingly, we invited the patients to the clinic to make the final

Table 5. Comparison of clinical and histopathological features of frontal fibrosing alopecia (FFA), lichen planopilaris (LPP), and fibrosing alopecia in a pattern distribution (FAPD)

Condition	Clinical features	Histopathological features
FFA	- Progressive frontotemporal hairline recession with eyebrow loss - Fewer patients with LP lesions elsewhere on the body than LPP	- Interface dermatitis at infundibulum and isthmus - Concentric, lamellar perifollicular fibroplasia with artifactual clefting between follicular epithelium and stroma - Apoptotic cells at infundibular and isthmic epithelium (less seen in LPP)
LPP	- The most common pattern: scattered foci of partial hair loss with perifollicular erythema and scaling - LP lesions on other sites support the diagnosis	- Less apoptotic keratinocytes and denser inflammation than FFA - Interfollicular epidermal changes are most common - Least involvement of vellus hair
FAPD	- Pattern of androgenetic alopecia with diffuse erythema and perifollicular scaling in the zone of thinning	- Increased vellus to terminal hair ratio (not typical of FFA and LPP) - Interfollicular epidermis is not affected - Vellus hair involvement is more common than in LPP

FFA: frontal fibrosing alopecia, LP: lichen planus, LPP: lichen planopilaris, FAPD: fibrosing alopecia in a pattern distribution

diagnosis. In accordance with previous studies, the main histopathologic findings of FFA observed in our specimens included lichenoid lymphocytic infiltrates involving the follicular infundibulum and isthmus, perifollicular fibrosis, apoptosis of the external root sheath keratinocytes, follicular destruction, and a lack of lichenoid inflammation within the interfollicular epidermis [6,8,14,23,24]. However, a substantial proportion of the biopsies (54.5%) showed mild superficial perivascular lymphocytic infiltration, which is reportedly more common in LPP than FFA [6].

Frontal fibrosing alopecia has been associated with various autoimmune disorders, the most prominent of which are thyroid disorders involving up to 45% of the patients [2-5,9,14,23,25,26]. Correspondingly, a relatively high proportion (40.9%) of our patients had concurrent hypothyroidism. It has been recommended that all patients with FFA be assessed for thyroid disorders [3]. Other autoimmune conditions seen in our study were RA, atopy (allergic rhinitis and asthma), and LP, supporting the role of immune mechanisms in the pathogenesis of FFA [27].

It is noteworthy that familial cases of FFA have been reported in 17.7% of patients [27]. It is assumed that FFA is inherited in an autosomal dominant pattern with incomplete penetration [28]. In this study, a family history of FFA was present in one (4.5%) of the patients. These observations suggest a role of genetic factors in the pathogenesis of the disease [27,28].

In the current study, the patients had experienced various treatments, the efficacies of which were unclear owing to the lack of medical records regarding their disease progression. However, in the literature, 5-alpha-reductase inhibitors, antimalarials, and intralesional corticosteroids have shown the greatest efficacies in stopping the disease [29,30].

Finally, this study provides some recommendations for better recognition, diagnosis, and management of FFA:

1. This condition is not rare in premenopausal women in comparison with postmenopausal women.
2. In addition to its typical presentation, dermatologists should be familiar with atypical presentations of FFA, such as patchy involvement of the frontotemporal hairline by irregular alopecic plaques.
3. Eyebrow loss and facial papules, which can precede scalp alopecia by years, are good clues for early diagnosis.
4. Facial papules are more common to premenopausal women with FFA than postmenopausal ones.
5. Due to the high coexistence of FFA with thyroid disorders, it is recommended that all patients be evaluated for the latter.

Acknowledgement

The present article was extracted from the M.D. thesis of Mohammad Sasannia, which was financially supported by the Shiraz University of Medical Sciences, Shiraz, Iran (Grant No.: 1396-01-01-16571).

Conflict of Interest: None declared.

REFERENCES

1. Kossard S. Postmenopausal frontal fibrosing alopecia. Scarring alopecia in a pattern distribution. Arch Dermatol. 1994;130:770-4.
2. Zhang M, Zhang L, Rosman IS, et al. Frontal fibrosing alopecia demographics: a survey of 29 patients. Cutis. 2019;103:e16-e22.
3. Vañó-galván S, Molina-ruiz AM, Serrano-falcón C, et al. Frontal fibrosing alopecia: a multicenter review of 355 patients. J Am Acad Dermatol. 2014;70:670-8.
4. Kanti V, Constantinou A, Reygagne P, et al. Frontal fibrosing alopecia: demographic and clinical characteristics of 490 cases. J Eur Acad Dermatol Venereol. 2019;33:1976-83.
5. Imhof RL, Chaudhry HM, Larkin SC, et al. Frontal fibrosing alopecia in women: the Mayo Clinic experience with 148 patients, 1992-2016. Mayo Clin Proc. 2018;93:1581-88.
6. Poblet E, Jiménez F, Pascual A, et al. Frontal fibrosing alopecia versus lichen planopilaris: a clinicopathological study. Int J Dermatol. 2006;45:375-80.
7. Gálvez-canseco A, Sperling L. Lichen planopilaris and frontal fibrosing alopecia cannot be differentiated by histopathology. J Cutan Pathol. 2018;45:313-7.
8. Cerqueira ER, Valente N, Sotto MN, et al. Comparative analysis of immunopathological features of lichen planopilaris and female patients with frontal fibrosing alopecia. Int J Trichology. 2016;8:197-202.
9. Heppt MV, Letulé V, Laniauskaite I, et al. Frontal fibrosing alopecia: a retrospective analysis of 72 patients from a German academic center. Facial Plast Surg. 2018;34:88-94.
10. Dlova NC, Jordaan HF, Skenjane A, et al. Frontal fibrosing alopecia: a clinical review of 20 black patients from South Africa. Br J Dermatol. 2013;169:939-41.
11. Kanti V, Constantinou A, Reygagne P, et al. Frontal fibrosing alopecia: demographic and clinical characteristics of 490 cases. J Eur Acad Dermatol Venereol. 2019;33:1976-83.
12. Sperling LC, Cowper SE, Knopp EA (Eds). An atlas of hair pathology with clinical correlations. London: Informa Healthcare; 2012.
13. Vañó-galván S, Saceda-corralo D, Moreno-arrones ÓM, et al. Updated diagnostic criteria for frontal fibrosing alopecia. J Am Acad Dermatol. 2018;78:e21-e2.
14. Starace M, Brandi N, Alessandrini A, et al. Frontal fibrosing alopecia: a case series of 65 patients seen in a single Italian centre. J Eur Acad Dermatol Venereol. 2019;33:433-8.
15. Tolkachjov SN, Chaudhry HM, Camilleri MJ, et al. Frontal fibrosing alopecia among men: a clinicopathologic study of 7 cases. J Am Acad Dermatol. 2017;77:683-90.e2.
16. Contin LA, De almeida ledá YL, Caldeira nassif K, et al. Patchy frontal fibrosing alopecia: description of an incomplete clinical presentation. Skin Appendage Disord. 2017;3:190-2.
17. Mervis JS, Borda LJ, Miteva M. Facial and extrafacial lesions in an ethnically diverse series of 91 patients with frontal fibrosing alopecia followed at a single center. Dermatol. 2019;235:112-9.
18. Pirmez R, Barreto T, Duque-Estrada B, et al. Facial papules in frontal fibrosing alopecia: beyond vellus hair follicle involvement. Skin Appendage Disord. 2018;4:145-9.
19. Macpherson M, Hohendorf-ansari P, Trüeb RM. Nail involvement in frontal fibrosing alopecia. Int J Trichology. 2015;7:64-6.
20. Inui S, Nakajima T, Shono F, et al. Dermoscopic findings in frontal fibrosing alopecia: report of four cases. Int J Dermatol. 2008;47:796-9.
21. Rubegni P, Mandato F, Fimiani M. Frontal fibrosing alopecia: role of dermoscopy in differential diagnosis. Case Rep Dermatol. 2010;2:40-5.
22. Toledo-Pastrana T, Hernández MJ, Camacho Martínez FM. Perifollicular erythema as a trichoscopy sign of progression in frontal fibrosing alopecia. Int J Trichology. 2013;5:151-3.
23. Banka N, Mubki T, Bunagan MJ, et al. Frontal fibrosing alopecia: a retrospective clinical review of 62 patients with treatment outcome and long-term follow-up. Int J Dermatol. 2014;53:1324-30.
24. Zaouak A, Ghorbel HH, Badri T, et al. Frontotemporal hairline recession in a postmenopausal woman. Dermatol Pract Concept. 2015;5:129-31.
25. Kusano LDC, Brenner FAM. Frontal fibrosing alopecia: follow-up of a Brazilian group. An Bras Dermatol. 2019;94:365-6.
26. Moreno-Arrones OM, Saceda-Corralo D, Rodrigues-Barata AR, et al. Risk factors associated with frontal fibrosing alopecia: a multicentre case-control study. Clin Exp Dermatol. 2019;44:404-10.
27. Photiou L, Nixon RL, Tam M, et al. An update of the pathogenesis of frontal fibrosing alopecia: what does the current evidence tell us? Australas J Dermatol. 2019;60:99-104.
28. Tziotzios C, Stefanato CM, Fenton DA, et al. Frontal fibrosing alopecia: reflections and hypotheses on aetiology and pathogenesis. Exp Dermatol. 2016;25:847-52.
29. To D, Beecker J. Frontal fibrosing alopecia: update and review of challenges and successes. J Cutan Med Surg. 2018;22:182-9.
30. Rácz E, Gho C, Moorman PW, et al. Treatment of frontal fibrosing alopecia and lichen planopilaris: a systematic review. J Eur Acad Dermatol Venereol. 2013;27:1461-70.