The biological debridement of bedsore with the larvae of *Lucilia sericata*: a case report

Kamran Akbarzadeh, PhD [1]
Abedin Saghafipour, PhD [2*]

1. Department of Medical Entomology and Vector Control, School of Public Health, Tehran University of Medical Sciences, Tehran, Iran
2. Department of Public Health, Faculty of Health, Qom University of Medical Sciences, Qom, Iran

*Corresponding author:
Abedin Saghafipour, PhD
Department of Public Health, Faculty Health, Qom University of Medical Sciences, Qom, Iran
Email: abed.saghafi@yahoo.com

Received: 2 February 2020
Accepted: 8 June 2020

Bedsores are caused by decreased tissue perfusion due to prolonged pressure on the skin and represent one of the problems of immobilized patients, including hospitalized ones. This study reports the successful treatment of a patient with bedsore wounds using the larvae of the fly *Lucilia sericata.* The study focused on a 64-year-old man residing in Qom (a city in central Iran), who was hospitalized for 45 days at Qom Shahid Beheshti Hospital in November 2019 because of cardiovascular disease and chronic obstructive pulmonary disease (COPD). He had a pressure ulcer of about 9.5 cm in diameter on the skin overlying the sacrum. After showing resistance to honey dressing and conventional antibiotic treatments, maggot therapy was recommended. This procedure was done by releasing the larvae of *L. sericata* 12 times every three days. The removal of necrotic tissues and the appearance of the granulated tissues were recorded using a ruler as an indicator of healing. After 12 sessions of larval treatment, the wound surface considerably reduced and was finally healed. Thus, it can be argued that maggot debridement therapy (MDT) is an effective treatment for bedsores and can be recommended to physicians as an adjuvant treatment for complex and resistant ulcers.

Keywords: bedsore, debridement, larva

Iran J Dermatol 2021; 24: 139-142

DOI: 10.22034/ijd.2021.132462

INTRODUCTION

Bedsores (pressure ulcers) are caused by decreased tissue perfusion due to prolonged pressure on the skin and represent one of the main problems in immobilized patients, particularly hospitalized ones [1]. This health issue has significant mental, physical, financial, and social consequences on the patients, involved families, healthcare workers, and health systems, with patients inevitably dealing with health problems such as pain, limb deformity, disability, and dependency on others [2]. In some cases, bedsores have also led to osteomyelitis and death [3]. Billions of dollars are spent annually in healthcare centers worldwide for the prevention and treatment of bedsores, especially for long-stay patients in hospitals [4]. Bedsores can affect any parts of the body, especially those parts where the bone is closer to the skin, such as the tailbone, hips, heels, and ankles. Bedsores, which start from the skin and, if left untreated, spread to the underlying tissues, range from 1 to 4 degrees according to their severity [5]. They are considered as one of the most common problems observed in hospitalized patients worldwide. The most commonly affected patients are those with spinal cord injuries, the elderly, and long-term hospitalized patients, particularly those undergoing surgery and those admitted to intensive care units (ICUs) [6]. About 65,000 cases of death have been reported among 1,000,000 cases of bedsores' complications, reflecting a major health issue around the globe [7]. The prevalence of bedsores in Iran has been estimated to include about 19% of all hospitalized patients. The most common bedsore

site is the sacrum [8]. Nowadays, different therapeutic options are used to treat patients with bed wounds. Honey dressing, vacuum-assisted closure (VAC), the use of electrical stimulation (ES), low-level laser therapy, hyperbaric oxygen treatment, surgical debridement, and larval therapy with maggots are routine treatments for pressure ulcers [1,2].

The beneficial effects of maggot therapy on wound healing and decreasing the need for amputation have been known for centuries. Numerous studies indicate that in ancient times, fly larvae, also called surgical maggots, were used to treat wounds. Debridement is one of the first steps of the wound healing process and is crucial for wound bed preparation [1]. It can be done through various methods [2]. Sharp and surgical debridement and some other conventional methods of debridement such as hydrotherapy and the use of a wet-to-dry gauze can be categorized as non-selective debridement strategies, which can damage healthy tissues by removing viable tissues more or less. In contrast, selective debridement methods can be used without damage to viable tissues [1,2]. Maggot debridement therapy (MDT) is among the selective methods that consume necrotic tissues and leave behind a healthy granulated base [9]. The U.S. FDA has also approved maggot therapy for the biological debridement of a wide variety of wounds [10]. Selective biological debridement along with other main characters of maggots including antibacterial effects as well as promoting wound growth brought great advantages for MDT in wound healing [11].

MDT is currently recognized as an effective, safe, and cost-effective treatment [9]. In this therapy, live and disinfected maggots of the fly *Lucilia sericata* (Diptera: Calliphoridae) are used for wound debridement and disinfection, ultimately accelerating wound healing. In addition, larval therapy has many benefits for patients, such as reducing the time of treatment and hospitalization [11]. Numerous studies have demonstrated the efficacy of maggot therapy in the treatment of chronic ulcers, including bedsores [9-12]. As reported in a study in Turkey, the rate of treatment of pressure ulcers with the larvae of *L. sericata* was nearly 80% [12]. There are very good experiences in maggot therapy in Iran, especially for the removal of bacterial infections and the treatment of diabetic foot ulcers [13]. In light of the above, this study reports the successful treatment of bedsore in a patient by MDT with the larvae of *L. sericata*.

CASE PRESENTATION

This study reports the treatment process of a 64-year-old man from Qom (a city in central Iran) who was hospitalized for 45 days at Shahid Beheshti Hospital in November 2019 due to cardiovascular disease and chronic obstructive pulmonary disease (COPD). He had a pressure ulcer of about 9.5 cm in diameter on the skin overlying the sacrum (sacral area) (Figure 1).

Figure 1. A necrotic pressure ulcer of about 9.5 cm in diameter on the skin overlying the sacrum of the studied patient before MDT (Shahid Beheshti Hospital, Qom, Iran)

In tests performed on admission, the following results were observed: white blood cell (WBC) = 5600/cu mm, erythrocyte sedimentation rate (ESR) = 71 mm/1 hour, and C-reactive protein (CRP) = positive. The patient was initially treated with antibiotics (cefazolin 1 g injection every 6 hours + gentamicin 800 mg every 8 hours + metronidazole 250 mg every 8 hours) and honey dressing for 28 days as conventional treatment for such cases. There was no significant progress in the healing of the wound, which might be because of bacterial resistance as well as the ineffectiveness of conventional treatments. After the frustration arising from conventional therapeutic measures, MDT with the larvae of the fly *L. sericata* was recommended to treat his bedsore. To do so, after dressing the area around the wound site, the larvae were freely released on the necrotic and static ulcer (Figure 2).

After 72 hours, the larvae were removed from the ulcer, and MDT in this manner was repeated 12 times in 36 days. After 12 sessions of larval treatment, the formation of healthy granulation tissue was completed; the wound surface area reduced considerably and the healing process was then completed (Figure 3).

DISCUSSION

The tendency to use biological treatment methods, such as maggot therapy, to treat wounds has increased over the past decades because of resistance to bacterial and chemical agents [14]. Maggot debridement therapy (MDT) is a well-known method to treat wounds and chronic infectious ulcers. Larvae can accelerate wound healing by debridement, disinfection, and stimulation of new tissue growth in wounds [11]. MDT is used to treat diabetic ulcers, bedsores, burns, and certain types of malignant tumors, domes, and boils for which other treatments do not work or are inappropriate. This treatment is a very simple and relatively inexpensive method and, unlike antibiotics, does not cause any side effects [9-12].

The frequency of employing maggots in wounds varies in terms of the size, depth, location, and other conditions of the wounds. In this study, the use of larvae was repeated 12 times. Polat *et al.* evaluated the effect of MDT on patients with decubitus ulcers and observed that about 80% of patients were completely healed after four to eight treatment sessions [12]. Also, Stegeman and Steenvoorde found that MDT prevented more than 50% of amputations [15]. Furthermore, Gottrup

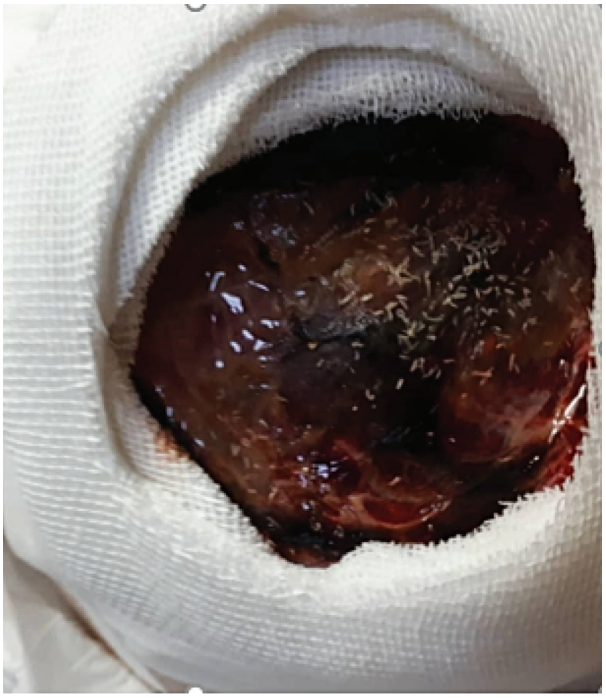

Figure 2. Applying fly maggots to the wound of the studied patient (Shahid Beheshti Hospital, Qom, Iran)

Figure 3. Successful reduction of the wound surface area ahead of its complete closure (Shahid Beheshti Hospital, Qom, Iran)

and Jorgensen reported that using MDT is a very effective technique to treat chronic wounds. This technique is comparable to surgical and non-surgical methods and is believed to be highly efficient and reliable [16].

One of the main causes of a bedsore is immobility [17]. Immobility may be due to long-term hospitalization. A bedsore was not the first problem of the patient of this study. He was hospitalized because of cardiovascular disease, with bedsore developing as a complication. With this issue, an extra treatment line was added to the basket of drugs and the costs of the hospital. It seems that MDT was the best option for this patient because of the resistance of his wound to other therapeutic measures. In the present study, based on the history of the patient, he had been treated with honey dressing and antibiotics before the onset of MDT. It seems that if the cost of the hospital stay is added to the costs of antibiotics and honey dressing, MDT is much more cost-effective. Physicians should gradually trust this treatment technique and consider and incorporate it into their routine treatment plans for chronic ulcers.

CONCLUSION

The results of this study confirmed the effectiveness of MDT in a hard-to-heal pressure ulcer. Consequently, MDT can be recommended for such wounds that seem untreatable by other therapeutic measures. The treatment of this case proved that MDT is completely effective in eligible wounds and there is no need to examine other conventional therapeutic measures. It seems that in this case, the first four weeks attempting to use conventional therapy wasted 28 days of the treatment time before switching to MDT. Therefore, MDT can be recommended for all eligible cases that have sufficient inclusion criteria and can reduce the time and costs of wound healing.

Conflict of Interest: None declared.

REFERENCES

1. Boyko TV, Longaker MT, Yang GP. Review of the current management of pressure ulcers. Adv Wound Care. 2018; 7(2):57-67.
2. Spilsbury K, Nelson A, Cullum N, et al. Pressure ulcers and their treatment and effects on quality of life: hospital inpatient perspectives. J Adv Nurs. 2007; 57(5):494-504.
3. Bodavula P, Liang SY, Wu J, et al. Pressure ulcer-related pelvic osteomyelitis: a neglected disease? Open Forum Infect Dis. 2015;2(3):ofv112.
4. Sen CK, Gordillo GM, Roy S, et al. Human skin wounds: a major and snowballing threat to public health and the economy. Wound Repair Regen. 2009;17(6):763-71.
5. Bhattacharya S, Mishra RK. Pressure ulcers: Current understanding and newer modalities of treatment. Indian J Plast Surg. 2015;48(1):4-16.
6. Agrawal K, Chauhan N. Pressure ulcers: back to the basics. Indian J Plast Surg. 2012; 45(2):244-54.
7. Soban LM, Hempel S, Munjas BA, et al. Preventing pressure ulcers in hospitals: a systematic review of nurse-focused quality improvement interventions. Jt Comm J Qual Patient Saf. 2011;37(6):245.
8. Karimian M, Sarokhani D, Sarokhani M, et al. Prevalence of bedsore in iran: a systematic review and meta-analysis. J Mazandaran Univ Med Sci. 2016;26 (136):202-210.
9. Sherman RA. Maggot therapy takes us back to the future of wound care: new and improved maggot therapy for the 21st century. J Diabetes Sci Technol. 2009;3(2):336-44.
10. Wayman J, Nirojogi V, Walker A, et al. The cost effectiveness of larval therapy in venous ulcers. J Tissue Viability. 2000;10:914.
11. Sherman RA. Mechanisms of maggot-induced wound healing: what do we know, and where do we go from here? Evid Based Complement Alternat Med. 2014;2014:592419.
12. Polat E, Kutlubay Z, Sirekbasan S, et al. Treatment of pressure ulcers with larvae of *Lucilia sericata*. Turk J Phys Med Rehabil. 2017;63(4):307–312.
13. Malekian A, Esmaeeli Djavid G, Akbarzadeh K, et al. Efficacy of maggot therapy on staphylococcus aureus and pseudomonas aeruginosa in diabetic foot ulcers: a randomized controlled trial. J Wound Ostomy Continence Nurs. 2019;46(1):25-29.
14. Adiele LC, Adiele RC, Enye JC. Wound healing effect of methanolic leaf extract of Napoleona vogelii family: lecythidaceae in rats. Asian Pac J Trop Med. 2014;7(8):620-4.
15. Stegeman SA, Steenvoorde P. Maggot debridement therapy. Proc Neth Entomol Soc Meet. 2011;22:61-66.
16. Gottrup F, Jorgensen. B maggot debridement: an alternative method for debridement. ePlasty. 2011;11:290-302.
17. Bhattacharya S, Mishra RK. Pressure ulcers: current understanding and newer modalities of treatment. Indian J Plast Surg. 2015;48(1):4–16.