External beam irradiation in keloid management: two case reports and review of literature

Vito Filbert Jayalie, MD
Henry Kodrat, MD*

Department of Radiation Oncology, Faculty of Medicine Universitas Indonesia-Dr. Cipto Mangunkusumo Hospital, Jakarta, Indonesia

**Corresponding author:*
Henry Kodrat, MD
Department of Radiation Oncology, Faculty of Medicine Universitas Indonesia-Dr. Cipto Mangunkusumo Hospital, Jakarta, Indonesia
Email: henrykodrat@gmail.com

Received: 22 May 2021
Accepted: 20 October 2021

Background: Keloid is a benign fibroproliferative skin disorder. Surgery has a high recurrence rate as the treatment of choice to instantly eliminate the lesion, so adjuvant radiotherapy may be useful. This article aims to discuss case reports and present a systematic review of external beam radiation therapy (EBRT) as an adjuvant in postoperative keloid management.

Methods: Case reports were obtained from patients in our institution. Informed consent was obtained for each patient. Articles found on literature search from Pubmed and Scopus were processed following Preferred Reporting Items for Systematic Reviews and Meta-Analyses and Centre of Evidence-Based Medicine University of Oxford guidelines. The risk of bias was rated using the Cochrane risk of bias tool.

Results: We reported the cases of two Asian women aged 18 and 23 years old with a history of injury to the earlobe before keloid formation. Postoperative radiotherapy was administered within 7 hours, with an 8-months follow-up showing no recurrence and grade 1 toxicity. Five articles appraised in this review suggested a lower recurrence rate for postoperative radiotherapy compared to steroid injection and conventional surgery (11.5 vs. 26.67 vs. 33%). Brachytherapy had a lower recurrence rate than external radiation but was limited by the need for a special applicator. The side effects of all treatment modalities in this study were well-tolerated.

Conclusion: Postoperative EBRT is a promising modality to minimize the risk of recurrence with low toxicity for keloid lesions. More randomized control trials are needed to better understand the role of EBRT in keloid management.

Keywords: keloid, external beam irradiation, postoperative

Iran J Dermatol 2022; 25: 142-153

DOI: 10.22034/ijd.2021.284680.1372

INTRODUCTION

Keloid, meaning crab claw in Greek, is a skin lesion characterized by fibroblast proliferation, extracellular matrix formation, and excess collagen deposition on the skin [1,2]. Many epidemiological studies highlighted female gender, young age, and people of color as important risk factors. An American study suggested that around 427,500 annual medical visits were related to keloids in women with a median age of 36.6 years old, accounting for up to 62% of the visits, mainly African American and Asian descendants [3]. A Taiwan-based study conducted between 2000–2005 found that the incidence rate of keloids reached 0.15% among the Taiwanese population, with

women and the age group of 20–29 being the most susceptible [4].

Various modalities have been proposed for managing keloids in terms of prevention as well as therapy. Preventive measures include avoidance of scar formation, minimal tension wound sutures, a mechanical stabilizer such as a bandage, or flavonoids [5,6]. Surgery, laser therapy, radiation, and medical interventions such as intralesional injections are some modalities used in treating keloids. However, the search for the golden standard treatment is still ongoing as the aforementioned therapies still possess controversies regarding their risks and benefits. A triamcinolone acetonide (TAC) injection exerts its effect via anti-inflammation and anti-allergy mechanisms but may also cause pigmentation and tissue atrophy. On the other hand, laser therapy is regarded as effective but may also affect surrounding healthy tissue. Meanwhile, surgery, one of the most common interventions, has a high recurrence rate of 65–99% [1,7].

Recent updates suggest that postoperative adjuvant therapy may lower the risk of keloid recurrence. Radiotherapy, utilizing endothelial vascularization and lowering fibroblast proliferation, is proposed to help early wound healing and thus promote better prognosis [8]. Howbeit, the lack of studies evaluating the use of postoperative radiotherapy for keloids, especially in Indonesia, limits the potential it may possess. This article discusses two case reports on patients receiving external radiation as postoperative adjuvant therapy while evaluating this mortality using a systematic review.

CASE REPORTS

Case 1

A 23-year-old female complained of a growing lump on her left ear after giving birth to her second child. The growth, triggered by ear-piercing eight years ago, was noticeable, especially during her pregnancies and when she had operations 2 and 5 years ago. A family history of a similar case was denied. On physical examination, no abnormalities were found except for a mass on the upper part of her left ear. The solid, raised, soft palpable mass measuring 4.3 × 2.2 × 2 cm (anteroposterior, laterolateral, craniocaudal) was painless, skin-colored, well-demarcated, and protruding outward of the auricle.

The patient was diagnosed with a left auricle keloid and planned to undergo an operation in addition to electron EBRT within seven hours after surgery. An electron EBRT encompassing a field of 6 × 6 cm inclusive of an additional 1 cm margin from the operative scar was applied with 6 MeV, 1.5 cm depth, 100 cm source-skin-distance (SSD), given at a dose of 3 × 6 Gy. A customized designed bolus was made to cover her left ear with an added 0.5 cm soft bolus from the outermost margin of her operative scar. The full details on patient preparation are shown in Figure 1.

After operation and radiotherapy, the patient complained of pain around the scar without signs of radiation toxicity. No additional therapy was administered. At evaluation two weeks following therapy, the patient felt itchy around the scar with signs of a grade 1 radiation toxicity. Similar complaints of pain and itchiness were reported at the subsequent one-month evaluation. Grade 1 radiation toxicity was observed during the 1st, 8th, and 12th months of evaluation (Figure 2). Keloid recurrence was not observed for the duration of follow-up.

Case 2

An 18-year-old female complained of itchy, skin-colored lumps on both her left and right auricles appreciable 1.5 years prior to admission. The growth was triggered by a burn injury to both her ears, right face, left cheek, and right neck one year and eight months ago during a house fire. A family history of a similar case was denied. General examination showed normal findings. On her left auricle, a soft, solid, well-demarcated, painless mass of size 1 × 4 × 7.5 cm (anteroposterior, laterolateral, craniocaudal) was covering the whole auricle. Meanwhile, a 1.5 × 1 × 5 cm solid mass of similar characteristics was found protruding outward of the middle part of her right auricle. Additionally, a solid, skin-colored mass was found on her left cheek along with full-thickness and split-thickness skin graft scars on her face, neck, back, and right chest. Postoperative contractures were found on both of her hands.

The patient was diagnosed with left and right ear, face, and neck keloids in addition to full-



Figure 1. Patient preparation for both cases 1 and 2. Bolus preparation using paraffin wax (A, B). Bolus attachment to the patient (C, D). Patient positioning and set-up position (E, F).

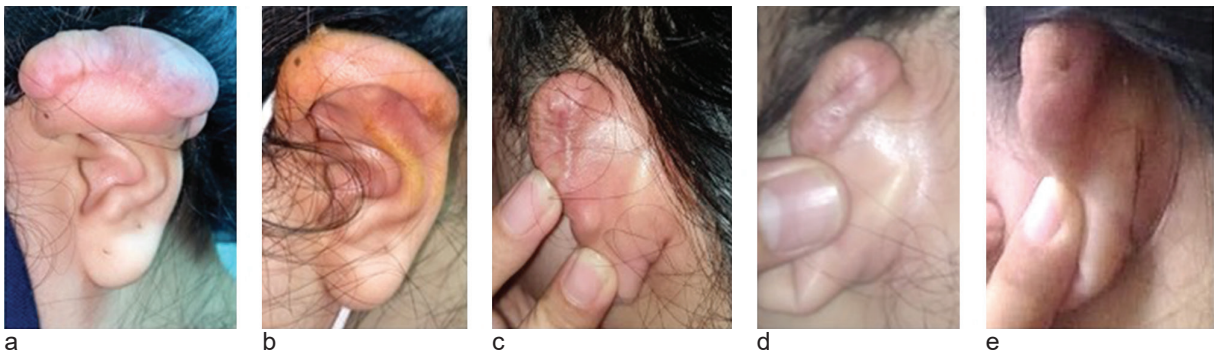

Figure 2. Patient follow-up. (A) Before surgery. (B) 2 weeks after surgery and radiotherapy. (C) 1 month, (D) 8 months, (E) 12 months after radiotherapy.

thickness skin graft scars on her neck and face as well as a split-thickness skin graft scar on her face and contractures on both hands following the release contracture procedure. The therapy regimen involved surgery followed by electron EBRT within seven hours post-surgery on her left ear before proceeding with other body parts. Anatomical pathology assessment revealed

hypertrophic scars and multiple keloids. An electron EBRT encompassing field of 10 × 6 cm inclusive of an additional 1 cm margin from the operative scar was applied with energy set at 4 MeV, 1 cm depth, 100 cm SSD, given at a dose of 3 × 6 Gy. A customized designed bolus was made to cover her left ear with an added 0.5 cm soft bolus from the outermost margin of her operative scar (Figure 1).

The patient complained of pain around the scar following the procedures, for which the physician recommended silicone sheet covering and micropore tapping. The patient complained of itchiness in the second week of evaluation, with grade 1 radiation toxicity. The patient was prescribed intralesional steroid injections at a three-week interval but only received the injection once at one month after the procedures due to the COVID-19 pandemic. Grade 1 radiation toxicity was observed during the 1st, 8th, and 12th months of evaluation (Figure 3). Keloid recurrence was not observed for the duration of follow-up.

METHODS

Case reports were obtained from patients in our institution. Informed consent was obtained for each patient.

Literature search obtained from online databases (Pubmed and Scopus) was conducted on 30th September 2020. Keywords used along with inclusion and exclusion criteria are listed in Supplementary Table 1. The literature search flow diagram is presented in Supplementary Figure 1.

The articles found were presented based on Preferred Reporting Items for Systematic Reviews and Meta-Analysis (PRISMA) and critically appraised following The Centre for Evidence-Based Medicine (CEBM) guidelines by the University of Oxford, assessing their validity, importance, and applicability [9,10]. The Cochrane risk of bias tool was implemented to evaluate the risk of bias in each study [11]. The study design, subject characteristics, intervention modality, and outcomes from the studies were also evaluated.

RESULTS

Literature search

Among the 397 articles found, five were included in the final critical appraisal considering the eligibility criteria (supplementary table 2). Two of the systematic reviews found were excluded

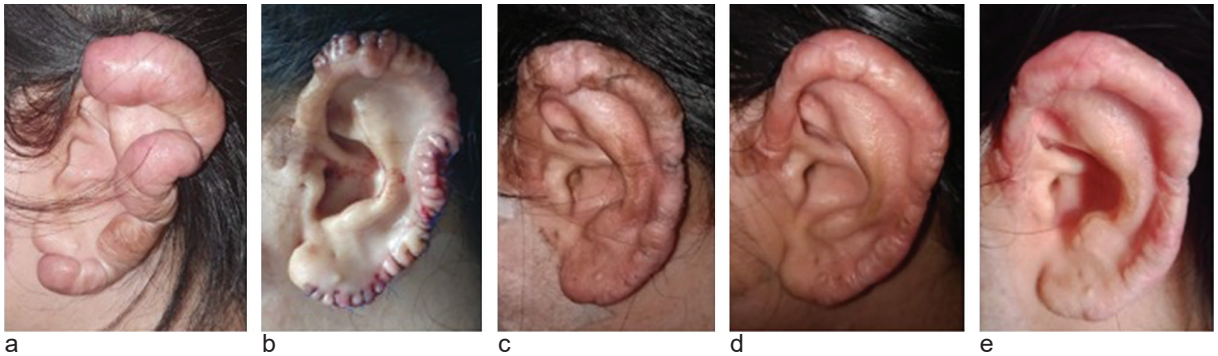

Figure 3. Patient follow-up. (A) Before surgery. (B) After surgery. (C) 1 month, (D) 8 months, (E) 12 months after radiotherapy.

Supplementary Table 1. Literature search keywords and inclusion and exclusion criteria

Keywords	(“Keloid”) AND (“Radiation Therapy” OR “Radiotherapy” OR “Radiation” OR “RT” OR “RTx” OR “XRT”) AND (“Surgery” OR “Postoperative”)
Inclusion criteria	- Observational study or clinical trial - All age groups - Evaluate postoperative keloid treatment and therapy outcomes - Comparing external radiation with other modalities - Articles written in English or Indonesian
Exclusion criteria	- Absence of group receiving external radiation exclusively - Unavailability of full-text article

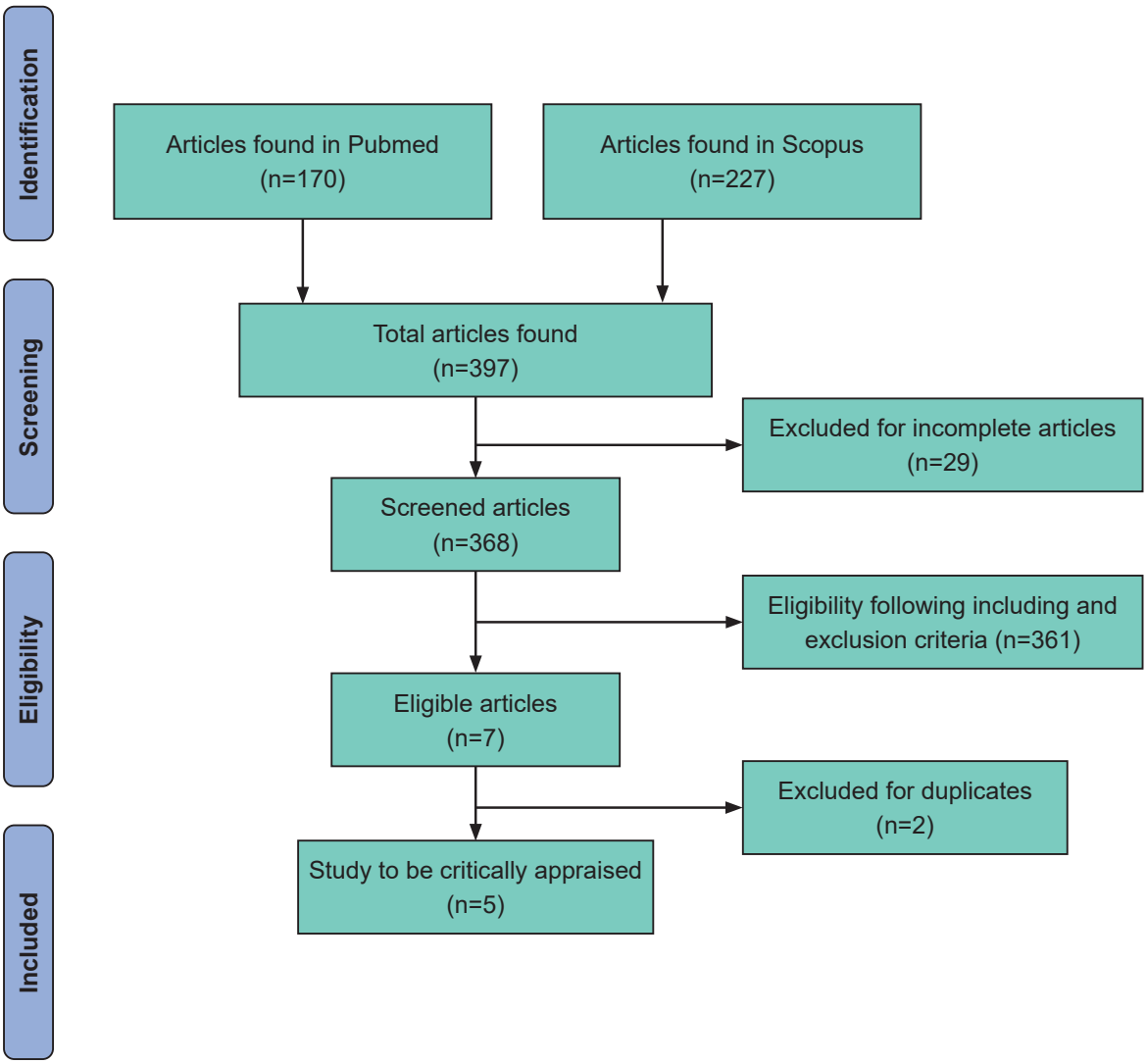

Supplementary Figure 1. Literature search flow diagram.

as they did not compare radiotherapy with other modalities. Another study was excluded due to evaluating combination therapies without the specific analysis of postoperative radiation.

Risk of bias and level of evidence

Assessed risk of bias components including selection, performance, detection, attrition,

Supplementary Table 2. Search strategy from Scopus and Pubmed

Online databases	Keywords	Number of articles found	Number of articles appraised
Scopus	(TITLE-ABS-KEY (keloid) AND TITLE-ABS-KEY (radiation AND therapy OR radiotherapy OR radiation OR rt OR rtx OR xrt) AND TITLE-ABS-KEY (surgery OR postoperative))	227	3
Pubmed	((Surgery[Title/Abstract]) OR (Postoperative[Title/Abstract])) AND (((Radiation Therapy[Title/Abstract]) OR (Radiotherapy[Title/Abstract]) OR (Radiation[Title/Abstract]) OR (RT[Title/Abstract]) OR (RTx[Title/Abstract]) OR (XRT[Title/Abstract])) AND (Keloid[Title/Abstract]))	170	4

* 2 articles were duplicates from the online databases, the final number of articles to be appraised is 5.

reporting, and other bias are provided in Supplementary Table 3. Generally, the risk of bias from the studies was moderately high as randomization and allocation concealment were only employed by Khalid *et al.* [12] and Sclafani *et al.* [13]. Low risk of performance bias and high risk of detection bias was observed in all studies. As for the attrition and reporting bias, 1 study of each category was considered high risk, with 1-2 studies having unclear risks and low risk for the others. Additionally, most of the articles found being observational studies also possess a certain degree of bias. The level of evidence of two and three of the final five articles was level 2 and 3, respectively [12–16]. The studies are summarized in Table 1.

Study characteristics

The five articles were found to have a similar study aim: to assess the recurrence and complications of postoperative radiotherapy compared with other modalities. They were published from 1996 to 2020. Most of the studies adopted a retrospective study design, whereas two were randomized clinical trials. Overall, from a total of 755 keloid patients/lesions, 376 received postoperative external irradiation, which was compared to a variety of other modalities such as conventional surgery, drugs, a combination of excision with an intralesional corticosteroid, and brachytherapy following surgery [12–16].

The population characteristics were comparable. The age ranged from 15 to 69 years, with a majority being 20 years or older. The risk of recurrence, regardless of single or multiple lesions, was higher in women and in dark skin-colored races. The primary cause of ear keloids was trauma due to ear piercing [12–16].

Efficacy of external radiation versus other modalities

The median follow-up duration of the studies varied from 5.5 to 120 months. The recurrence rate in the groups receiving post-surgery external radiation was 12.5–56.67%, with a median time until recurrence of 6–42 months. Meanwhile, the recurrence rate of groups having only conventional surgery, post-surgery intralesional steroid injections, and post-surgery brachytherapy were 33–54% (median time 9-10 months), 26.67–33% (median time 7-18 months), and 11.5–23% (median time 12 months), respectively [12–16].

Safety Evaluation of Keloid Management

All modalities observed in the studies were generally well-tolerated by the patients. Postoperative external radiation groups complained mainly of erythema or hyperpigmentation (2–10%). On the other hand, epidermolysis and wound dehiscence occurred in 6.67% of groups receiving post-surgery steroid injections. As for the post-surgery brachytherapy group, infection, open wound, erythema, or hyperpigmentation were observed in 16% of the patients [12–16]. Long-term follow-up by Duan *et al.* revealed that two subjects were diagnosed with esophageal cancer; nevertheless, the location of occurrence being distant from the site of intervention doubted the relationship of causality [16].

DISCUSSION

Abnormal wound healing is the key mechanism underlying keloid formation. A keloid is a solid, erythematous, smooth, and shiny protruding mass that, unlike hypertrophic scars, grow farther than the

Supplementary Table 3. Risk of bias analysis

	Random sequence generation (selection bias)	Allocation concealment (selection bias)	Blinding of participants and personnel (performance bias)	Blinding of outcome assessment (detection bias)	Incomplete outcome data (attrition bias)	Selective reporting (reporting bias)	Other bias
Akinbiyi *et al.* [14]							
Khalid *et al.* [12]							
Hoang *et al.* [15]							
Duan *et al.* [16]							
Sclafani *et al.* [13]							

*Green = low risk; yellow = unclear risk; red = high risk

Table 1. Characteristics of the reviewed studies

Author	Year of publication	Aim of study	Study design	Location	Control and intervention	Sample size	Sample characteristics	Study outcomes	Level of evidence
Akinbiyi et al.	2020	Evaluating effectivity (changes in skin lesion or recurrence) of medical intervention, excision, and postoperative radiotherapy for keloid	Retrospective cohort	Dermatology Department – Plastic Surgery Division, University of Pennsylvania Health System	- 95 lesions treated with topical and/or intralesional corticosteroid (without excision/ radiotherapy) - 94 lesions treated with excision with or without a history of corticosteroid therapy (without radiotherapy) - 95 lesions were treated with excision followed by radiotherapy within 24–48 hours. Radiotherapy was given in 3–4 consecutive fractions with a dose of 3-8 Gy**	284 keloid lesions	- Age 39.1 years old (IQR 26.1–53) - 68.1% female - 68.1% African American	- Median follow-up: 15.4 months (IQR 5.5-30.6 months). The medical intervention improved cosmesis and complaints by 84.6% and 72.5% and was applicable for patients refusing or unable to undergo surgical intervention.* - Recurrence rate of surgery vs. surgery + RT was 37.2% and 37.9%, respectively, with median time until recurrence of 290 and 316.5 days (P=0.41). Postoperative corticosteroid adjuvant therapy increased the chance of recurrence (OR: 9.5). Radiation prescribed at > 5 Gy and BED (a/b=2,08) above 51.1 Gy reduced the recurrence risk (P< 0.01). - Patients receiving postoperative RT had higher complication rate compared to conventional surgery alone (17.9% vs. 6.3%) with greater OR observed for keloid in extremities (OR 19.51, P< 0.05), regardless of lesion size (OR 1, P< 0.05). There was no complication needing further surgical intervention or hospital admission.	3
Khalid et al.	2018	Evaluating effectivity of 5-FU/TAC intralesional injection with post-excision radiotherapy for ear keloids	Randomized clinical trial	Jinnah Burn and Reconstructive Surgery Centre, Allama Iqbal Medical College, Lahore	- Group A: 30 patients receiving excision + 5-FU/TAC intraoperative intralesional injection, followed by monthly injection for 2 months. Injections were continued if hypertrophy occurred after the last injection until it flattened - Group B: 30 patients receiving excision and electron radiotherapy 2x5 Gy within 24 hours after operation for 2 consecutive days. An additional 0.5 cm radiation margin was added around the suture wound.	60 patients	- Age range 12–65 years (group A median 30.9 vs. group B median 32.73) - Female: male ratio (group A 1:3.28 vs group B 1:2.34) - > 50% had a history of ear piercing, with an average time of 4 years until the occurrence of skin lesion.	- Minimal follow-up of 12 months, median 19 months. Better efficacy in group A compared with B (recurrence rate 26.67% vs. 56.67%, P=0.01). The time until recurrence was around 7 months. - Complications such as epidermolysis and wound dehiscence (6.67%) were observed in group A and erythema (10%) in group B; improved with conventional therapy within weeks.	2

Table 1. Continued

Author	Year of publication	Aim of study	Study design	Location	Control and intervention	Sample size	Sample characteristics	Study outcomes	Level of evidence
Hoang et al.	2017	Evaluating recurrence and complication rate of excision vs. excision + external radiation vs excision + HDR brachytherapy	Retrospective study	Cedars-Sinai Medical Centre, Los Angeles, United States	- 20 patients (28 keloid lesions) underwent excision; 24 patients (39 keloid lesions) received postoperative HDR brachytherapy; 84 patients (197 lesions) received postoperative external irradiation. -Single lumen interstitial HDR brachytherapy was set intraoperatively following excision and taken out after therapy. Brachytherapy utilizing Iridium-192, prescribed at 8–12 Gy over a single fraction, with 5 mm distance from the source. External radiation using electron (Linac) or superficial X-ray of dose 9–30 Gy over 1–10 fractions, within 36 hours after excision. Electron radiation was set at 6 or 9 MeV prescribed to the 90% isodose line atop a 0.5–1 cm silicon bolus. Radiation field encompassed operation wound with additional 3-5 mm margin. Superficial X-ray utilizing 80-100 kVp, with a target-to-skin distance of 15–25 cm prescribed to maximum depth with 90% isodose to target area similar to that of the electron irradiation and additional 0.5–1 cm horizontal margin. An additional 1–2 mm lead block to protect surrounding non-target areas.	128 patients (264 lesions)	- Age between 14–83 years old (median brachytherapy 49 years, EBRT 43 years, and conventional surgery 50 years); - 77% female - 50% African American - 53% single lesion	- Recurrence rate was 54% for patients treated with surgery alone (median follow-up until recurrence 9 months), 19% for patients receiving operation and external irradiation (median time 42 months), and 23% for patients receiving postoperative HDR brachytherapy (median time 12 months) with a significant difference ($P< 0.05$). - External radiation was shown to be superior in delaying recurrence episodes by 2.5 years compared with brachytherapy. - No radiotherapy toxicity greater than 1st degree was observed. 16% of patients treated with postoperative brachytherapy had an infection, open wound, erythema, or hyperpigmentation. As for the EBRT group, 2% of patients experienced erythema or hyperpigmentation. Overall, 96% of patients receiving postoperative radiotherapy did not suffer from complications.	3
Duan et al.	2015	Evaluating effectivity and toxicity of postoperative keloid radiotherapy (brachytherapy vs. electron EBRT)	Retrospective study	Department of Oncology, Taihe Hospital, Shiyan, People's Republic of China	- 44 patients received HDR brachytherapy of 1x8 Gy + 3x3 Gy or 4x5 Gy using 192Ir within 12 hours after surgery. - 34 patients received HDR brachytherapy of 4x5 Gy or 6x3 Gy using 60Co. - 38 patients received electron EBRT of dose 13x2 Gy or 15x2 Gy set at 4, 6, or 9 MeV	116 patients	- 37.9% aged 21–30 years old (range 15–60 years old) - 72.4% female gender - Most commonly on the sternum (22.4%)	Median follow-up of 46.5 months (10–120 months): recurrence was found in 18 patients with a median time of 16.7 months (10–30 months). Local control between patients receiving hypofraction (> 2 Gy) compared to conventional fraction were 88.5% and 76.3%. BED > 30 Gy was superior (89.7% vs 79.3%). Similar local control was observed comparing the different radiation modalities and doses ($P=0.094$). The recurrence rate of brachytherapy and EBRT were 11.5 and 23.7%, respectively. Based on CTCAE v3.0, no toxicity greater than 1st degree was observed. Two patients had middle-esophageal cancer 5 and 6 years after radiation; however, it was distant from the area of radiation which questioned the causative relationship.	3

Table 1. Continued

Author	Year of publication	Aim of study	Study design	Location	Control and intervention	Sample size	Sample characteristics	Study outcomes	Level of evidence
Sclafani et al.	1996	Evaluating corticosteroid injection vs. radiotherapy in preventing ear keloid recurrence	Randomized clinical trial	Otolaryngology clinic, The New York Eye & Ear Infirmary (NYEEI)	- 12 keloid lesions treated with postoperative steroid injection. - 16 lesions treated with postoperative superficial 100 kVp X-ray or electron irradiation, prescribed at a dose of 7 or 10 Gy over a single fraction, within 3 hours after surgery. - 3 lesions neither treated with radiation nor steroid injection.	26 patients (31 keloid lesions)	- Median age among the groups ranged between 27–29.4 years - Female: male gender ratios receiving steroid and radiation therapy were 5:1 and 7:1, respectively - 76.9% were African American - Almost all lesions were related to ear piercings	Median follow-up of 19 months (surgery + radiation and surgery + steroid injection groups) and 9 months (surgery alone) with an overall median follow-up period of 18 months. 12.5% of patients receiving surgery + radiation had a recurrence. 33% of patients receiving surgery + steroid injection and surgery alone had recurrence episodes. The median time until recurrence was 17, 18, and 9 months for surgery + radiation, surgery + steroid, and conventional surgery, respectively. No complications of hyper/ hypopigmentation, wound healing abnormality, swelling, chondritis, or skin ulcer was observed	2

*Cosmesis and complaints were assessed as recurrence rate cannot be measured. ** Types of radiotherapy not specified.
Abbreviations: 5-FU/TAC, 5-fluorouracil/triamcinolone acetonide; BED, Biological Effective Dose; Co, cobalt; CTCAE, common terminology criteria for adverse events; EBRT, external beam radiation therapy; HDR, high dose rate; IQR, interquartile range; Ir, iridium; kVp, kilovoltage peak; OR, odds ratio; Linac, linear accelerator; RT, radiotherapy

initial extent of the injury with histological features of multiple thick-hyalinized and eosinophilic collagen bundles [17,18]. Wound healing normally involves inflammation, proliferation, and remodeling. In the inflammation phase, tissue damage activates pro-inflammatory cytokines, which trigger fibroblast and keratinocyte migration for epithelization during the proliferation phase at days 4-7, followed by fibroblast reduction, blood vessel occlusion, and fibrous tissue formation during the remodeling phase. Abnormal collagen production, extracellular matrix collagen degradation, and certain cytokines such as transforming growth factor (TGF)-β1 and interleukin (IL)-6 are associated with hypertrophic scars and keloid formation [19,20]. Although not fully understood, radiation is hypothesized to mediate its effect by modifying humoral and cellular mediators associated with fibroblast proliferation [21]. Additionally, it is also suggested to affect angiogenesis, apoptosis, and cell aging, thereby inhibiting collagen production [22].

Gender, age, and history of ear trauma were some of the highlighted risk factors found in the studies. Looking at the cases presented earlier, the patients were Asian females aged 18 and 23 with a history of ear trauma before keloid formation. The studies suggested that the female gender was indeed correlated with a higher incidence, although the risk of keloid formation does not differ significantly [12,14–16,22]. History of ear trauma at productive age between 10-30 years old was also associated with greater risk, as shown by Khalid and Sclafani *et al* [12,13,22]. Hoang *et al.* found that Asians were ranked third (13%) after the African-American and Caucasian races in terms of keloid incidence [15]. Keloid formation during pregnancy, as seen in Case 1, may be due to hormonal changes mediated by estrogen. Such an observation was also found in the study by Kim *et al.*, where a patient had keloid recurrence in her second pregnancy, despite already having surgery during her first pregnancy [23]. However, limited data is available regarding pregnancy-induced keloid formation.

Overall, the assessed risks of bias were high because most of the studies were observational. Given that different interventions such as surgery, injections, and radiotherapy were employed, blinding of participants and personnel was not possible; hence performance bias was categorized as low. Despite those limitations, the studies

provided useful scientific evidence in line with the aim of this study.

The two randomized clinical trials found in the literature search had a few weaknesses. Khalid *et al.* tend to mostly discuss intralesional steroid injections with outcomes determined by plastic surgery department assessment. The lack of details on electron radiation, for instance, bolus and energy used, cast doubt upon the 56.67% recurrence rate until further subgroup analysis can be made [12]. Meanwhile, Sclafani *et al.* did not explain the reasoning behind 16 patients whose outcomes were excluded, along with unclear radiotherapy specifications as well as a lack of information about allocation concealment. The conventional surgery recurrence rate of 33% was also compromised since only three patients were part of the group [13].

Radiotherapy was shown to be the superior adjuvant therapy for keloid management, reflected by the lower recurrence rate. The lowest recurrence rate of 11.5% was found in the radiotherapy group, compared to steroid injection (26.67%) and conventional surgery (33%). However, the median time until recurrence for radiotherapy was six months, which was shorter than the other groups [12–16]. Provided such information, a longer follow-up period is recommended for our two cases, even though the 12 months of follow-up effectively showed no sign of recurrence.

The subsequent question is pointed out toward comparing internal (brachytherapy) and external radiotherapy. Among the different types of external radiotherapy (electron, superficial, and orthovoltage X-ray), electron radiation is preferable due to its superior dose distribution curve, steeper fall-off dose, and better-condensed radiation deposition [22]. On the other hand, brachytherapy is capable of administrating high radiation doses to a more localized area, minimizing damage to the surrounding healthy tissue [2]. Hoang *et al.* and Duan *et al.* found similar recurrence rates between external radiotherapy (19% and 23.7%) and brachytherapy (11.5% and 23%) [15,16]. Howbeit, installation of brachytherapy requires a special applicator, which poses additional costs to radiotherapy centers. Thus, when brachytherapy is inaccessible, external radiotherapy can be used as a suitable alternative with comparable efficacy.

Looking at the radiation dose, three studies analyzed the optimum biologically effective dose (BED). Akinbiyi *et al.* found a significantly lower recurrence rate when the BED was set at > 51.1 Gy (51.1-69.9 Gy) and the dose per fraction was > 5 Gy [14]. Similarly, Duan *et al.* supported that BED > 30 Gy ($\alpha/\beta = 10$) exerted better tumor control with a recurrence rate of 10.3% vs. BED < 30 Gy with 23.7% [16]. Meanwhile, although Hoang *et al.* stated the BED used in the study (BED $\alpha/\beta = 2.08$ for external radiation 22-71.7 Gy and brachytherapy 46.8-81.2 Gy; BED $\alpha/\beta = 10$ for external irradiation 11.7-32.8 Gy and brachytherapy 14.4-26.4 Gy), no conclusion can be derived from their data [15].

Radiation dose rationalization took into consideration the location of lesions. Less skin tension in the ear, head, and neck resulted in a better prognosis when compared to lesions on the chest and extremities. Additionally, skin tension from the operation also contributes to a greater chance of recurrence [2]. A meta-analysis by Mankowski *et al.* suggested that a lower BED of 15–22.5 Gy ($\alpha/\beta = 10$) for ear keloids may reduce the recurrence rate to ≤ 5%, while simultaneously having lower side effect risk [24]. The radiation dose prescribed for our two cases was 3 × 6 Gy with BED ($\alpha/\beta = 10$) at 28.8 Gy, which, combined with a lesion location of the ear, should yield a better prognosis with an expected recurrence rate of < 5%.

The time interval between surgery and radiotherapy varies between studies, ranging from 3–48 hours. All studies stated the time interval until postoperative radiotherapy, except for Duan *et al.*, who only mentioned the time interval for brachytherapy being 12 hours post-surgery. Akinbiyi *et al.* also analyzed the effect of early (within 25 hours) and delayed (within 29.5 hours) adjuvant radiotherapy, suggesting that earlier radiotherapy had a significantly greater risk for recurrence ($P = 0.01$). That being said, there was a discrepancy between the number of samples of early and delayed sub-group analysis (36 vs. 59 samples) [12–16]. On the contrary, a systematic review by van Leeuwen *et al.* suggested that the group receiving earlier radiotherapy within 7 hours post-surgery had a lower recurrence rate than 7–24 hours and > 24 hours after surgery (14 vs. 25 vs. 21.5%) [25]. The postoperative radiotherapy of our two cases was administered within 7 hours, per this study.

All studies showed that adjuvant radiotherapy

toxicity was well-tolerated. Some radiation toxicity observed included erythema, hyperpigmentation, infection, or open wounds following external or internal radiation. Epidermolysis and wound dehiscence were some side effects monitored in the steroid injection group. A higher complication rate for adjuvant radiotherapy than conventional surgery was recognized in the study by Akinbiyi *et al.*, but the side effects that needed further medical intervention were not elaborated [12–16]. Both the cases presented in this article showed first-degree radiation toxicity after the intervention, which was well-tolerated in accordance with these studies.

CONCLUSION

To conclude, both case reports presented had risk factors of higher keloid incidence, namely the female gender, young age, Asian ethnicity, and history of trauma. Based on the available literature, postoperative radiotherapy is a promising modality to improve local wound control and recurrence rates. Although brachytherapy offers better efficacy, its use is limited in terms of accessibility, making external radiation a suitable alternative. All the different interventions monitored in this systematic review are relatively well-tolerated. A relatively high risk of bias was the main limitation of the reviewed studies. This systematic review summarized the available evidence regarding keloid management, including those presented in our case reports, while also encouraging more randomized clinical trials focusing on postoperative external radiation.

Conflict of interest: None declared.

REFERENCES

1. Bao Y, Xu S, Pan Z, et al. Comparative efficacy and safety of common therapies in keloids and hypertrophic scars: a systematic review and meta-analysis. Aesthetic Plast Surg. 2020;44(1):207–18.
2. Xu J, Yang E, Yu N-Z, et al. Radiation therapy in keloids treatment: history, strategy, effectiveness, and complication. Chin Med J (Engl). 2017;130(14):1715–21.
3. Davis SA, Feldman SR, McMichael AJ. Management of keloids in the United States, 1990–2009: an analysis of the national ambulatory medical care survey. Dermatol Surg. 2013;39(7):988–94.
4. Sun L-M, Wang K-H, Lee Y-CG. Keloid incidence in Asian people and its comorbidity with other fibrosis-related diseases: a nationwide population-based study. Arch Dermatol Res. 2014;306(9):803–8.
5. Lee H, Jang Y. Recent understandings of biology, prophylaxis and treatment strategies for hypertrophic scars and keloids. Int J Mol Sci. 2018;19(3):711.
6. Wolfram D, Tzankov A, Pülzl P, et al. Hypertrophic scars and keloids—a review of their pathophysiology, risk factors, and therapeutic management. Dermatol Surg. 2009;35(2):171–81.
7. Ellis MM, Jones LR, Siddiqui F, et al. The efficacy of surgical excision plus adjuvant multimodal therapies in the treatment of keloids: a systematic review and meta-analysis. Dermatol Surg. 2020;46(8):1054–9.
8. Shin JY, Lee J-W, Roh S-G, et al. A comparison of the effectiveness of triamcinolone and radiation therapy for ear keloids after surgical excision: a systematic review and meta-analysis. Plast Reconstr Surg. 2016;137(6):1718–25.
9. Moher D, Liberati A, Tetzlaff J, et al. Preferred reporting items for systematic reviews and meta-analyses: the PRISMA statement. PLoS Med. 2009;6(7):e1000097.
10. The Centre for Evidence-Based Medicine - University of Oxford. OCEBM Levels of Evidence - CEBM. [Internet]. [cited 2019 Apr 13] Available from: https://www.cebm.net/2016/05/ocebm-levels-of-evidence/
11. Higgins JPT, Altman DG, Gotzsche PC, et al. The cochrane collaboration's tool for assessing risk of bias in randomised trials. BMJ. 2011;343:d5928–d5928.
12. Khalid FA, Farooq UK, Saleem M, et al. The efficacy of excision followed by intralesional 5-fluorouracil and triamcinolone acetonide versus excision followed by radiotherapy in the treatment of ear keloids: a randomized control trial. Burns. 2018;44(6):1489–95.
13. Sclafani AP, Gordon L, Chadha M, et al. Prevention of earlobe keloid recurrence with postoperative corticosteroid injections versus radiation therapy. Dermatol Surg. 1996;22:569–74.
14. Akinbiyi T, Kozak GM, Davis HD, et al. Contemporary treatment of keloids: a 10-year institutional experience with medical management, surgical excision, and radiation therapy. Am J Surg. 2021;221(4):689-96.
15. Hoang D, Reznik R, Orgel M, et al. Surgical excision and adjuvant brachytherapy vs external beam radiation for the effective treatment of keloids: 10-year Institutional retrospective analysis. Aesthet Surg J. 2017;37(2):212–25.
16. Duan Q, Liu J, Luo Z, et al. Postoperative brachytherapy and electron beam irradiation for keloids: a single institution retrospective analysis. Mol Clin Oncol. 2015;3(3):550-4.
17. Tsai C-H, Ogawa R. Keloid research: current status and future directions. Scars Burns Heal. 2019;5:205951311986865.
18. Cipto H, Suriadiredja ASD. Tumor kulit. In: menaldi SLSW, Bramono K, Indriatmi W (Eds). Ilmu penyakit kulit dan kelamin. Jakarta: Badan Penerbit Fakultas Kedokteran Universitas Indonesia; 2017.
19. Mari W, Alsabri SG, Tabal N, et al. Novel insights on

understanding of keloid scar: article review. J Am Coll Clin Wound Spec. 2015;7(1–3):1–7.

20. Nangole FW, Agak GW. Keloid pathophysiology: Fibroblast or inflammatory disorders? JPRAS Open. 2019;22:44–54.
21. Eng TY, Abugideiri M, Chen TW, et al. Radiation therapy for benign disease: Keloids, macular degeneration, orbital pseudotumor, pterygium, peyronie disease, trigeminal neuralgia. Hematol Oncol Clin North Am. 2020;34(1):229–51.
22. Ojeh N, Bharatha A, Gaur U, et al. Keloids: current and emerging therapies. Scars Burns Heal. 2020;6:205951312094049.
23. Kim H-D, Hwang S-M, Lim K-R, et al. Recurrent auricular keloids during pregnancy. Arch Plast Surg. 2013;40(1):70.
24. Mankowski P, Kanevsky J, Tomlinson J,et al. Optimizing radiotherapy for keloids: a meta-analysis systematic review comparing recurrence rates between different radiation modalities. Ann Plast Surg. 2017;78(4):403–11.
25. van Leeuwen MCE, Stokmans SC, Bulstra AEJ, et al. Surgical excision with adjuvant irradiation for treatment of keloid scars: a systematic review. Plast Reconstr Surg - Glob Open. 2015;3(7):e440.