IJD Case Report

Atypical annular presentation of tufted angioma: a case report

Anchitha H, MD[1]
Pramod Kumar, MD [1]
Deepti Dsouza, MD [1*]
Pooja K Suresh, MD [2]

1. Department of Dermatology, Kasturba Medical College, Mangalore, Manipal Academy of Higher Education, Manipal, Karnataka, India
2. Department of Pathology, Kasturba Medical College, Mangalore, Manipal Academy of Higher Education, Manipal, Karnataka, India

*Corresponding author:
Deepti Dsouza, MD
Department of Dermatology, Kasturba Medical College, Mangalore, Karnataka 575001
E-mail: deepti.dsouza@manipal.edu

Received: 1 October 2022
Accepted: 24 February 2023

Tufted angioma is an uncommon vascular benign tumor of infancy or early childhood with slow and indolent growth. We report the case of a four-year-old boy with an asymptomatic annular lesion over the nape of the neck resembling granuloma annulare. Punch biopsy revealed multiple scattered vascular lobules or tufts. Aggregates of closely packed, dilated to compressed vascular spaces with plump endothelial cell lining were seen in the dermis, confirming the diagnosis of tufted angioma. Immunohistochemical positivity was present with CD31 and CD34 staining of endothelial cells. It is a slow-growing tumor; Kasabach–Merritt syndrome (KMS) and consumptive coagulopathy are rare complications. Blood coagulation profiles were within normal limits. In our case, the lack of reliable distinguishing characteristics of the vascular tumor and atypical annular presentation was a source of diagnostic confusion. Tenderness, typically present in tufted angiomas, was absent in our patient. This unusual case illustrates that clinicians should recognize an annular configuration as an atypical manifestation of tufted angioma.

Keywords: vascular tumor, hemangioma, granuloma annulare, Neoplasms

Iran J Dermatol 2023; 26: 226-228

DOI: 10.22034/ijd.2023.363991.1616

INTRODUTION

Tufted angioma, earlier identified as angioblastoma of Nakagawa [1], is an uncommon vascular benign tumor of infancy or early childhood with slow and indolent growth. It was coined after its pathognomonic feature of "tufts" of capillaries in the dermis [2]. They usually present as dusky red to violaceous plaques or mottled patches with telangiectasia, occasionally observed with hyperhidrosis or hypertrichosis [2,3]. At birth, lesions are absent or manifest as erythematous to brown discoloration. Here, we report the case of a patient with a rare clinical form of tufted angioma.

CASE REPORT

A four-year-old boy presented to the dermatology outpatient department with a gradually progressive raised lesion over the nape of the neck for the past two years. The mother reported that the lesion initially started as a small brown patch. There was no history of pain, increased sweating, itching, or trauma. There were no similar lesions anywhere else in the body. On clinical examination, a single 4×5 cm hyperpigmented annular plaque was present on the nape of the neck with a raised border. The lower border had a corrugated surface. Superimposed papules were present. There was no telangiectasia. Excessive hair was seen around the lesion. On palpation, it was firm, non-tender, non-compressible, and mildly infiltrated (Figure 1A). Systemic examination, hemogram, and serum biochemistry panel were normal. A clinical

Please cite this article as: H A, Kumar P, Dsouza D, Suresh P. Atypical annular presentation of tufted angioma: a case report. Iran J Dermatol. 2023; 26(4): 226-228.

diagnosis of granuloma annulare was considered.

Punch biopsy revealed skin lined by irregular acanthosis of the epidermis and dermis with multiple scattered lobules or tufts of capillary-type vessels. Aggregates of closely packed, dilated to compressed vascular spaces with plump endothelial cell lining were seen in the dermis, imparting a 'cannonball' or 'glomerular' appearance (Figure 1B-E). Mitosis was rare. Periodic acid-Schiff staining was negative. The histopathological features were indicative of tufted angioma. Immunohistochemistry revealed positive CD31 and CD34 antibodies in the endothelial cells, confirming the vascular nature of the lesion (Figure 1D-E). Blood coagulation profiles were within normal limits. Surgical excision was advised, but parents did not favor any active intervention. The patient was brought to us again a year later with new lesions over the back; cryotherapy treatment was initiated as their preferred treatment.

DISCUSSION

Approximately 50% of tufted angiomas manifest within the first year of life [4]. The etiopathogenesis of this tumor is unclear. They have varied clinical presentation; the most common forms are red-violaceous indurated or nodular plaques, mottled patches with telangiectasia, and less frequently as a firm exophytic or violaceous nodule [3]. These clinical presentations are widely reported in most of the case series on tufted angiomas in the literature. None of these studies came across an annular presentation of tufted angioma [2,4,5]. Our patient had a rare presentation with lesions like granuloma annulare with no features suggestive of vascular pathogenesis. Granuloma annulare is an inflammatory, benign condition seen in young adults and pediatric populations [6]. They present as painless cutaneous papules with annular configuration, favoring sites such as the dorsum of feet or hands, buttocks, and scalp [6]. The presence of the lesion over the neck in the present case is classical for tufted angioma; other commonly reported areas are the shoulders and trunk [2]. Hyperhidrosis and hypertrichosis can occur over the lesion; peripheral hypertrichosis was seen in our case. Tenderness, typically present in tufted angiomas, was absent in our patient. There have been cases reporting paroxysmal episodes of pain [2].

The age of onset, the evolution of the lesion,

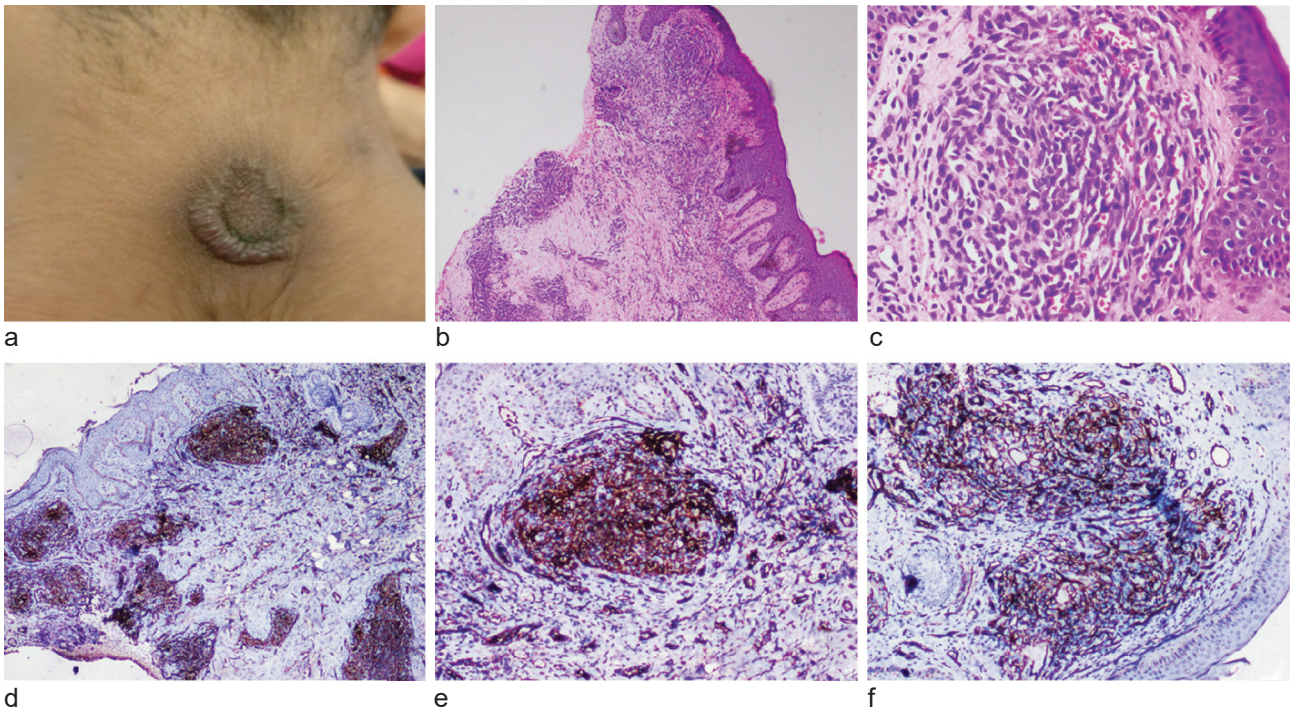

Figure 1. a) Annular lesion on the upper back. b) Histopathology sections show multiple, discrete lobules of capillary-type blood vessels in the dermis showing a cannonball appearance. c) Higher power shows lobules composed of spindle to oval-shaped cells with spaces in between containing RBCs. d,e) Immunohistochemical marker CD34 highlighting the tufted nature (cannonball appearance) of capillary-type blood vessels in the dermis. f) Immunohistochemical marker CD31 showing membranous positivity in endothelial cells.

and clinical examination are sufficient to diagnose a tufted angioma in most cases. In our case, the lack of reliable distinguishing characteristics of the vascular tumor and the atypical annular presentation was a source of diagnostic confusion. Usually, the clinical presentation of tufted angioma is similar to kaposiform hemangioendothelioma (KHE), infantile hemangiopericytoma (IHP), and common hemangioma [3]. Whereas a common haemangioma presents as a soft and compressible lesion, a tufted angioma presents as a tender and indurated lesion. KHEs are large irregular infiltrative lesions with biphasic patterns composed of vascular and lymphatic components. The vascular component shows slit-like vascular lumina and significant desmoplastic response. However, our case did not show the infiltrative growth pattern with stromal response and dilated lymphatic channels. Immunohistochemistry with lymphatic marker D2-40 was not done as it was unavailable at our center. KHEs are usually associated with consumption coagulopathy and Kasabach–Merritt syndrome (KMS), which were absent in our case [7].

As tufted angiomas show clinical variability, histologic examination and immunohistochemistry are essential for diagnosis. Tufted angiomas show a characteristic "cannonball" appearance due to the proliferating endothelial cells forming tufts or lobules in the dermis [2]. Immunohistochemistry shows positivity for endothelial and lymphatic vascular markers CD34, CD31, and D2-40 [5]. It is a slow-growing tumor; Kasabach–Merritt syndrome (KMS) and consumptive coagulopathy are rare complications. Due to the aggressive nature of KMS, it is prudent to do a thorough hematological workup with a coagulation profile in all patients.

Treatment options include surgical excision, intralesional steroids, cryotherapy, systemic corticosteroids, and pulsed-dye laser [3,8]. Although spontaneous regression in tufted angioma is rare, unlike hemangioma, a non-interventional wait-and-watch approach with a regular follow-up to look for complications is a valid measure in uncomplicated cases.

CONCLUSION

A diagnosis of tufted angioma is naturally suspected in a child with a red or violaceous vascular lesion; our patient had a rare granuloma annulare-like clinical manifestation. Tufted angioma is a slowly growing tumor, but due to the aggressive nature of KMS, it is prudent to do a thorough hematological workup. This unusual case illustrates that an annular configuration should be recognized by clinicians as a possibility of an atypical manifestation of tufted angioma, hence avoiding excessive testing, misdiagnosis, and, eventually, inappropriate therapy.

Authors contributions

All authors contributed equally to this study. Dr Anchitha wrote the paper. Dr Pramod Kumar was mentor/ guide. Dr Pooja is the pathologist who reported this case. Dr Deepti Dsouza and Dr Pooja K Suresh revised the manuscript and supervised it. All authors read and approved the final manuscript.

Acknowledgment

None.

Funding source

None.

Conflict of Interest: None declared.

REFERENCES

1. Nakagawa K. Case report of angioblastoma of the skin. Jpn J Dermatol. 1949;59:92-4.
2. Osio A, Fraitag S, Hadj-Rabia S, et al. Clinical spectrum of tufted angiomas in childhood: a report of 13 cases and a review of the literature. Arch Dermatol. 2010;146(7):758-763.
3. Herron MD, Coffin CM, Vanderhooft SL. Tufted angiomas: variability of the clinical morphology. Pediatr Dermatol. 2002;19(5):394-401.
4. Okada E, Tamura A, Ishikawa O, et al. Tufted angioma (angioblastoma): case report and review of 41 cases in the Japanese literature. Clin Exp Dermatol. 2000;25(8):627-630.
5. Su X, Liu Y, Liu Y, Ma C. A retrospective study: clinicopathological and immunohistochemical analysis of 54 cases of tufted angioma. Indian J Dermatol Venereol Leprol. 2020;86(1):24-32.
6. Katsarou A, Vavouli C, Balamoti E, et al. Granuloma annulare in children. J Am Acad Dermatol. 2014;70(5):AB145.
7. Chundriger Q, Tariq MU, Abdul-Ghafar J, et al. Kaposiform Hemangioendothelioma: clinicopathological characteristics of 8 cases of a rare vascular tumor and review of literature. Diagn Pathol. 2021 Mar 15;16(1):23.
8. Fabbri N, Quarantotto F, Caruso A, et al. Surgical excision of a tufted angioma of the hand in an adult—a rare case report with a review of literature. AME Case Reports. 2019;3:7-7.