

Cutaneous granulomatous reaction post intravesical BCG installation: a case report

Mahmood Farshchian, MD
Elahe Soltanieh, MD
Leila Mosavi, MD

Department of Dermatology, Sina (Farshchian) Hospital, Hamedan University of Medical Sciences, Hamedan, Iran

*Corresponding Author:
Elahe Soltanieh, MD
Department of Dermatology, Sina (Farshchian) Hospital, Hamedan University of Medical Sciences, Hamedan, Iran
Email: soltaniehe@yahoo.com*

Conflict of interest: None to declare

*Received: 8 August 2011
Accepted: 10 October 2011*

Intravesical instillation of Bacillus Calmette-Guerin (BCG) has become an established adjuvant treatment for superficial bladder carcinoma. This treatment is associated with a relatively high rate of side effects which are mostly reversible spontaneously or can be treated symptomatically. Serious systemic side effects are less frequent. One of rare complications is granulomatous cutaneous reaction. We report a 50-year-old man with disseminated papules and plaques following intravesical BCG.

Keywords: Bacillus Calmette-Guerin, Cutaneous granulomatous, lupus vulgaris

Iran J Dermatol 2012; 15: 95-98

INTRODUCTION

Transitional cell carcinoma of the bladder is an aggressive and potentially fatal malignancy. In 1990, the US Food and Drug Administration approved the use of intravesical Bacillus Calmette-Guérin (BCG) for the treatment of superficial bladder cancer¹. BCG, which is an inactivated form of the Mycobacterium tuberculosis, induces both cell-mediated immunity and a variety of cytokines into the urine of patients with superficial transitional cell carcinoma². Through these immune responses, a significant reduction in the rate of disease progression and mortality rate is achieved with intravesical BCG therapy. In addition to the effectiveness against superficial tumors, BCG is the treatment of choice for carcinoma in situ of the bladder³. BCG has been used to treat transitional cell carcinoma since 1976 and has been reported to eradicate disease in more than 70% of the patients with in situ and stage I disease⁴. While the majority of patients tolerate intravesical BCG

treatment well, a number of adverse reactions (e.g. fever, hematuria, dysuria, nausea, and malaise) have been reported. More serious complications include granulomatous prostatitis, pneumonitis, and hepatitis^{5,6}. The frequency of adverse effects was reported in a study of more than 1,200 patients who received this type of immunotherapy. The results revealed only an incidence rate of 2.9% for high fever (>39°C), 1.0% for major hematuria, 0.9% for granulomatous prostatitis, 0.7% for granulomatous pneumonitis/hepatitis, 0.5% for arthritis or arthralgia, 0.4% for epididymo-orchitis, 0.4% for life-threatening BCG sepsis, 0.3% for urethral obstruction, 0.2% for bladder contracture, 0.1% for renal abscess, and 0.1% for cytopenia. In addition, there have been reports of rare BCG complications such as mycotic aneurysms, glomerulonephritis, choroiditis, nephrogenic adenoma, suppurative lymphadenitis, cardiac toxicity, and musculoskeletal lesions. Nevertheless, BCG treatment is still considered to be a reasonably safe and effective cancer therapy⁷⁻⁹. Cutaneous complications of

BCG vaccination include localized or generalized tuberculids, lupus vulgaris, scrofuloderma and other non-specific reaction such as fever and local inflammation¹⁰. We herein report a 50-year-old man with granulomatous lesions like lupus vulgaris secondary to intravesical BCG therapy for bladder cancer.

CASE REPORT

A 50-year-old man presented with a 6-month history of progressive developing cutaneous lesions following intravesical instillation of BCG. These lesions were neither painful nor itchy. According to his medical history, the patient underwent transurethral resection of a bladder tumor with a diagnosis of a grade II/IV noninvasive transitional-cell carcinoma 18 months ago and then received BCG maintenance instillation therapy. The first and second six BCG treatments were well tolerated. Six months prior to admission to the department of dermatology, the patient received his last BCG treatment (his 18th BCG treatment overall). A few days after the last instillation, he developed generalized multiple granulomatous cutaneous lesions. He had no cough, dyspnea, fever or weakness. His family history was negative for bladder carcinoma. On physical examination, multiple brown to reddish and slightly elevated papules and plaques were observed all over his body, ranging from 1-10mm

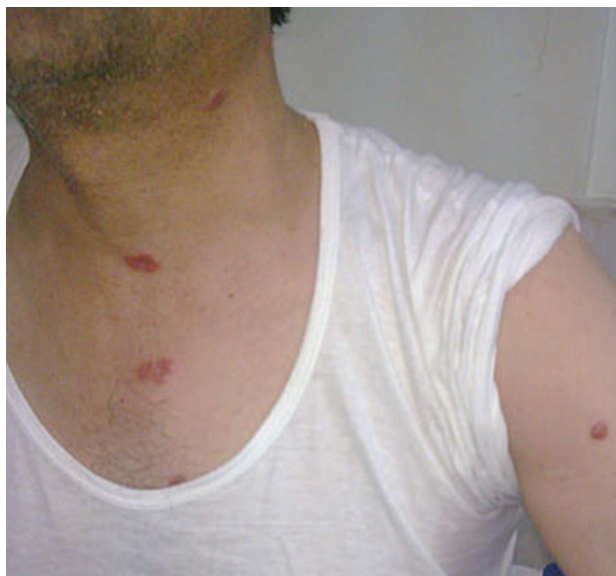

Figure 1. Multiple brown to reddish and slightly elevated papules and plaques

in diameter (Figure 1). Laboratory examination revealed an elevated erythrocyte sedimentation rate but routine hematology, urinalysis, serum biochemistry, and serum lipid were normal. PPD was 10mm. Blood and urine cultures for *Mycobacterium bovis* were negative. Chest X-ray did not show any abnormalities. Biopsies of the lesion showed a skin tissue with an intact rather acanthotic epidermis. The dermis revealed severe lymphohistiocytic dermal infiltration including some granuloma formations with multinucleated

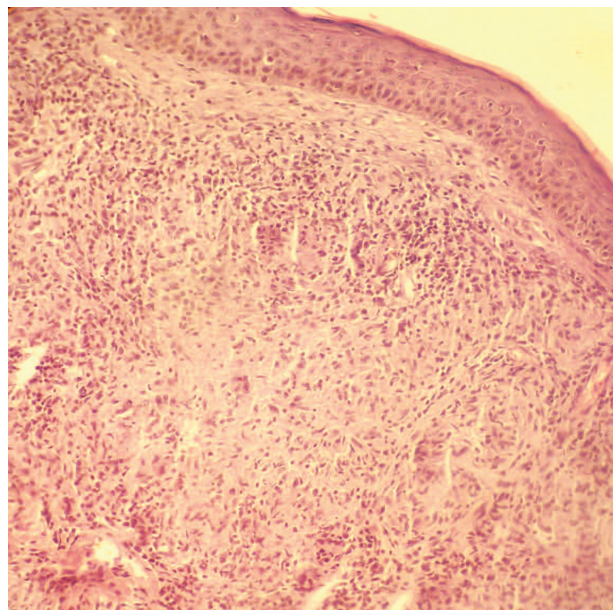


Figure 2. The dermis reveal some granuloma formations with multinucleated giant cells rimmed by lymphocytes (H&E*10).

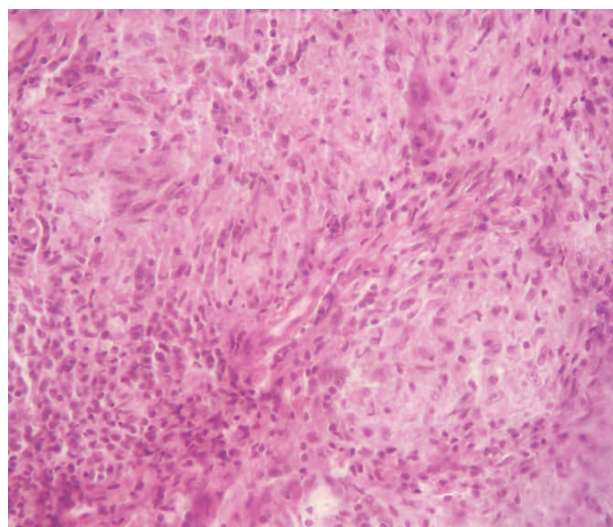


Figure 3. Granuloma formations with multinucleated giant cells rimmed by lymphocytes (H&E*40)

giant cells, rimmed by lymphocytes. No evidence of any caseating necrosis was observed (Figure 2, 3).

Although blood and urine cultures for *Mycobacterium bovis* were negative, a presumptive diagnosis of disseminated cutaneous granulomatous reaction (like lupus vulgaris) was justified by clinical appearance and histologic findings.

He was treated by isoniazid (300mg/day), rifampin (600mg/twice a day), ethambutol (900mg/day), pyrazinamide (1625mg/day) and vitamin B6 for 4 months and then received isoniazid and rifampin for 2 months. The lesion improved after treatment began.

DISCUSSION

BCG is used as immunotherapy in the management of superficial and in situ transitional cell carcinoma of the bladder. The BCG vaccine is usually instilled into the bladder on a monthly basis¹¹.

A study in 1985 demonstrated that more than 70% of patients with superficial and stage I disease experienced complete remission⁴. The method by which BCG provides therapeutic benefit in patients with bladder cancer is unknown. However, it is thought to act as a nonspecific stimulant of the immune system by inducing granulomatous inflammation^{1,12}. Although intravesical therapy is generally safe, local and systemic side effects occur and it is important to be aware of them. Identifying complications early, preventing them when possible and managing them efficiently are critical. Most complications are preventable. Knowing the risks and benefits of chemotherapeutic agents may decrease the short-term and long-term toxicity of these agents¹³. Cutaneous complications of the intravesical BCG have been reported in different articles; for example, Honl et al, reported a pityriasis rosea-like rash secondary to BCG therapy for bladder cancer¹⁴. Yurdakul et al, presented a pure squamous cell carcinoma in an intravesical BCG-treated patient¹⁵. To our knowledge, few cases of granulomatous reaction, mainly involving the liver (granulomatous hepatitis) and the kidneys, have been reported following intravesical BCG instillation but cutaneous granulomas have been rarely reported. A similar case was reported in 2006 in which a patient presented with disseminated tuberculous lesions post intravesical BCG therapy.

They reported the first case of cutaneous granuloma lesions in a patient receiving the above-mentioned treatment¹⁶; similar to our case, her lesions were also disseminated. Then, Kureshi et al reported a 69-year-old man with ulceration of the penile base following intravesical BCG. Biopsy findings showed granulomatous inflammation with foci of dermal necrosis suggestive of a BCG-related granulomatous reaction¹⁷.

Lupus vulgaris and other cutaneous granulomatous lesions are specific complications of BCG vaccination that may develop at the vaccination site, usually a few months after vaccination. Samuel et al, reported a child who received BCG vaccination in China and then developed lupus vulgaris shortly after adoption in the United States¹⁸. Many other studies have reported lupus vulgaris following BCG vaccination. Distant cutaneous granulomas have been described after BCG immunotherapy for malignant melanoma¹¹.

Therefore, cutaneous granulomatous reactions (like lupus vulgaris) have been reported as a complication of BCG vaccination but they are reportedly rare after intravesical BCG. Our patient developed granulomatous lesions like lupus vulgaris following intravesicular treatment with BCG. To our knowledge, this represents the second report of a presumed cutaneous granulomatous reaction in a patient receiving intravesical BCG therapy for bladder carcinoma.

REFERENCES

1. Lamm D. BCG immunotherapy for transitional-cell carcinoma in situ of the bladder. *Oncology* (Williston Park). 1995;9:947-52, 955, discussion 955-65.
2. Bohl A, Brandau S. Immune mechanisms in bacillus calmette-Guerin immunotherapy for superficial bladder cancer. *J Urol* 2003; 170:964-9.
3. Lamm DL. Management of bladder cancer. *J Urol* 2004; 171:2482-3.
4. Schellhammer PF, Ladaga LE, Fillion MB. Bacillus Calmette-Guérin for superficial transitional cell carcinoma of the bladder. *J Urol* 1986; 135:261-4.
5. Lamm DL, Stogdill VD, Stogdill BJ, Crispin RG. Complications of bacillus Calmette-Guérin immunotherapy in 1, 278 patients with bladder cancer. *J Urol* 1986; 135:272-4.
6. Lamm DL, van der Meijden PM, Morales A, et al. Incidence and treatment of complications of bacillus Calmette-Guerin intravesical therapy in superficial bladder cancer. *J Urol* 1992;147: 596-600.

7. Koya MP, Simon MA, Soloway MS. Complications of intravesical therapy for urothelial cancer of the bladder. *J Urol* 2006;175:2004-10.
8. Bornet P, Pujade B, Lacaine F, et al. Tuberculous aneurysm of the femoral artery: a complication of bacilli Calmette-Guérin vaccine immunotherapy: a case report. *J Vasc Surg* 1989; 10:688-92.
9. Izes JK, Bihle W 3rd, Thomas CB. Corticosteroid-associated fatal mycobacterial sepsis occurring 3 years after instillation of intravesical bacillus Calmette-Guérin. *J Urol* 1993;150 (5 pt 1):1498-500.
10. Bologna JL, Jorizzo JL, Rapini RP. *Dermatology*. Second edition. Mosby Elsevier; 2008.
11. Burns T, Breathnach S, Cox N, Griffiths C. *Rook's text book of dermatology*. Wiley-Blackwell. 8th edition; 2010.
12. Groves MJ. Pharmaceutical characterization of *Mycobacterium bovis* bacillus Calmette-Guérin (BCG) vaccine used for the treatment of superficial bladder cancer. *J Pharm Sci* 1993; 82:555-62.
13. Lamm DL. Complications of bacillus Calmette-Guérin immunotherapy. *Urol Clin North Am* 1992; 19:565-72.
14. Honl BA, Keeling JH, Levis CW, Thompson IM. A pityriasis rosea-like eruption secondary to bacillus Calmette-Guérin therapy for bladder cancer. *Cutis* 1996; 57: 447-50.
15. Yurdakul T, Avunduk MC, Piskin MM. Pure squamous cell carcinoma after intravesical BCG treatment. A case report. *Urol Int* 2005; 74:283-5.
16. Ng YH, Bramwell SP, Palmer TJ, Woo WK. Cutaneous mycobacterial infection post intravesical BCG installation. *Surgeon* 2006; 4:57-8.
17. Kureshi F, Kalaaji AN, Halvorson L, et al. Cutaneous complications of intravesical treatments for bladder cancer: granulomatous inflammation of the penis following BCG therapy and penile gangrene following mitomycin therapy. *J Am Acad Dermatol* 2006;55: 328-31.
18. Samuel A, Browning J, Campbell J, Metry D. Bacillus Calmette-Gu vaccine-induced lupus vulgaris in a child adopted from China. *Pediatr Dermatol* 2007;24:E44-6.