

Eruptive Syringoma

Parviz Toossi, MD
 Reza Mahmoud Robati, MD
 Nima Sarrafi-rad, MD
 Sima Kavand, MD

Skin Research Center, Shahid Beheshti
 University of Medical Sciences, Tehran,
 Iran

Corresponding Author:
 Reza Mahmoud Robati, MD
 Skin Research Center, Shahid Beheshti
 University of Medical Sciences, Tehran,
 Iran
 Email: rmroboti@gmail.com

Received: November 24, 2008
 Accepted: January 20, 2009

Abstract

Syringoma is a benign adnexal tumor originated from the intraepidermal portion of eccrine sweat duct. They commonly present as soft, flesh colored to slightly yellow dermal papules on the lower eyelids of healthy individuals. It usually occurs in the peri-pubertal period. There are a few reports of its widespread distribution as eruptive syringoma in the literature. Treatment of this benign condition is cosmetic only in both localized and eruptive form. Herein, a case of a 29 year old female with one year history of eruptive syringomas is presented. (*Iran J Dermatol 2009; 12: 96-98*)

Keywords: adnexal neoplasm, sweat gland, syringoma

Introduction

Syringomas are benign adnexal tumors derived from the intraepidermal portion of eccrine sweat ducts. They occur mainly in women at puberty or later in life ¹. Although occasionally solitary, the lesions are usually multiple and may be present in great numbers. They are small, skin coloured or slightly yellow, soft papules frequently only 1 or 2 mm in diameter. In many patients, the lesions are usually limited to the lower eyelids ². Other sites of predilection are the cheeks, thighs, axillae, abdomen, and vulva ^{3,4}. There are a few reports of its widespread distribution as eruptive syringoma in the literature ⁵.

Case Report

A 29 year old healthy female presented with a one year history of eruption that had begun as a few papules around his umbilicus and spread to a larger area on her body over the next six months. The lesions were asymptomatic and, since their appearance, the patient's skin had never been completely clear. She was not on any medication. No family member had ever had a similar skin condition. Physical examination revealed multiple erythematous flat-topped papules 1 to 3 mm in diameter on the abdomen, lower part of her back and flanks. The lesions were bilateral and

symmetrical (Figures1,2). The remainder of the physical examination was unremarkable

A skin biopsy from the lesion of the abdomen showed a normal epidermis overlying a dermis that was filled with multiple ducts and small solid epithelial nests embedded in a fibrous stroma. The ducts were lined by an inner layer of flattened epithelial cells. Some ducts had a tadpole-like shape due to the appearance of a comma-like tail. The lumina of the ducts contained amorphous debris (Figure3). These histological features were consistent with the diagnosis syringoma.

We treated the patient with topical tretionin three times per week for six months but it seems to be ineffective and the lesion did not show any marked improvement.

Discussion

In eruptive syringoma, the lesions usually arise in large numbers in successive crops on the anterior trunk of young people. More rare cases with wider involvement of the body have also been reported. It occurs more frequently among women. There have been reports of unilateral, naevoid, bathing trunk and generalized distribution ⁵. In rare instances, occult syringomas are associated with hair loss ⁶ or cicatricial alopecia ⁷. Definitive diagnosis can be made on histological examination, because syringomas demonstrate distinctive

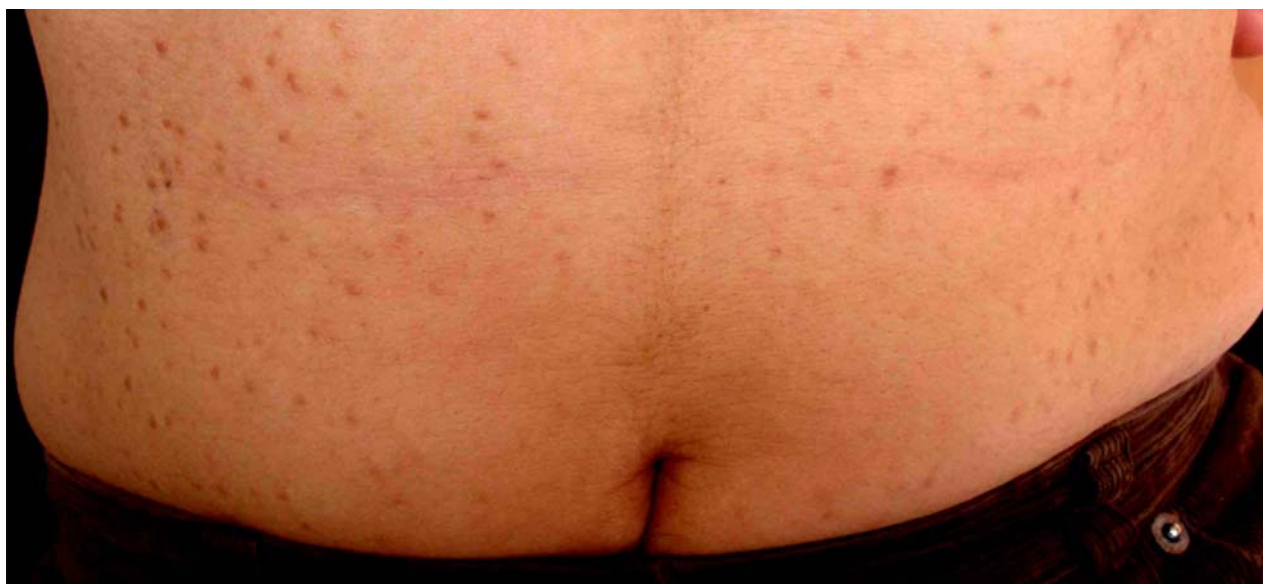

Figure 1. Bilateral and symmetrical erythematous papules on the lower abdomen.

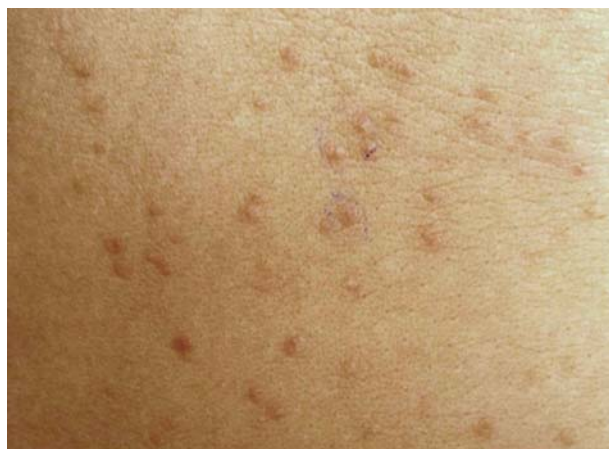

Figure 2. Syringoma: closer view of the abdominal lesions.

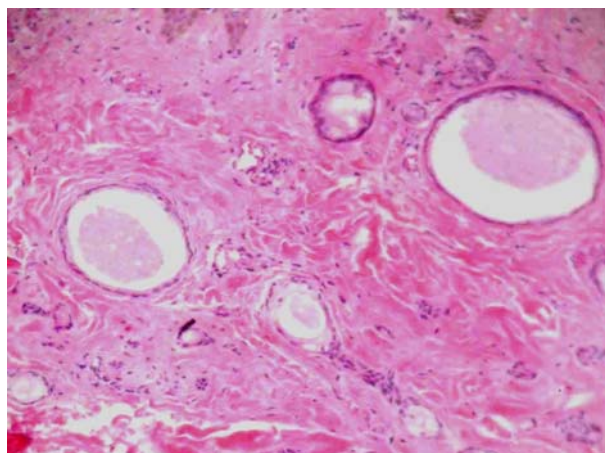


Figure 3. The dermis filled with multiple ducts and small solid epithelial nests embedded in a fibrous stroma. Some had a tadpole-like appearance. The lumina of the ducts contained amorphous debris. (H&E*40).

histopathological features. Embedded in a fibrous stroma are numerous small ducts, the walls of which are lined usually by two rows of epithelial cells. In most instances, these cells are flat. The lumina of the ducts contains amorphous debris. Some of the ducts possess small, comma-like tails of epithelial cells, giving them the appearance of tadpoles. In addition, there are solid strands of basophilic epithelial cells independent of ducts⁸.

There are many different treatment modalities such as dermabrasion, electrodesiccation with curettage, cryosurgery, chemical peeling and oral and topical retinoids or lasers with limited efficacy

⁹⁻¹¹. Since, these lesions are located in the dermis and often numerous, there is no standard treatment for widespread syringomas and the treatment may end in an insignificant efficacy, as in our patient.

Although, syringoma occur more frequently on the face in a localised manner, it would be better to keep it in mind in differential diagnosis of any eruptive papular lesions throughout the body. The histopathological assays could be very beneficial in this regard.

References

1. Patrizi A, Neri I, Marzaduri S, Varotti E, Passarini B. Syringoma: a review of twenty-nine cases. *Acta Derm Venereol* 1998; 78:460-2.
2. Goyal S, Martins CR. Multiple syringomas on the abdomen, thighs, and groin. *Cutis* 2000; 66:259-62.
3. Lo JS, Dijkstra JW, Bergfeld WF. Syringomas on the penis. *Int J Dermatol* 1990; 29:309-10.
4. Agrawal S, Kulshrestha R, Rijal A, Sidhu S. Localized vulvar syringoma causing vulval pruritus and venerophobia. *Australas J Dermatol* 2004; 45:236-7.
5. Soler-Carrilo J, Estrach T, Mascaro JM. Eruptive syringoma: 27 new cases and review of the literature. *J Eur Acad Dermatol Venereol* 2001; 15:242-6.
6. Helm TN, Guitart J, Bergfeld WF, Benedetto E. Occult syringoma associated with alopecia. *Int J Dermatol* 1992; 31:437-8.
7. Dupre A, Bonafe JL, Christol B. Syringomas as a causative factor for cicatricial alopecia. *Arch Dermatol* 1981;117:315.
8. Hashimoto K, DiBella RJ, Borsuk GM, Lever WF. Eruptive hidradenoma and syringoma. Histological, histochemical and electron microscopic studies. *Arch Dermatol* 1967; 96:500-19.
9. Karam P, Benedetto AD. Syringomas: new approach to an old technique. *Int J Dermatol* 1996;35:219-20.
10. Gómez MI, Pérez B, Azaña JM, Núñez M, Ledo A. Eruptive syringoma: treatment with topical tretinoin. *Dermatology* 1994;189:105-6.
11. Park HJ, Lee DY, Lee JH, Yang JM, et al. The treatment of syringomas by CO(2) laser using a multiple-drilling method. *Dermatol Surg* 2007; 33:310-3.