

# Sarcoidal Type Foreign Body Reaction: A Case Report

Mansour Nassiri Kashani, MD  
Parastoo Davari, MD  
Farzam Gorouhi, MD  
Alireza Firooz, MD

Center for Research and Training in Skin  
Diseases and Leprosy/Tehran University of  
Medical Sciences, Tehran, Iran

Corresponding Author:  
Mansour Nassiri Kashani, MD  
Center for Research and Training in Skin  
Diseases and Leprosy/Tehran University of  
Medical Sciences, Tehran, Iran  
Email: nassirikashani@yahoo.com

Received: April 14, 2010  
Accepted: June 1, 2010

## Abstract

Sarcoidosis and foreign body reactions are common differential diagnoses of skin granuloma formation. We report a 40 year –old man with sarcoid type granulomas containing polarized foreign materials, and also bilateral hilar adenopathy. It appears that detection of foreign bodies in histopathologic studies of granulomas does not necessarily exclude the possibility of sarcoidosis. (*Iran J Dermatol* 2010;13: 57-59)

**Key words:** foreign body, sarcoidosis, granulomatous

## Introduction

Sarcoidosis is a multisystem disorder histologically characterized by well demarcated non caseating epithelioid granulomas, occasional giant cell formation and no necrosis<sup>1</sup>. Foreign body granulomatous reaction is one of the differential diagnosis of sarcoidosis<sup>2</sup>, which may have an immunologic or non immunologic basis<sup>3</sup>.

We report a case with granulomatous reaction who demonstrated different features of both the aforementioned diseases.

## Case Report

A forty year-old Caucasian man presented with asymptomatic lesions on the left side of his face from two years ago. The lesions appeared to be enlarging gradually. Also, he had the history of shrapnel wounds in the same area fourteen years ago. The wounds, which were cleaned and debrided at the time of injury, healed with no complications shortly afterwards.

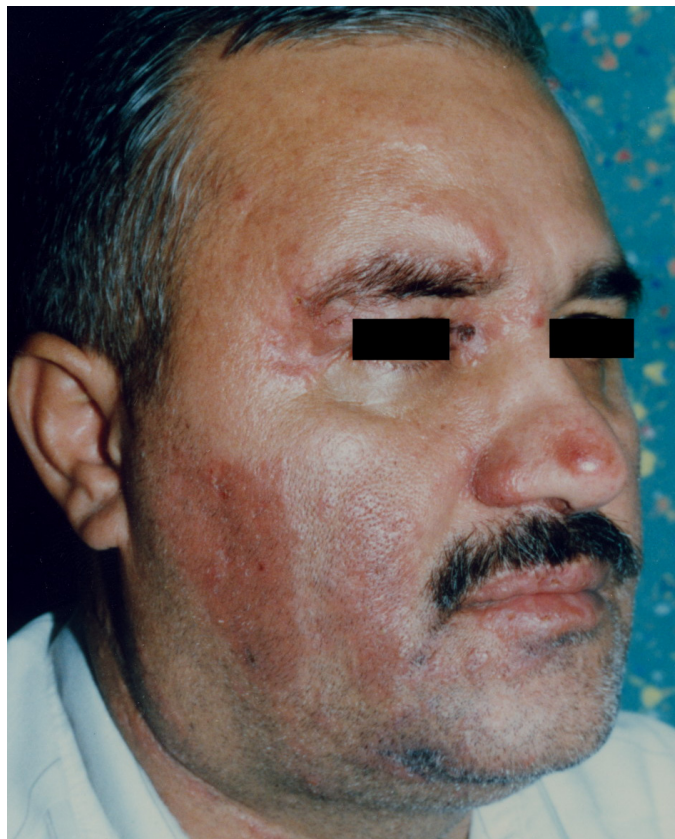Physical examination revealed flesh-colored to translucent papulonodules with a zosteriform pattern involving the left side of his lips, nose, and also left nasal and temporal canthus. (Figures 1)

Biopsies of the lesions showed well-circumscribed granulomas with epithelioid and giant cells surrounded by lymphocytes. (Figure 2)

Special staining for acid fast bacilli, culture for mycobacterium tuberculosis and atypical mycobacteria, PPD skin test and ANA were negative. Birefringent particles were detected on polarized light microscopy (Figure 3). Foreign bodies surrounded by epithelioid histiocytes were found after reviewing the specimens by conventional light microscopy as well.

Laboratory studies relevant to sarcoidosis (erythrocyte sedimentation rate, angiotensin converting enzyme, serum calcium and 24-hours urine calcium) were within normal limits. Chest X-ray and chest CT scan revealed bilateral hilar lymphadenopathy with no paranchymal involvement. So, the possibility of sarcoidosis was considered.

The lesions improved significantly after daily treatment with 30 mg prednisolone, but they recurred rapidly after tapering the dose of prednisolone. Intralesional injections of triamcinolone acetonide caused marked improvement of the lesions, though recurrence occurred again after a short while.



**Figure 1.** Translucent papulonodules with a zosteriform pattern involving the left side of nose, nasal and temporal canthus.

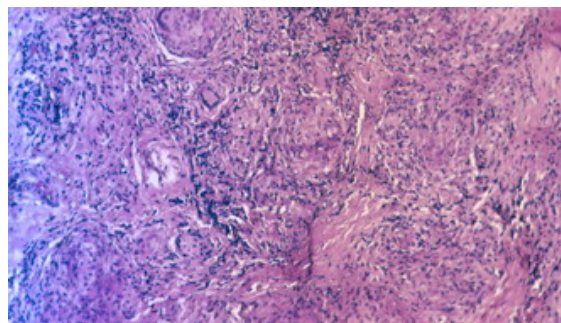
Unfortunately, the patient was lost to follow up for his skin and pulmonary involvement.

## Discussion

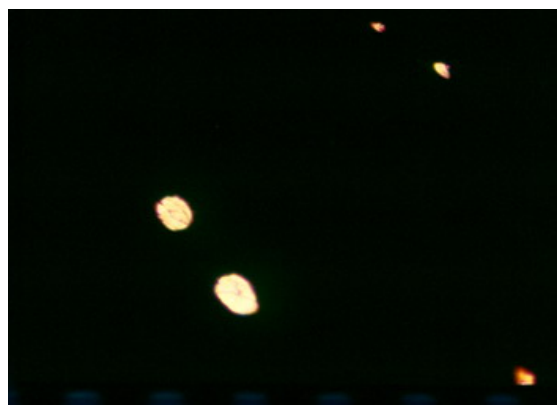
Sarcoidal granuloma formation is found in the presence of both sarcoidosis and foreign body reactions<sup>4</sup>.

Foreign bodies embedded in skin tissue lead to granuloma formation either under immunologic control or without immunologic modulation. Granulomatous reactions may mimic the histopathology of sarcoidosis and also commonly produce birefringent effects on polarized microscopy. In some instances, electron microscopy or spectrographic analysis are used to detect foreign bodies<sup>3</sup>.

Sarcoidosis is known as a multisystem disorder of unknown origin characterized by non-caseating granulomas<sup>5</sup>. Since bilateral hilar lymphadenopathy is the hallmark of the disease<sup>2</sup>, sarcoidosis was postulated to be responsible for the granuloma formation in our case. On the other hand, the detection of birefringent particles in



**Figure 2.** Well-circumscribed granulomas with epithelioid and giant cells surrounded by lymphocytes (H&E\*10)



**Figure 3.** Birefringent particles on polarized light microscopy.

polarized microscopy and normal laboratory tests weakened this possibility. However, the presence of polarizable foreign bodies in granulomatous skin lesions may not exclude the diagnosis of sarcoidosis. In fact, there have been several reports of sarcoidosis associated with foreign bodies within skin granulomatous lesions<sup>6-10</sup>. It has been suggested that foreign materials may play the role of a stimulus for granuloma formation in sarcoidosis<sup>6</sup>. It is worthy of note that in patients with foreign body reactions, diagnosis of sarcoidosis should not be ignored, considering the clinical and histopathological similarities between the two mentioned diseases.

Indeed, chemical analysis of the foreign bodies as well as further diagnostic studies for sarcoidosis such as gallium-67 scan, pulmonary function tests, bronchoalveolar lavage, and slit lamp eye examination, should have been done to make a more precise diagnosis in our case.

## References

1. English JC, Patel PJ, Greer KE. Sarcoidosis. *J Am Acad Dermatol* 2001;44:725-43.
2. Crystal RG. Sarcoidosis. In: Kasper DL, Braunwald E, Fauci AS, et al, editors. *Harrison's principles of internal medicine*. New York: McGraw-Hill;2005:2017-23.
3. Epstein WL, Fukuyama K. Mechanisms of granulomatous inflammation. *Immunol Ser* 1989;46:687-721.
4. Weedon D. *The skin pathology*, 3<sup>rd</sup> ed. Edinburgh: Churchill Livingstone;1992.
5. Newman LS, Rose CS, Maier LA. Sarcoidosis. *N Engl J Med* 1997; 336:1224-34.
6. Kim YC, Triffet MK, Gibson LE. Foreign Bodies in Sarcoidosis. *Am J Dermatopathol* 2000;22:408-12.
7. Walsh NM, Hanly JG, Tremaine R, Murray S. Cutaneous sarcoidosis and foreign bodies. *Am J Dermatopathol* 1993; 15:203-7.
8. Val-Bernal JF, Sanchez-Quevedo MC, Corral J, Campos A. Cutaneous sarcoidosis and foreign bodies. An electron probe roentgenographic microanalytic study. *Arch Pathol Lab Med* 1995;119:471-4.
9. Schewach-Millet M, Ziv R, Trau H, Zwas ST, Ronnen M, Rubinstein I. Sarcoidosis versus foreign-body granulomas. *Int J Dermatol* 1987; 26:582-5.
10. Marcoval J, Mana J, Moreno A, Gallego I, Fortuño Y, Peyrí J. Foreign bodies in granulomatous cutaneous lesions of patients with systemic sarcoidosis. *Arch Dermatol* 2001; 137: 427-30.