

# Localized genital bullous pemphigoid; A case report

Afshar Ramezanzpour, MD<sup>1</sup>  
Abdolamir Feizi, MD<sup>2</sup>

1. Department of Dermatology, Zanjan  
University of Medical Sciences,  
Zanjan, Iran

2. Department of Pathology, Zanjan  
University of Medical Sciences,  
Zanjan, Iran

Corresponding Author:  
Afshar Ramezanzpour, MD  
Dermatology Ward, Valiasr Hospital,  
Zanjan Medical University, Zanjan, Iran.  
E-mail: drramezanzpour@yahoo.com

Conflict of interest: None to declare

Received: March 4, 2011  
Accepted: April 23, 2011

Bullous pemphigoid (BP) is an autoimmune bullous disorder with urticarial pruritic papules and plaques and tense bullae in flexural surfaces of body. The localized form of the disease is a rare variant which can be triggered by different stimuli. Hereunder, we report a patient with the local type involving genitalia without any triggering factors.

**Keywords:** bullous pemphigoid, localized, genitalia

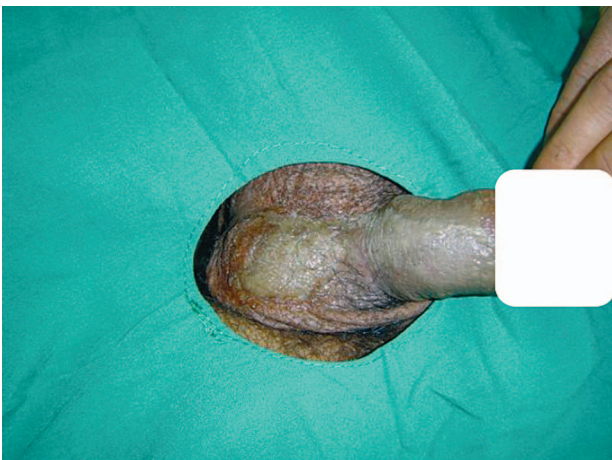
Iran J Dermatol 2011; 14: 71-72

## CASE REPORT

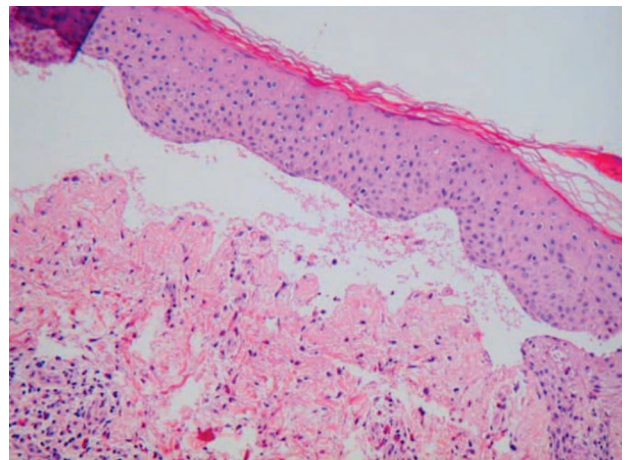
A 22-year-old married man was visited at Valiasr Hospital Clinic with a one-year history of erosive lesion on the ventral surface of his penis and scrotum (Figure 1). He had been treated by different antibiotics and topical therapy without any success.

Upon dermatologic examination, he was observed

to have an erosive macerated lesion on his genitalia (the ventral surface of the penis and scrotum) with no lesion or bulla in other parts of the body. His physical examination was otherwise normal. He had no drug history or trauma. In the result of his laboratory tests, potassium hydroxide smear, gram stain and culture, Tzank smear and VDRL, HCV Ab, HBS Ag and HIV serology were negative. Also, skin biopsy showed subepidermal blister (Figure 2)



**Figure 1.** The erosive lesion on the ventral surface of the penis and scrotum.



**Figure 2.** Subepidermal blister with cellular infiltration (H&E\*10).

and linear deposits of C3 and IgG were reported on direct immunofluorescence techniques (DIF). The diagnosis of bullous pemphigoid was made regarding the clinical and histopathological data. Our patient responded well to treatment with oral prednisone 50 mg/day for one month followed by gradual tapering of the dose. There was no recurrence of the disease at the time of this report.

## DISCUSSION

Some autoimmune bullous disorders such as pemphigus and linear IgA disease may be induced by trauma and PUVA therapy<sup>1,2</sup>. Localized BP is a rare variant of BP that may also occur after trauma<sup>3</sup>. Some scholars consider it as the result of different forms of epidermal damage (Koebner phenomenon) in predisposed patients; with the induction of antigen exposure in the context of subclinical pemphigoid followed by activation of the corresponding autoimmune process<sup>4</sup>, but our patient had no history of trauma. Also, the local form of the disease has been reported following thermal burn, radiation, PUVA therapy, surgical wound and also at injection and colostomy sites<sup>5-10</sup>. There are a few reports of localized genital BP in adults; in one of these reports, a 72-year-old woman had pruritic erythematous plaques and erosions in her perineum and perianal area<sup>11</sup>. This patient already had chronic itching due to chronic intertrigo or lichen sclerosis before suffering from BP, this factor was postulated as a trigger. In comparison, our patient was younger and had no triggering factor. In another report, a 67-year-old man had pruritic blisters on his penis and scrotum<sup>12</sup>, but our patient had no blisters. Similar to our case, a report was found in the literature in which the patient had erosive lesions on her genitalia<sup>13</sup>.

Although localized BP in vagina, perineum and perianal area have already been reported, sexual activity can also be considered as one of the triggering factors causing this type of the disorder.

The authors believe that sexual activity was most probably the cause in our patient as well. However, it is highly recommended that bullous disorders such as BP be considered in every patient with localized erosive dermatosis with no response to conventional therapy.

## REFERENCES

1. Ginarte M, Sánchez-Aguilar D, Pereiro-Ferreirós MM, Toribio J. Pemphigus vulgaris exhibiting koebner phenomenon. *J Eur Acad Dermatol Venereol* 1998;10: 90-2.
2. Salmhofer W, Soyer HP, Wolf D, Fodinger D, Hodl S, Kerl H. UV light induced Linear IgA dermatosis. *J Am Acad Dermatol* 2004;50:109-114.
3. Macfarlane AW, Verbov JL. Trauma induced bullous pemphigoid. *Clin Exp Dermatol* 1989; 14: 245-9.
4. Pardo J, Serna MR, Mercader P, Fortea JM. Localized bullous pemphigoid overlying a fistula for hemodialysis. *J Am Acad Dermatol* 2004; 51(2suppl): S131-2.
5. Vermeulen C, Janier M, Panse I, Daniel F. Localized bullous pemphigoid induced by thermal burn. *Ann Dermatol Venereol* 2000; 127: 720-2.
6. Leconte-Boulard C, Domp Martin A, Verneuli L, Thomine E, Joly P, Rogerie MJ, leory D. Localized bullous pemphigoid following radiotherapy. *Ann Dermatol Venereol* 2000; 127:70-2.
7. Perl S, Rappersberger K, Fodinger D, Anegg B, Honigsmann H, Ortel B. Bullous pemphigoid induced by PUVA therapy. *Dermatology* 1996; 193: 245-7.
8. Parslew R, Verbov JL. Bullous pemphigoid at sites of trauma. *Br J Dermatol* 1997; 137: 825-6.
9. Massa MC, Freeark RJ, Kang JS. Localized bullous pemphigoid occurring in a surgical wound. *Dermatol Nurs* 1996;8:101-2.
10. Vande M, Dominique M, Reilly JC. Bullous pemphigoid at colostomy site: report of a case. *Dis Colon Rectum* 1997;40:370-1.
11. Patsatsi A, Lazaridou E, Papagaryfallou I, Sotiriadis D. Bullous pemphigoid of the perineum and perianal area: A rare localized form in adults. *Acta Derm Venereol* 2008; 88: 401.
12. Lawrence A, Schiffman DO. Bullous pemphigoid of the penis. *AOCD J* 2010; 15: 10-2.
13. Haustien UF. Localized nonscarring bullous pemphigoid of the vagina. *Dermatologica* 1988; 176: 200-1.