

# Subcision for acne scarring with and without suctioning: A clinical trial

Kamran Balighi, MD  
Samaneh Jamshidi, MD  
Maryam Daneshpajoo, MD  
Vahideh Lajevardi, MD  
Sima Aalami Harandi, MD  
Hamed Ghassemi, MD

*Department of Dermatology, Razi  
Hospital-Tehran University of Medical  
Sciences, Tehran, Iran*

*Corresponding Author:  
Samaneh Jamshidi, MD  
Department of Dermatology, Razi  
Hospital-Tehran University of Medical  
Sciences, Tehran, Iran  
Email: samanehjamshidimd@yahoo.com*

*Conflict of interest: none to declare*

*Received: July 13, 2011  
Accepted: August 14, 2011*

**Background:** Treatment of acne scars is a therapeutic challenge that may require multiple modalities. Subcision is a procedure that has been reported to be beneficial in the treatment of acne scars. Although subcision is a valuable method, its efficacy is mild to moderate due to the high recurrence rate. This study aimed to evaluate the novel complementary treatment of repeated suction sessions plus subcision at the recurrence period of subcised scars.

**Methods:** The standard technique of subcision was applied to treat scars in 12 patients; then, one side of the face underwent repeated suctioning for 2 weeks. All patients completed treatment and the follow-up period. The patients' and investigators' assessments of improvement were both recorded.

**Results:** According to patients and investigators, subcision plus suction showed 81% and 65% improvement after 3 month, respectively. Subcision alone, after 3 month, was associated with 62% and 33.3% improvement according to patients and investigators, respectively. The rate of response showed a significant difference with the use of repeated suctioning. The side-effects of local edema and bruising were all transient.

**Conclusion:** Subcision plus frequent suctioning at the recurrence period of subcision appears to be a safe technique that increases the efficacy of subcision without considerable complications.

**Keywords:** acne scar, depressed scar, scar, subcision, subcision-suction method

Iran J Dermatol 2011; 14: 95-99

## INTRODUCTION

Acne is a common disease with a considerable prevalence worldwide. A complex problem that confronts a skin surgeon who attempts to manage acne is its permanent disfiguring scars. Disfiguring facial scarring is a common cause of patient dissatisfaction with treatment modalities of acne and a cause of distress to the patients<sup>1</sup>.

There are numerous surgical options to revise acne scars. Superficial modalities like light chemical peels and microdermabrasion (particulate resurfacing) have had limited success in improving deep acne scars although laser resurfacing (including non-

ablative dermal remodeling) modalities can make scars less perceptible by ablating the epidermis and part of the dermis and then permitting remodeling of the skin<sup>2-4</sup>. Filler substances have similarly been used with variable success rates to raise depressed scars<sup>5,6</sup>. Surgical methods including excision and punch grafting result in dramatically altered scar morphology in some patients<sup>7,8</sup>.

The term subcision (subcutaneous incisionless) surgery describes a unique form of incisionless local subcuticular undermining using a needle inserted under the depressed scar<sup>9</sup>. The process entails introducing a hypodermic needle just under the dermis to release fibrous attachments tethering

the epidermis and dermis to the subcutis. Motion of the needle parallel to the skin results in rasping as the underside of the dermis is released from its attachment to the subcutis<sup>10</sup>. The effectiveness of subcision for correcting scar depressions depends on two factors. First, the act of surgically releasing the skin from its attachment to deeper tissues results in skin elevation. Second, introduction of a controlled trauma initiates wound healing with consequent formation of connective tissue which augments the depressed site<sup>9</sup>. Subcision seems to be a favorable choice in this regard due to its simple method and low requirement for post-operative care.

Although subcision is safe, valuable and practical, depression recurrence is a very common side-effect and overall improvement is mild to moderate<sup>11</sup>. Because of common re-depression in our patients in the first 2–3 weeks after subcision, we hypothesized that repeated suctioning of the subcised scars at the recurrence period might prevent re-depression by induction of repeated hemorrhage in dermal pocket, delay in healing and more new connective tissue formation at the scar area<sup>12</sup>.

In this regard, we use repeated suctioning as a complementary treatment on the one side of subcised faces to assess whether it would enhance the efficacy of subcision due to the induced hemorrhage. The aim of our study was to assess the effectiveness of subcision plus suction in acne scars.

## PATIENTS AND METHODS

This study was an open-label clinical trial. All 12 patients suffered from mild to severe acne scars on their face with symmetrical distribution of lesions. Bleeding diathesis, susceptibility to keloid formation, age less than 18 years, breast feeding, pregnancy, active cystic acne, active infection on the face, isotretinoin therapy in the previous 12 months, inability to attend follow-up sessions and taking medications that prolonged bleeding such as aspirin and vitamin E all were regarded as exclusion criteria. All the patients signed informed consent forms after receiving verbal and written explanation regarding the study protocol. This study was approved by the ethics committee of our university and was performed according to the principles of the Declaration of Helsinki. Photographs of the affected anatomic

sites were taken before subcision and at the end of the treatment course with the same digital camera.

Subcision procedures were performed under the same conditions, in the same facilities and by the same surgeons, using identical techniques. Areas to be treated were determined after thorough assessment of each patient's scarring and consultation with the patient. Before every procedure, instructions were given to stop any medication that could lengthen bleeding (e.g. aspirin, vitamin E) if medically logical.

First, to anaesthetize the treatment area, topical anesthesia (EMLA cream) was used under occlusion 1–2 h preoperatively; then, the scarred area was marked with a fine-tip water-resistant surgical marking pen to place dots on the depressed scars and subcutaneous anesthesia (lidocaine 1% without epinephrine) was performed. The operative sites were then prepared using Povidon Iodine and draped in a sterile fashion.

Subcision was performed with the use of a 23-gauge needle in almost all patients. In a few small and superficial scars, we used 27-gauge needles (Insulin). Nokor Admix (Becton Dickinson Co) needles were used in a few very fibrotic scars.

The needle was inserted into the superficial dermis just 1–2 mm from each target region with the bevel upward and nearly parallel to the skin surface. Afterward, rapid repetitive advancement and retraction of the needle under the scarred area was performed to abrade the underside of the dermis and release scar sub-surfaces including the base, walls, borders and shoulders and 1 mm of the margin in superficial dermis. Then, fanning motion (side-to-side needle motion) was performed to completely cut fibrous tissue in one plane (superficial dermal undermining). Larger scarred areas were treated through two or three entry sites to achieve triangulation of the treatment zone and thorough soft tissue release. Care was taken to remain superficial to deep vessels and the proximal branches of the facial nerve. Dressing of the treated sites was done with a piece of gauze without pressure for 24 hours. Oral and topical antibiotics were also prescribed.

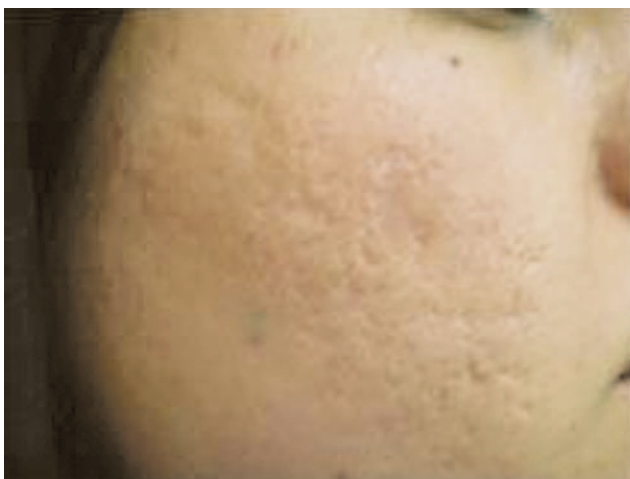Then, on one side of the patient's face, suctioning was performed every day for 2 weeks starting from the 3<sup>rd</sup> day after subcision using the handpiece of Clair Derm microdermabrasion device - Australia- (without crystal abrasion) with a 5 mm disposable

nozzle by a surgeon. The side of suctioning was randomly chosen. Suctioning was performed by both vertical and horizontal handpiece motions without causing trauma. In the beginning of suction period, elevated lesions were not suctioned until they became flat. On the first days, we used less negative pressure but in the subsequent sessions, depending on the condition of the scars, we could increase negative pressure (even to maximum: 70 mmHg), duration (not more than 4 seconds in each pass) and the number of suctioning passes (even 8–12 passes) per session. Effective suctioning caused edema and hemorrhage in the subcised scars and led to elevation of the depressed scars above the skin surface. At the same visit, suctioning maneuvers were applied on the other side of the face with the suction switched off and a recorded suction sound being played.

Outcomes of subcision procedures were assessed by investigators' and patients' ratings. After 3 months, 2 board certified dermatologists rated the degree of the improvement of the treated acne scars: no improvement: < 25%, mild improvement: 26% to 50%, moderate improvement: 51% to 75%, and marked improvement: > 75%. The patients were asked to complete a questionnaire assessing their satisfaction with subcision and unpleasant adverse effects. The data were finally analysed with SPSS-16 software.

## RESULTS

Twelve patients (3 male and 9 female) were enrolled in the study and treated with subcision.



All patients completed the study. The age of the participants ranged from 26 to 35 years (mean age: 30.3± 3.4). The mean number of scars was 17.2±5.47 and the etiology of scars was acne vulgaris in all of the patients. About 85.7% of the lesions were rolling acne scars and the remaining were ice pick and boxcar scars.

Investigators' ratings after 3 months indicated that, on average, improvement in the appearance of the subcision and subcision plus suction sides was 33.3 % and 65 %, respectively (Figure 1, 2).

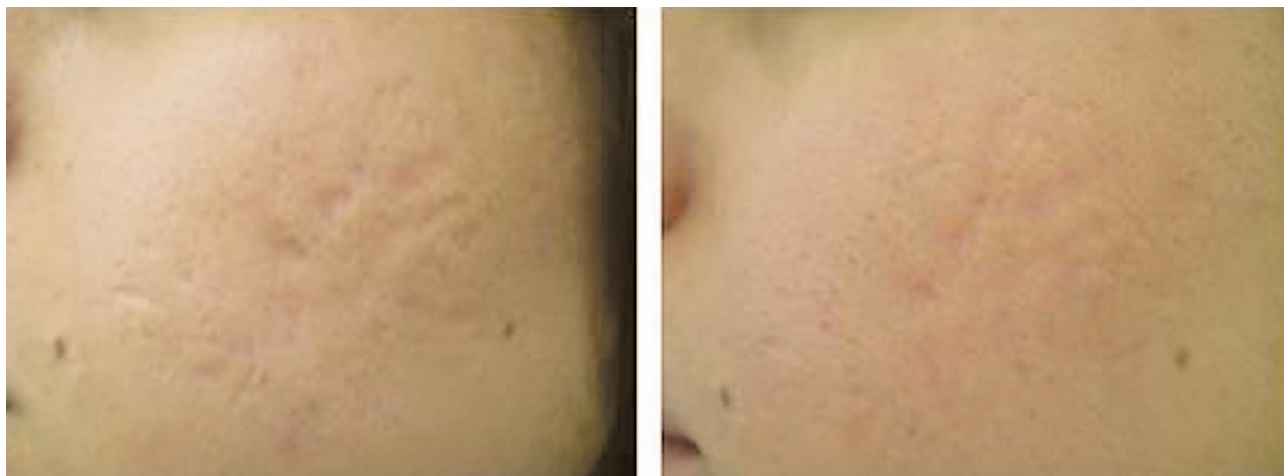
Patient questionnaires were administered, on average, 3 months post-procedure. The mean patients' ratings of improvement were 62% on the subcision side and 81 % on the subcision plus suction side.

Swelling was seen on the subcision side in 6 cases (50%), and on the subcision plus suction side in 10 cases (83%). Bruising was observed in all cases but was absorbed within 6-8 days on the subcision side and 14-17 days on the other side. Skin infection was not detected in any of the patients. Two cases of mild hyperpigmentation and one case of hypertrophic scar were documented. None of the patients showed any side-effects 3 months after intervention.

Investigators' ratings of improvement showed a significant difference between these two sides 3 months after the procedure ( $p=0.0003$ , Wilcoxon Test). The patients' assessment of efficacy also showed a significant difference with the use of suction 3 months after procedure ( $p=0.0002$ , Wilcoxon Test). The incidence of the adverse effects such as swelling, infection or bruising showed no

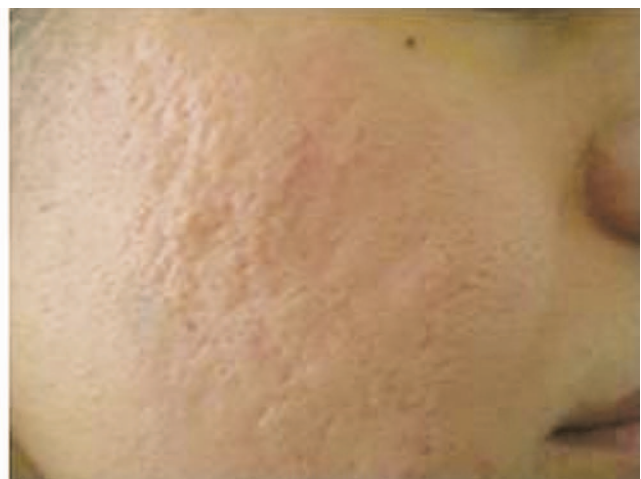

Figure 1. scar improvement after subcision



**Figure 2.** scar improvement after subcision and suction method

significant difference between the two sides ( $P=0.2$ , Wilcoxon test).

## DISCUSSION

Historically, many methods have been proposed for the treatment of acne scars with variable cosmetic results<sup>13-15</sup>. Subcision, first described by Orentreich, is a simple procedure for revision of many cutaneous deformities<sup>9,16-18</sup>. This is a simple, safe, easy to perform, well-tolerated and inexpensive technique by which any area on the face can be treated in minutes<sup>19</sup>. Treated scars can become significantly less noticeable. Improved but rather persistent scars can be subcised again or further smoothed by a resurfacing technique, such as laser resurfacing<sup>20</sup>.

Undermining of scars and cutaneous depressions appears to work by two mechanisms. First, breaking up the attachments of these contour abnormalities and releasing the tethers binding down the scar and second, reactive formation of new connective tissue after blood accumulation under the defect and its subsequent organization. This leads to long-term correction of the defect, although this is usually not complete following the first treatment<sup>18</sup>.

Few studies have assessed the efficacy and safety of subcision in the treatment of acne scars. Alam et al, assessed the efficacy of subcision in 40 patients with rolling acne scars and reported that both investigators and patients found that subcision improved rolling acne scars. They estimated improvement at just over 50% and side

effects were minimal to negligible<sup>10</sup>. Balighi et al, assessed the efficacy of subcision in the treatment of rolling acne scars in twenty patients and evaluated a novel subdermal filler 'absorbable plain catgut suture' with subcision. Both investigators and patients found that subcision improved rolling acne scars. The mean self assessment of patients' improvement was above 50%. The rate of response showed no significant difference with the use of subdermal implant<sup>19</sup>.

According to the experiences of our senior author with subcision, the recurrence of depression is a very common side-effect, particularly in the first 2-3 weeks after subcision, but we can prevent re-depression and enhance subcision outcome with repeated suctioning of the subcised scars when recurrence ensues<sup>12</sup>.

In the previous study, we concluded that frequent suctioning of subcised lesions with recurrence markedly increased the efficacy of subcision and caused significant and persistent improvement in short time, without considerable complications, in depressed scars of the face<sup>12</sup>. In continuation of the previous study, we compared subcision plus suction and subcision alone with applying these two modalities in reciprocal sides of the patients' faces. Both investigators and patients found that subcision plus suction resulted in greater improvement when compared to subcision alone. The rate of side-effects was not different between the two groups but bruising and swelling lasted longer with repeated suctioning.

In conclusion, subcision plus suction seems to

be a safe, effective surgical procedure for treating acne scars and is an easy to perform and useful tool for dermatologists who perform scar revision with a considerable rate of improvement and patient satisfaction. However, further controlled trials should be conducted to assess the efficacy and safety of this procedure.

## REFERENCES

- Rapp DA, Brenes GA, Feldman SR, Fleischer AB Jr, Graham GF, Dailey M, Rapp SR. Anger and acne: implications for quality of life, patient satisfaction and clinical care. *Br J Dermatol* 2004; 151: 183-9.
- Jordan R, Cummins C, Burls A. Laser resurfacing of the skin for the improvement of facial acne scarring: a systematic review of the evidence. *Br J Dermatol* 2000;142:413-23.
- Goldberg DJ. Full-face nonablative dermal remodeling with a 1320nm Nd:YAG laser. *Dermatol Surg* 2000;26:915-8.
- Ang P, Barlow RJ. Nonablative laser resurfacing: a systematic review of the literature. *Clin Exp Dermatol* 2002;27:630-5.
- Watson D, Keller GS, Lacombe V, Fodor PB, Rawnsley J, Lask GP. Autologous fibroblasts for treatment of facial rhytids and dermal depressions. A pilot study. *Arch Facial Plast Surg* 1999;1:165-70.
- Krauss MC. Recent advances in soft-tissue augmentation. *Semin Cutan Med Surg* 1999; 18:119-28.
- Johnson WC. Treatment of pitted scars: punch transplant technique. *J Dermatol Surg Oncol* 1986;12:260-5.
- Sotoloff SA. Treatment for pitted acne scarring: postauricular punch grafts followed by dermabrasion. *J Dermatol Surg Oncol* 1986;12: 1079-84.
- Orentreich DS, Orentreich N. Subcutaneous incisionless (subcision) surgery for the correction of depressed scars and wrinkles. *Dermatol Surg* 1995; 21: 54-9.
- Alam M, Omura N, Kaminer MS. Subcision for acne scarring: technique and outcomes in 40 patients. *Dermatol Surg* 2005; 31: 310-7.
- Vaishnani JB. Subcision in rolling acne scars with 24G needle. *Indian J Dermatol Venereol Leprol* 2008; 74: 677-9.
- Aalami Harandi S, Balighi K, Lajevardi V, Akbari E. Subcision-suction method: a new successful combination therapy in treatment of atrophic acne scars and other depressed scars. *J Eur Acad Dermatol Venereol* 2011;25:92-9.
- Jacob CI, Dover JS, Kaminer MS. Acne scarring: a classification system and review of treatment options. *J Am Acad Dermatol* 2001; 45: 109-117.
- Frith M, Harmon CB. Acne scarring: current treatment options. *Dermatol Nurs* 2006; 18: 139-42.
- Goodman G. Post acne scarring: a review. *J Cosmet Laser Ther* 2003; 5:77-95.
- Sommer B, Bergfeld D, Sattler G. LipoRepair. Approach to correction of fat tissue deformities. *Hautarzt* 2004; 55: 605-10.
- Karacalar A, Demir A, Yildiz L. Subcision surgery for the correction of ear deformities. *Aesthetic Plast Surg* 2004;28:239-44.
- Goodman GJ. Therapeutic undermining of scars (Subcision). *Australas J Dermatol* 2001; 42: 114-7.
- Balighi K, Robati RM, Moslehi H, Robati AM. Subcision in acne scar with and without subdermal implant: a clinical trial. *J Eur Acad Dermatol Venereol* 2008; 22: 707-11.
- Branson DF. Dermal undermining (scarification) of active rhytids and scars: enhancing the results of CO2 laser skin resurfacing. *Aesthet Surg J* 1998;18: 36-7.