

Harlequin ichthyosis: A case report from Iran

Simin S. Meymandi, MD ^{1,2}

Niloofer Mehrolhasani, MD ²

Marcie Ulmer, MD ³

Richard I. Crawford, MD ³

1. Pathology and Stem Cell Research Center, Afzalipour Medical School, Kerman University of Medical Sciences, Kerman, Iran

2. Department of Dermatology, Afzalipour Medical School, Kerman University of Medical Sciences, Kerman, Iran

3. Department of Dermatology and Skin Science, University of British Columbia, Vancouver, Canada

Corresponding Author:

Niloofer Mehrolhasani, MD

Department of Dermatology, Afzalipour Medical Complex, Imam Highway, Kerman, Iran

Email: mehrolhasaniniloofer@gmail.com

Conflicts of interest: None to declare

Received: 27 August 2016

Accepted: 6 October 2016

Harlequin ichthyosis is a rare and exceedingly severe form of congenital ichthyosis with an incidence of approximately 1 in 300,000 births. These patients are at a high risk for neonatal infection and septicemia. Most affected infants die within the first days or weeks of life.

We report a male baby born with harlequin ichthyosis. There is limited information regarding the course and prognosis of neonates affected with harlequin ichthyosis. However, it is now evident that these infants, depending on the severity, may have an extended survival potential with intensive supportive measures as well as the addition of retinoids.

Keywords: ichthyosis, harlequin ichthyosis, retinoid

Iran J Dermatol 2016; 19: 139-141

INTRODUCTION

Harlequin ichthyosis is the most severe type of congenital ichthyosis with an incidence of approximately 1 in 300,000 births. The disease is inherited as autosomal recessive with no racial or sexual predilection ¹. Prenatal diagnosis can be made by fetoscopy, fetal skin biopsy, or amniotic fluid sampling. Few cases of successful prenatal diagnosis at 20 weeks' gestation have been reported ². The affected neonates are often born prematurely, with resultant additional complications.

The clinical presentation includes markedly thickened, ridged, and cracked skin forming horny plates over the entire body disfiguring the facial features ³. Facial anomalies include bilateral ectropion (complete eversion of the eyelids with occlusion of the eyes), eclabium (eversion of the lips), absence of external ears, and nasal hypoplasia.

The nails and hair are underdeveloped ⁴.

The limbs are encased in thick hyperkeratosis resulting in flexion contracture of the arms, legs, and digits. The fingers and toes appear hypoplastic and ischemic ⁵. The unyielding shell may also restrict movement of the chest wall and may result in respiratory distress or failure. The abnormal fissuring and hyperkeratosis interfere with the normal and protective function of the skin. These patients are at a high risk for neonatal infection and septicemia, temperature dysregulation, dehydration, and electrolyte abnormalities. Electrolyte and metabolic abnormalities can cause seizures. Poor feeding and nutrition are commonly reported contributing to failure to thrive.

CASE REPORT

A male infant was born at 33 week gestational

age by normal vaginal delivery weighing 1,400 grams in Afzalipour Hospital, Kerman, Iran. His 22-year-old Iranian mother was gravida II para II. The parents were first cousins and their previous child had a similar presentation and died within the first week of life. The infant was covered with massive thick, waxy, plate-like scales and deep, moist, erythematous fissures. There was striking facial distortion including severe eclabium, ectropion, flattening of the nose, and underdevelopment of the ears. The limbs were in a semi-flexed position (Figure 1). The patient had

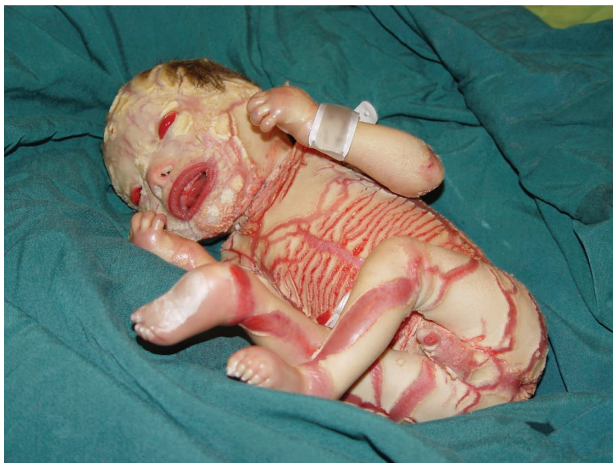

Figure 1. Thirty-three week-old premature neonate with harlequin ichthyosis. Large, thick, hyperkeratotic scales are separated by moist erythematous fissures. There is severe ectropion and eclabium with a fixed, open mouth. Pinnae are rudimentary. Limbs, hands, and feet are semi-flexed and affected by contractures.

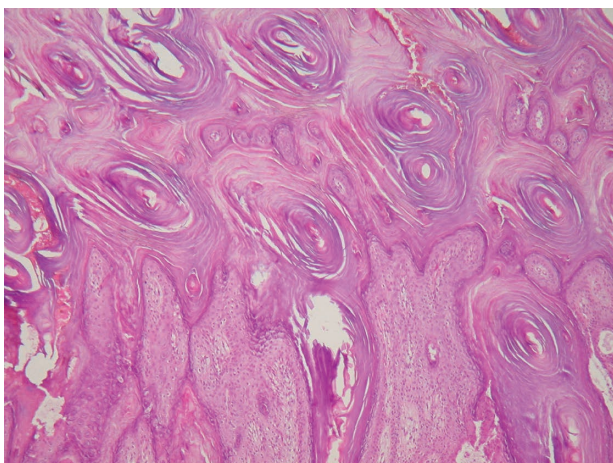


Figure 2. Marked orthokeratotic hyperkeratosis, mild hypergranulosis, and enlarged keratohyaline granules affecting the epidermis and the follicular infundibula. The deeper portions of the hair follicles, sebaceous glands and sweat ducts are unaffected. There is no reticular degeneration (H&E, 40×).

restricted respiratory movements and difficulty in feeding and was transferred to the Neonatal Intensive Care Unit where a decision was made to withhold active treatment. The infant expired at two days of age. Skin biopsy identified histologic features consistent with a clinical diagnosis of harlequin ichthyosis (Figure 2). Informed consent was obtained from the parents.

DISCUSSION

There is limited information regarding the course and life expectancy of neonates affected with harlequin ichthyosis as the majority of these patients do not survive the neonatal period. However, death may not be inevitable with intensive care measures with the addition of systemic retinoid⁶. Initially, intensive neonatal supportive care includes a humidified incubator, temperature regulation, fluid and electrolyte monitoring, infection control, skin and eye care, and nutrition replacement⁷. The first case of harlequin ichthyosis treatment with etretinate was reported in 1985¹. Isotretinoin and acitretin have been used more recently^{8,9}. The surviving children have been reported to have severe, generalized and lifelong ichthyosis with features resembling non bullous congenital ichthyosiform erythroderma¹. Effective therapy for this disease is supportive rather than curative. A continuing multidisciplinary approach and a lifelong meticulous daily skin care regimen are essential to maintain skin integrity and to prevent infection and hospitalization for these children.

Currently, it has been reported that mutations in the genes that cause this disease can be found by molecular methods. Families can receive genetic counseling about pregnancy planning, and gene-based therapies will be possible in the near future¹⁰.

REFERENCES

1. Lawlor F. Progress of a harlequin fetus to nonbullous ichthyosiform erythroderma. *Pediatrics*. 1988;82(6):870-3.
2. Roberts LJ. Long-term survival of a harlequin fetus. *J Am Acad Dermatol*. 1989;21(2 Pt 2):335-9.
3. Morelli JG. Disorders of keratinization. In: Behrman RE, Kliegman RM, Jenson HB, editors. *Nelson's textbook of pediatrics*. 17th Ed. Philadelphia, Saunders (WB) Co. Ltd.;2004:pp.2200-1.
4. Vijayaraghavan SB, Lalitha R, Ahmed AKJ. Congenital ichthyosis. *The Fetus.net* [Internet]. 2004; 11:09-14.

- Available from: <https://sonoworld.com/TheFetus/page.aspx?id=1448> [Last accessed: April 25, 2016]
5. Prendiville J. Harlequin Ichthyosis. Medscape [internet]. Last updated: 2016; Available from: <http://emedicine.medscape.com/article/1111503-overview>. [Last accessed: April 25, 2016]
 6. Ward PS, Jones RD. Successful treatment of a harlequin fetus. *Arch Dis Child*. 1989;64(9):1309-11.
 7. Thomas C. Harlequin ichthyosis. *Advance healthcare network for NPs & PAs* [internet]. 2000;11:32-48. Available from: <http://nurse-practitioners-and-physician-assistants.advanceweb.com/Article/Harlequin-Ichthyosis.aspx>. [Last accessed: April 25, 2016]
 8. Chang LM, Reyes M. A case of harlequin ichthyosis treated with isotretinoin. *Dermatol Online J*. 2014;18:20(2).
 9. Arjona-Aguilera C, Albarrán-Planelles C, Jiménez-Gallo D. Treatment of harlequin ichthyosis with acitretin. *Actas Dermo-Sifiliograficas*. 2015;106(9):759.
 10. Richard G, Choate K, Milstone L, Bale S. Management of ichthyosis and related conditions gene based diagnosis and emerging gene based therapy. *Dermatol Ther*. 2013;26(1):55-68.