Surgical excision in Bowen's disease

Iffat Hassan, MD
Peerzada Sajad, MD
Syed Mubashir, MD

Department of Dermatology, Sexually Transmitted Diseases & Leprosy, Government Medical College Srinagar, University of Kashmir, Jammu and Kashmir, India

Correspondence Author:
Iffat Hassan, MD
Department of Dermatology, Sexually Transmitted Diseases & Leprosy, Government Medical College Srinagar, University of Kashmir, Jammu and Kashmir, India
E-mail:hassaniffat@gmail.com.

Conflict of interest: none to declare

Received: 10 March 2014
Accepted: 30 July 2014

Background: Bowen's disease is a form of intraepidermal squamous cell carcinoma (SCC) characterised by a persistent, non-elevated, red, scaly or crusted plaque with a small potential for invasive malignancy. Most cases of typical Bowen's disease in the white population are found on the lower legs of the elderly women. However, in this part of the world, i.e. Kashmir, the most common site is thighs followed by the lower abdomen. A range of treatment options are available for it including cryotherapy, curettage and cautery, photodynamic therapy, laser destruction, surgical excision, 5-fluorouracil cream, imiquimod cream, and radiotherapy. The aim of this study was to evaluate the efficacy of surgical excision in Bowen's disease.

Method: All the patients with biopsy proven Bowen's disease were included for the study. A detailed history was taken for each patient including the history of medical treatment for Bowen's disease. Wide surgical excision (including either fusiform excision, W-plasty, or Z-plasty) was performed in each patient and the patients were then followed up for any recurrence. No sign of renewed disease activity at 6 months follow-up was taken as cure. All patients are intended to be followed up for 5 years.

Result: Ten out of 12 patients reported the use of topical imiquimod cream but complained of the progression of lesions. Surgical excision was performed in 12 patients. All the patients are currently under regular follow-up. Except for secondary infection and wound dehiscence in one patient, all the patients are in good condition with no signs of recurrence.

Conclusion: Although it was a preliminary study, we recommend surgical excision in treatment of Bowen's disease due to low recurrence rate.

Keywords: Bowen's disease, squamous cell carcinoma, surgery, treatment

Iran J Dermatol 2014; 17: 101-103

INTRODUCTION

Bowen's disease, also known as "squamous cell carcinoma in situ", is a neoplastic skin disease which can be considered as an early stage or intraepidermal form of squamous cell carcinoma. It was named after Mark Bowen [1]. Most cases of typical Bowen's disease in the white population are found on the lower legs of the elderly women. Bowen's disease typically presents as a gradually enlarging, well demarcated erythematous plaque with an irregular border and a crusting or scaling surface. Bowen's disease may occur at any age in adults but is rare before the age of 30 years; most patients are over 60 years of age. Any site may be affected although the involvement of palms or soles is uncommon. Bowen's disease occurs predominantly in women (70-85% of cases). About 60-85% of the

patients have lesions on the lower legs, usually in previously or presently sun exposed areas of the skin [2,3]. It presents as a persistent progressive non-elevated red scaly or crusted plaque which is due to an intraepidermal carcinoma and is potentially malignant. The lesions may occur anywhere on the skin or on mucosal surfaces. The proposed causes of Bowen's disease include solar damage, arsenic, immunosuppression (including AIDS), viral infection (human papillomavirus or HPV), and chronic skin injury [4,5]. A range of treatment options are available for it including cryotherapy, curettage and cautry, photodynamic therapy, laser destruction, surgical excision, 5-fluorouracil cream, imiquimod cream, and radiotherapy [6,7].

PATIENTS AND METHODS

This prospective hospital based study was conducted on patients attending the Department of Dermatology, STD & Leprosy, SMHS Hospital, an associated hospital of Government Medical College, Srinagar, India. All the patients with a clinical suspicion of Bowen's disease were included for the study. A detailed history was taken for each patient including the history of medical treatment for the presenting problem, and a physical examination including cutaneous and systemic examinations was done in each patient. Skin biopsy, either punch biopsy or edge biopsy depending on an individual case, was done in each patient, which was then sent for histopathological examination. After confirming a diagnosis of Bowen's disease, wide surgical excision (including either fusiform excision, W-plasty, or Z-plasty) was done in each patient (Figure 1-3). The size of the lesions varied from 1 to 3 cm in the longest diameter, and 0.5 to 1cm of the healthy margin was excised. Excision was performed up to the level of subcutis. After adequate undermining, the wounds were stitched using vicryl or silk sutures. A local dressing was applied and oral antibiotics were prescribed to all the patients for 7-10 days. The patients were followed at weekly intervals for one month and then monthly for any sign of recurrence. No sign of renewed disease activity at 6 months of follow-up was taken as cure. The patients have been currently under follow-up since last year and we intend to follow up these patients for 5 years post surgery.

Figure 1. Bowen's disease in a patient on the medial aspect of the right thigh.

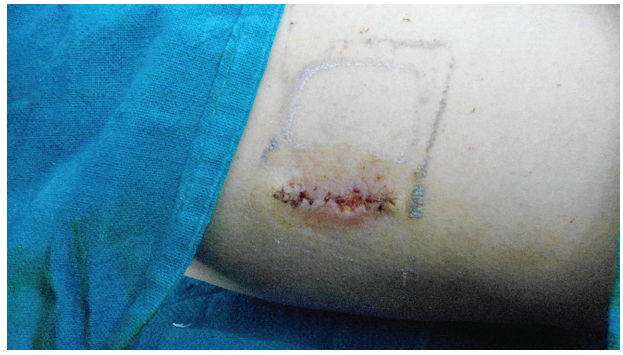

Figure 2. The same patient after the removal of sutures after 10 days.

Figure 3. The same patient after one and a half months.

RESULTS

This study included 12 patients, 7 females (58.33%) and 5 males (41.66%). The age range of the patients was 50-70 years. The duration of the disease ranged from 1-3 years. Ten out of 12 patients used topical imiquimod for more than three months but reported progression of the lesions associated with pain and pruritus. Surgical

excision was performed in all 12 patients considering aseptic precautions under local anaesthesia. The anteromedial aspect of the thigh was the most common site of affliction, followed by anterior abdomen and legs. Bowen's disease was noticed over the background of erythema ab igne in all the cases because of the common causative factor (i.e. Kangri use) and the most common presentation was an erythematous crusted scaly plaque. All the patients are currently under regular follow-up. Except for secondary infection and wound dehiscence in one patient, all the patients are in good condition with no signs of recurrence. No sign of renewed disease activity at 6 months of follow up was taken as cure. The patients have been under follow-up for the past one year and we intend to follow them for five years.

DISCUSSION

Bowen's disease typically presents as a gradually enlarging, well demarcated erythematous plaque with an irregular border and a crusting or scaling surface. It may occur at any age in adults but is rare before the age of 30 years - most patients are over 60 years of age. Any site may be affected although the involvement of palms or soles is uncommon. Bowen disease occurs predominantly in women (70-85% of cases) [1-3]. About 60-85% of the patients have lesions on the lower legs, usually in previously or presently sun exposed areas of skin. It presents as a persistent progressive non-elevated red scaly or crusted plaque which is due to an intraepidermal carcinoma and is potentially malignant. The lesions may occur anywhere on the skin or on mucosal surfaces [4,5]. There is a wide range of therapeutic options available for the treatment of Bowen's disease [5,6]. The preferred treatment option is based on a number of factors including the size of the lesion, site, previous treatment, and the number of lesions. Comparison of the relative effectiveness of different therapies and regimens is difficult as published studies do not fully control for factors such as size and site and there are inconsistencies between treatment regimens used at different centres. Surgical excision is a useful approach, particularly for small lesions in poor healing sites, perineal lesions, and digital lesions [8,9]. Various studies have demonstrated a nearly 100% cure rate for surgical excision. In a clinicopathological study of 47 cases of perianal Bowen's disease excision by Marchesa et al, surgical excision with a wide margin was found to offer a nearly 100% cure rate [10]. All therapeutic options have a failure rate of 5-10% except for surgical excision. Direct comparison is limited between different treatment modalities as there are few randomized controlled studies with comparable patient subgroups. The British Association of Dermatologists has prepared a guideline for the management of Bowen's disease which states that for individual patients, factors such as treatment related morbidity, and ease and availability of the treatment options may be a greater issue than the cure rate [4]. Our study also demonstrated very good results with surgical excision, especially with lesions on the thighs and abdomen. As it was a preliminary study, large controlled studies are required to establish the efficacy of this treatment modality in the treatment of Bowen's disease more definitely.

REFERENCES:

1. Bowen JT. Precancerous dermatosis. J Cutan Dis 1912;30:241-55.
2. Bowen JT. Precancerous dermatosis: the further course of two cases previously reported. Arch Dermatol 1920;1:23-4.
3. Graham JH, Helwig EB. Bowen's disease and its relationship to systemic cancer. AMA Arch Derm 1959; 80:133-59.
4. Cox NH, Eedy DJ, Mortan CA, et al. Guidelines for the management of Bowen's disease: 2006 update. Br J Dermatol 2007;156:11-21.
5. Mortan CA,Whitehurst C, Mosely H, et al. Comparison of photodynamic therapy with cryotherapy in the treatment of Bowen's disease. Br J Dermatol 1996;135:766-71.
6. Patel GK, Goodwin R, Chawla M. Imiquimod 5% cream monotherapy for squamous cell carcinoma in situ (bowen's disease): a randomised double-blind, placebo controlled trial. J Am Acad Dermatol 2006;54:1025-32.
7. Holt PJ. Cryotherapy for skin cancer: results over a 5-year period using liquid nitrogen spray cryosurgery. Br J Dermatol 1988;119:231-40.
8. Cox NH, Dyson P. Wound healing on the lower leg after radiotherapy or cryotherapy of Bowen's disease and other premalignant skin lesions. Br J Dermatol 1995;133:60-5.
9. Mortan CA,Whitehurst C, McColl JH, et al. Photodynamic therapy for large or multiple patches of Bowen's disease and basal cell carcinoma. Arch Dermatol 2001;137:319-24.
10. Marchesa P, Fazio VW, Short S, et al. Perianal Bowen's disease: a clinicopathological study of 47 patients. Dis Colon Rectum1997; 40:1280-93.