

# Coexistence of Disseminated Superficial Actinic Porokeratosis and Ptychotropica Porokeratosis

Maryam Akhiani, MD<sup>1</sup>  
 Vahideh Lajevardi, MD<sup>1</sup>  
 Fatemeh Moeineddin, MD<sup>1</sup>  
 Kambiz Kamyab, MD<sup>2</sup>

1. Department of Dermatology  
 2. Department of Pathology, School of Medicine, Tehran University of Medical sciences, Tehran, Iran

Corresponding author:  
 Vahideh Lajevardi, MD  
 Department of Dermatology, Razi Hospital, Vahdatab-Eslami square, 11996, Tehran, Iran  
 Email: vahide\_lajevardi@yahoo.com

Received: December 16, 2007  
 Accepted: March 17, 2008

## Abstract

Porokeratosis (PK) is an uncommon disorder of epidermal keratinization characterized by annular plaques with an atrophic center surrounded by a raised, keratotic wall, with unknown aetiology and an unpredictable outcome. It has several clinical forms including porokeratosis of Mibelli, giant porokeratosis, linear porokeratosis, disseminated superficial actinic porokeratosis, palmoplantar porokeratosis and punctate porokeratosis.

Genital porokeratosis is a rare and probably underestimated subset of PK that mostly affects middle-aged men. Although there are many clinical variants, coexistence of different variants of porokeratosis in a single patient has been regarded as a rare occurrence. Here we report a rare variant of porokeratosis, genital or ptychotropica porokeratosis, accompanied by superficial actinic porokeratosis in a patient and his family members. (*Iran J Dermatol* 2008;11: 126-128)

**Keywords:** porokeratosis, genitalia, actinic

## Case Report

A 32-year-old man referred with 8 year history of pruritic lesions on his natal cleft and scrotum. The lesions had started in the natal cleft and subsequently extended on to the right and left buttocks symmetrically. He received several topical medications with clinical impression of dermatophytosis and psoriasis, without any significant improvement. Apart from this problem, he complained of two annular lesions on his face. He was otherwise well, had no systemic illnesses, immunosuppressed status or specific drug history. In family history, his mother and sister disclosed similar annular facial lesions which were never dermatologically evaluated.

Physical examination revealed a sharply demarcated hyperkeratotic, erythematous to brownish plaque in the natal cleft and both buttocks of the patient (figure 1).

Close examination revealed multiple asymptomatic annular lesions with a raised margin and central atrophy on his forehead, nose and cheeks, 0.5 to 2 cm in diameter (figure 2).

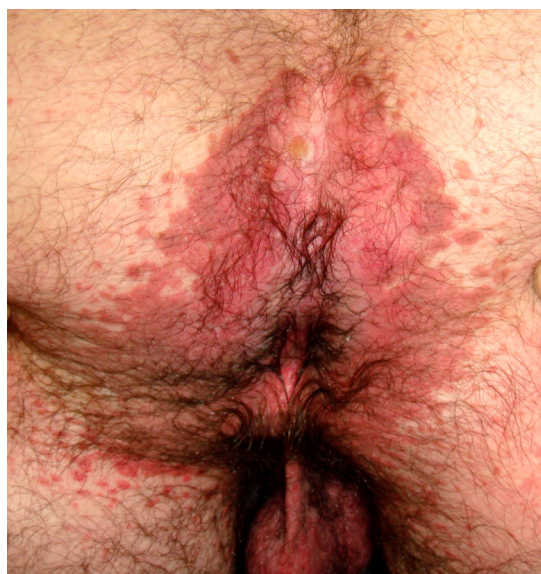Palms and soles, scalp, nails and mucous membranes were completely spared. Histopathologic examinations of elliptical biopsies

across the edge of lesions in the natal cleft showed a thickened column of keratin containing porokeratotic cells with an absent underlying granular layer characteristic of coronoid lamella (figure 3). No evidence of malignancy or dysplasia was noted. This histological feature was compatible with the diagnosis of porokeratosis. Histopathology of facial lesions of his mother demonstrated similar findings well-matched with the diagnosis of superficial actinic porokeratosis.

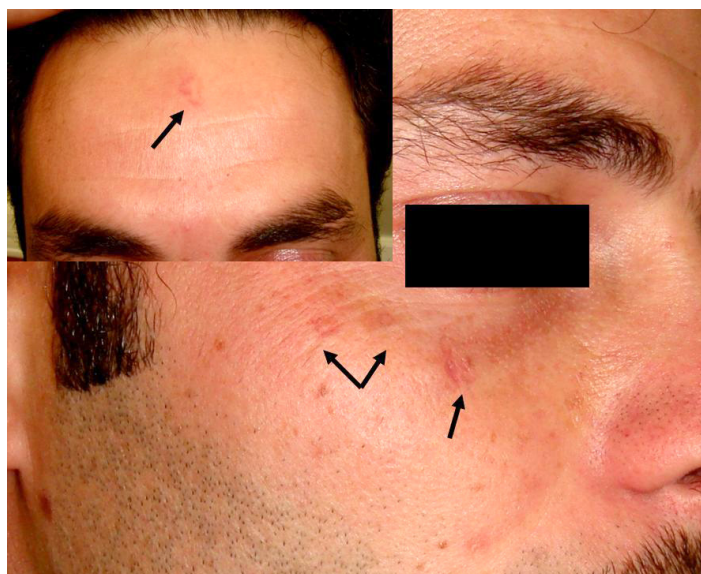The patient was treated with topical steroid and cryotherapy with the diagnosis of genital porokeratosis accompanied by familial disseminated superficial actinic prokeratosis. His complaints remained unchanged after 2 months until the prescription of imiquimod cream (Aldara) which led to partial improvement of his problems.

## Discussion

Porokeratosis (PK) is an uncommon disorder of epidermal keratinization, characterized by annular plaques with an atrophic center bordered with a raised keratotic wall. The aetiology of PK is remained unclear with an unpredictable outcome and susceptibility to develop malignant transformations<sup>1,2</sup>.



**Figure 1:** Hyperkeratotic plaque on natal cleft and buttock



**Figure 2:** Multiple lesions with raised border and central atrophy

Several clinical forms have been reported each with differing morphology, distribution and clinical course, including: porokeratosis of Mibelli, linear porokeratosis, punctate porokeratosis, disseminated superficial porokeratosis, porokeratosis palmaris plantaris et disseminate and disseminated superficial actinic porokeratosis<sup>1,2</sup>. These various clinical presentations may be due to the different phenotypic expression of a common genetic abnormality or may be the consequence of abnormalities in closely linked genetic loci or genes. Apart from these five variants, a number of morphological features, such as facial porokeratosis, giant porokeratosis, punched out porokeratosis, hypertrophic verrucous porokeratosis (HVP), reticulate porokeratosis<sup>3</sup> and porokeratosis ptychotropica<sup>4,5</sup> have been reported in the literature.

The term -porokeratosis ptychotropica- was introduced by Luckert et al to describe a chronic, bilateral; psoriasiform eruption extending onto the buttocks in a young male. Ptychotropica refers to the eruptions which have a predilection for the flexural skin<sup>4,5</sup>.

Considering genital PK as a distinct form of PK is premature to date; however, it discloses several characteristics: male gender preference, development of PK in the fifth decade, positive history of diabetes mellitus, long-lasting restriction of the lesions to the genital areas and the buttocks, pruritus and absence of malignant transformation. Our patient showed similar demographic and

clinical features as to the previous reports.<sup>6,7</sup>. Thomas et al<sup>8</sup> reported a case of hypertrophic perianal porokeratosis in association with superficial actinic porokeratosis of the leg, but with no positive family history as in our patient.

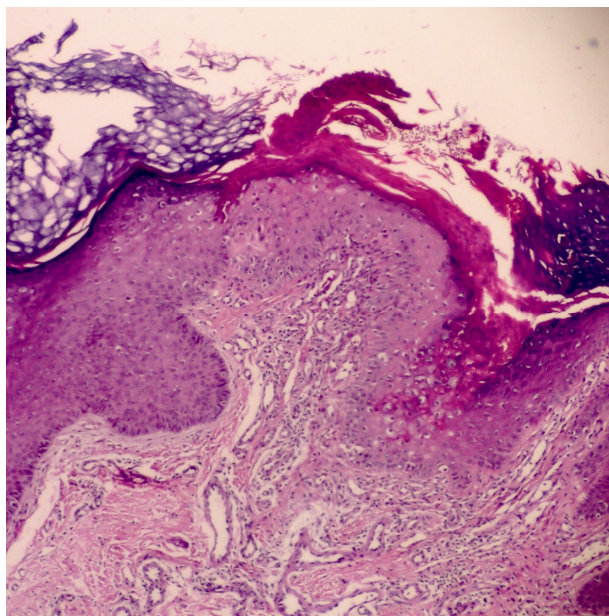
Simultaneous occurrence of disseminated superficial, linear and hypertrophic verrucous perianal forms of porokeratosis are also reported in a child<sup>9</sup>.

A genetic transmission, possibly autosomal dominant, is suggested due to occurrence of similar lesions in his mother and sister, although it has never been reported in genital PK to date except by Kluger et al<sup>10</sup>.

Diabetes is noted in 30% of all cases of genital PK according to a report by Chen et al<sup>6</sup>, but our patient did not display any clinical or laboratory findings of diabetes.

A recent review of malignant transformation in PK indicated that malignant changes were more frequently found on non exposed skin, large PK lesions, long-standing lesions, older patients, linear PK, large lesions on the extremities and in patients who had previously received radiotherapy<sup>11,12</sup>. Although this case did not show any evidence of malignancy even in the last visit; a long term follow-up period is needed for early detection of any malignant transformation.

Various topical treatments have been used in PK<sup>6,7</sup> including: topical and intralesional steroids, 5-fluorouracil, tretinoin<sup>13</sup>, 5% imiquimod cream and vitamin D3 analogs<sup>14</sup>. Systemic oral retinoid can be



**Figure 3:** Column of cornoid lamella (H & E staining, 40 X)

proposed if not contraindicated<sup>15</sup>. Physical treatments mainly include surgical excision, cryotherapy with liquid nitrogen, cryosurgery, CO<sub>2</sub> laser, electrocautery, and photodynamic therapy<sup>16</sup>.

Recently, 3% Diclofenac gel has been successfully used in a case of genital porokeratosis<sup>10</sup>.

Genital PK is probably underdiagnosed and should be considered in the differential diagnosis of patients presented with unusual hypertrophic erythematous and scaling perianal lesions. Due to the high rate of cellular proliferation in genital prokeratosis and the potential risk of malignant transformation, early diagnosis, treatment and long-term follow up are highly recommended in this type of PK.

## References

1. Cirgla HS, Bhattacharya SK. Clinical study of Porokeratosis: Reports of 10 cases. *Int J Dermatol* 1976;15:43-51.
2. Schamroth JM, Zlotogorski A, Gilead L. Porokeratosis of Mibelli. Overview and review of the literature. *Acta Derm Venereol* 1997;77:207-13.
3. Rao MV, Singh A, Thappa DM, Ratnakar C. Hyperkeratotic verrucous porokeratosis. *Indian J Dermatol* 1998;43:120-1.
4. Lucker GPH, Happle R, Steijlen PM. An unusual case of porokeratosis involving the natal cleft: porokeratosis ptychotropica? *Br J Dermatol* 1995; 132: 150-1.
5. Stone N, Ratnavel R, Wilkinson JD. Bilateral perianal inflammatory verrucous porokeratosis (porokeratosis ptychotropica). *Br J Dermatol* 1999;140: 553-5.
6. Chen TJ, Chou YC, Chen CH, et al. Genital porokeratosis: A series of 10 patients and review of the literature. *Br J Dermatol*. 2006;155:325-9.
7. Huang SL, Liu YH, Chen W. Genitogluteal porokeratosis. *J Eur Acad Dermatol Venereol* 2006;20:899-900.
8. Thomas C, Ogboli MI, Carr RA, et al. Hypertrophic perianal porokeratosis in association with superficial actinic porokeratosis of the leg. *Clin Exp Dermatol* 2003;28:676-7.
9. Mukhopadhyay AK. Simultaneous occurrence of disseminated superficial, linear and hypertrophic verrucous forms of porokeratosis in a child. *Indian J Dermatol, Venereol* 2004;70:364-5.
10. Kluger N, Dereure O, Guilhou J, et al. Genital porokeratosis: Treatment with diclofenac topical gel. *J Dermatolog Treat*. 2007; 18: 188-90.
11. Sasson M, Krain AD. Porokeratosis and cutaneous malignancy. A review. *Dermatol Surg* 1996; 22:339-42.
12. Otsuka F, Someya T, Ishibashi Y. Porokeratosis and malignant skin tumors. *J Cancer Res Clin Oncol* 1991; 117:55-60.
13. Agrawal SK, Gandhi V, Madan V, Bhattacharya SN. Topical tretinoin in Indian male with zosteriform porokeratosis. *Int J Dermatol* 2003;42:919-20.
14. Bohm M, Luger TA, Bonsmann G. Disseminated superficial actinic porokeratosis: Treatment with topical tacalcitol. *J Am Acad Dermatol* 1999;40:479-80.
15. Schamroth JM, Zlotogorski A, Gilead L. Porokeratosis of Mibelli. Overview and review of the literature. *Acta Derm Venereol* 1997;77:207-13.
16. Cavicchini S, Turlaki A. Successful treatment of disseminated superficial actinic porokeratosis with methyl aminolevulinate- photodynamic therapy. *J Dermatolog Treat* 2006;17:190-1.