

Erosive Pressure Dermatitis Associated with Cardiac Pacemaker

Hayedeh Ghaninejadi, MD
Soheil Fateh, MD
Roghie Shamsoddini, MD
Farshad Farshidfar, MD

Department of Dermatology, Razi Hospital, Tehran University of Medical Sciences, Tehran, Iran

Corresponding author:
Soheil Fateh MD
Department of Dermatology, Razi Hospital, Tehran University of Medical Sciences, Tehran, Iran
Email: sfateh@razi.tums.ac.ir

Received: June 14, 2009
Accepted: November 24, 2009

Abstract

Erosive dermatitis is a skin reaction associated with implantable cardiac devices (ie, pacemakers and cardioverter defibrillators). We report a 65-year-old man with a history of several cerebrovascular attacks who developed an erythematous crusted erosive patch over the pacemaker site after implantation of two subsequent pacemakers. We suggest that physical irritation may be a trigger factor for both pacemakers and changing the type of pacemaker is not important in some cases. (*Iran J Dermatol* 2009;12 (Suppl): S25-S26)

Keywords: pacemaker, erosion, pacemaker dermatitis

Introduction

Erosive dermatitis is a rare entity which has been reported to occur following the placement of implanted cardiac devices and drug delivery systems. We describe a patient that developed a crusted erosive nonpruritic patch on the chest after the placement of two subsequent pacemakers. The patient responded favorably to the removal of the first pacemaker but the condition repeated after the placement of the second pacemaker.

Case Report

A 65-year-old man, confined to a wheelchair, with a history of several cerebrovascular attacks was visited with the chief complaint of tenderness and redness on the overlying skin of his pacemaker site. A pacemaker was implanted for him 15 months ago. Three months later, he had a visit due to pain and redness over the device site. Physical examination revealed oozing, pus secretion and crust, warmth, tenderness and erosion due to pacemaker site infection. The hardware was removed and the patient showed significant improvement after treatment with systemic antibiotics. After complete resolution with systemic antibiotics, a titanium coated pacemaker was implanted contralaterally. After ten months, subacute inflammation over the site of the new titanium coated pacemaker urged the patient to

seek medical attention. On physical examination, erosion, erythema and crust were visible (Figure 1). With the initial diagnosis of contact dermatitis, a set of patch test with metal series was ordered and meanwhile, a zinc oxide ointment and zinc sulfate solution compress was prescribed for topical use as the initial treatment.

One week later, the patient returned for the patch test. The patch test result was negative. On examination, nearly all previous manifestations were resolved. No systemic or topical corticosteroid was prescribed for the patient and the resolution of the lesions only occurred with the use of the zinc oxide ointment.

Discussion

Cutaneous complications due to cardiac pacemaker implantation are frequently encountered. Some common postoperative problems include haematoma of the pocket, infections of the pocket or the leads, thrombosis, pectoral or diaphragmatic twitching, contact dermatitis to pacemaker constituents, and the 'painful' pocket. Differential diagnosis of cutaneous erythema and erosion around a pacemaker pocket includes allergic contact dermatitis and cellulitis¹. In our case, cellulitis can be the cause of the lesion in the first pacemaker because of the clinical course and resolution after antibiotic therapy. Déry et al.

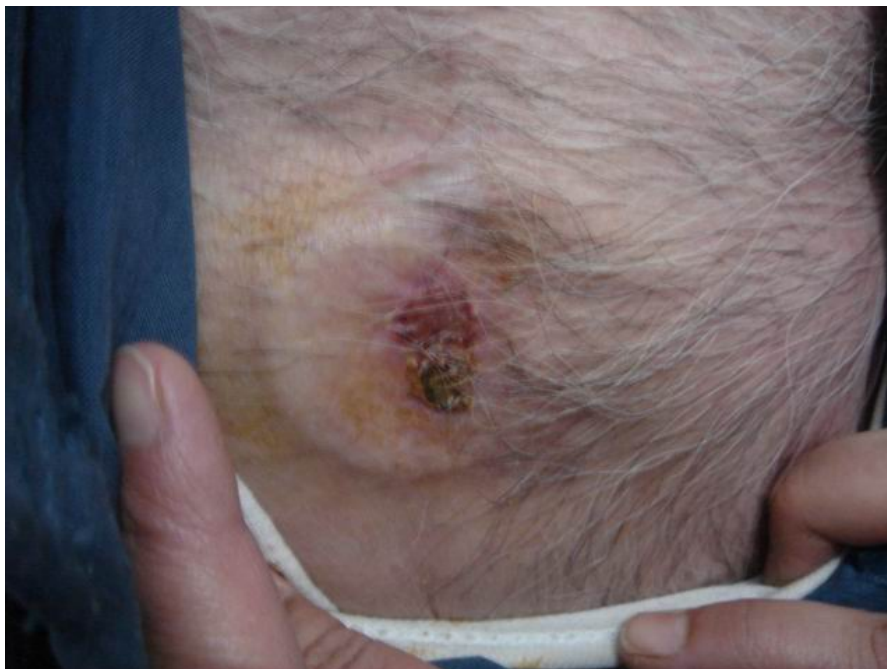


Figure 1. Crusted erosive pressure dermatitis over the pacemaker

reported a case that developed contact dermatitis after implantation of two subsequent pacemakers. The diagnosis was made with skin patch tests that were positive to polyurethane 75D and polysulfone beige, two components found in pacemakers and connectors², but in our case, allergic contact dermatitis was ruled out based on the negative patch test results and resolution without corticosteroid therapy. In addition, changing the pacemaker to a non-allergic titanium coated one did not prevent from the recurrence of the patient's symptoms. Wilkerson et al. reported a case with pressure dermatitis from an implanted pacemaker. He suggested that most of these reactions were isomorphic responses to the expansion of the subcutaneous tissues by the hard device and allergic contact dermatitis was documented in a few cases³. Physical irritation may be considered as a trigger factor. As in erythema abigne, heat followed by hyperemia may be the cause of erythema⁴. Krasagakis et al. suggested that physical forces such as heat and electric or magnetic fields may be the cause of pacemaker erythema and erosion⁵. Our patient mentioned that his condition recurred whenever his pacemaker site was stretched, for example when he did

forceful activities with his hands, and that his symptoms resolved only with the use of the zinc oxide ointment without using any corticosteroid.

We surmise that physical factors, such as mechanical irritation due to stretching or electromagnetic effects from the pacemaker, might play a role and changing the type of the pacemaker is not useful in some cases.

References

1. Lin YC, Chiu HC, Chu CY, Sun CC. Telangiectatic pacemaker erythema. *Clin Exp Dermatol* 2003 ;28:447-8.
2. Déry JP, Gilbert M, O'Hara G, Champagne J, et al. Pacemaker contact sensitivity: case report and review of the literature. *Pacing Clin Electrophysiol* 2002 ;25:863-5.
3. Wilkerson MG, Jordan WP Jr. Pressure dermatitis from an implanted pacemaker. *Dermatol Clin* 1990 ;8:189-92.
4. Sorhage B, Glowania H. Erythem nach Herzschrittmacher Implantation. *Z Hautkr* 1991;66:458-62.
5. Krasagakis K, Vogt R, Tebbe B, Goerd S. Persistent telangiectatic erythema associated with an automatic implantable cardioverter defibrillator. *Br J Dermatol* 1997;136:633.