# Multidrug resistant *Candida glabrata* in an oral lichen planus patient

Ensieh Lotfali, PhD [1*]
Alireza Firooz, MD [2]
Azam Fattahi, PhD [2]
Mojgan Borzouie, PhD [3]
Behzad Chalaki, [4]
Reza Ghasemi, [5]
Mohammad Mahdi Rabiei, [5]
Sareh Farhadi, DDS [6]
Seyed Amirfarshad Esteghamat, [4]
Mobina Habibollahi, [4]

1. *Department of Medical Parasitology and Mycology, School of Medicine, Shahid Beheshti University of Medical Sciences, Tehran, Iran*
2. *Center for Research and Training in Skin Diseases and Leprosy, Tehran University of Medical Sciences, Tehran, Iran*
3. *Medical Laboratory Department, Romgermed Hospital, Bucharest, Romania*
4. *Student Research Committee, Gifted and Talented Dental Students Division, School of Dentistry, Shahid Beheshti University of Medical Sciences, Tehran, Iran*
5. *Student Research Committee, School of Medicine, Shahid Beheshti University of Medical Sciences, Tehran, Iran*
6. *Assistant Professor, Oral & Maxillofacial Pathology Department, Faculty of Dentistry, Tehran Medical Sciences, Islamic Azad University, Tehran, Iran*

**Corresponding author:*
*Ensieh Lotfali, MD*
*Department of Medical Parasitology and Mycology, School of Medicine, Shahid Beheshti University of Medical Sciences, Tehran, Iran*
*Email: ensiehlotfali@sbmu.ac.ir, ensiehlotfali@yahoo.com*

*Received: 14 March 2020*
*Accepted: 22 April 2020*

Oral lichen planus (OLP) is a mucocutaneous disease characterized by inflammation leading to severe damage to the epithelial basal layer. This report describes a case of a 65-year-old Iranian female with a complaint of multifocal white lesions on the buccal and tongue mucosa with a reticular pattern and a focal pseudomembranous appearance (similar to thrush), together with burning symptoms for fourteen months. The patient was using topical fluocinolone acetonide 0.1%, two to three times a day at least for six months to control the ulcers and erythema. Molecular analysis of the thrush sample revealed *Candida glabrata* as the causative agent. Histopathologic examination confirmed the diagnosis of OLP. The minimum inhibitory concentration analysis was performed according to CLSI-M60 and revealed that this *C. glabrata* isolate was multidrug-resistant (resistant to nystatin, fluconazole, micafungin, and caspofungin). Finally, this patient was treated with amphotericin B oral suspension (0.5 g/5 ml) thrice daily for 14 days. The thrush disappeared completely and the patient no longer had any pain or burning sensations. *Candida glabrata*, the second most common cause of candidemia, is a major opportunistic fungal pathogen of humans that causes systemic as well as, mucosal and superficial infections. This case is the first case of OLP accompanied by multidrug-resistant *C. glabrata*.

**Keywords:** oral lichen planus; *Candida glabrata*; multidrug resistance

Iran J Dermatol 2020; 23: 120-124

DOI: 10.22034/ijd.2020.111551

## INTRODUCTION

Oral lichen planus (OLP) is a common disorder that predominantly involves stratified squamous epithelium. It is a global disorder, mostly seen in the fifth to sixth decades of life, and is twice as common in women [1]. In some OLP cases, a pseudomembranous appearance caused by *Candida* species can be seen on the white lesions of the oral mucosa [2]. In the present case, *C. glabrata* was isolated from a woman suffering from OLP. Susceptibility testing of *C. glabrata* showed that this microorganism was resistant to many antifungal drugs. To the best of our knowledge, this is the first report of OLP accompanied with multidrug-resistant *C. glabrata*.

## CASE REPORT

A 65-year-old female referred to the Oral & Maxillofacial Pathology Department, Faculty of Dentistry, Tehran Medical Sciences Islamic Azad University (Tehran, Iran) with a complaint of multifocal white lesions on the buccal and tongue mucosa and burning symptoms for fourteen months. The physical examination revealed a white reticular pattern and a focal pseudomembranous appearance similar to thrush (Figure 1). Also, she had full implant-supported fixed prostheses without a history of any systemic diseases.

She had received medications such as nystatin drops (50,000 units) and fluocinolone acetonide 0.1% solution (as a topical steroid two to three times a day) without remarkable improvements. An incisional biopsy was performed and the histopathologic examination with hematoxylin-eosin (H&E) staining revealed oral mucosa with keratinized stratified squamous epithelium along with focal basal cell degeneration and band-like infiltration of lymphocytes beneath the connective tissue subjacent to the epithelium, compatible with the diagnosis of OLP (Figure 2).

The causative agent was identified with molecular testing of the thrush sample. Fresh colonies were isolated from overnight cultures and DNA was extracted using a method described in the literature [3]. Internal transcribed spacer (ITS) regions of the rDNA gene of the isolate were amplified by universal fungal primers, ITS1 (5′-TCCGTAGGTGAACCTGCGG-3′) and ITS4 (5′- CCTCCGCTTATTGATATGC-3′) [4]. The PCR product was subjected to sequencing for precise identification of the isolate using the BigDye™ Terminator Cycle Sequencing Kit supplied by Bioneer (Korea). The specific pattern of *Candida* spp. using the amplification of the ITS region after sequencing was *C. glabrata.* The minimum inhibitory concentrations of four antifungals including nystatin, fluconazole, micafungin, and caspofungin (Sigma-Aldrich, St. Louis, MO, USA) were determined according to the CLSI M60 standard procedure, which revealed that this strain was multidrug-resistant; resistance to all antifungals was observed according to the CLSI guideline (micafungin ≥ 0.25; caspofungin ≥ 0.5; fluconazole ≥ 64; and nystatin ≥ 8) [5]. The patient was treated with the oral suspension of amphotericin B (0.5 g/5 ml) thrice daily for 14 days. Subsequently, the patient no longer had any symptoms and the thrush disappeared completely.

## DISCUSSION

The present study elucidated an unusual case of *C. glabrata* carriage in the oral cavity of an OLP patient who had undergone topical steroid therapy; the *C. glabrata* strain was resistant to nystatin, fluconazole, micafungin, and caspofungin. Lichen planus is a T cell-mediated autoimmune disease affecting the stratified squamous epithelium and giving rise to chronic inflammation. Although

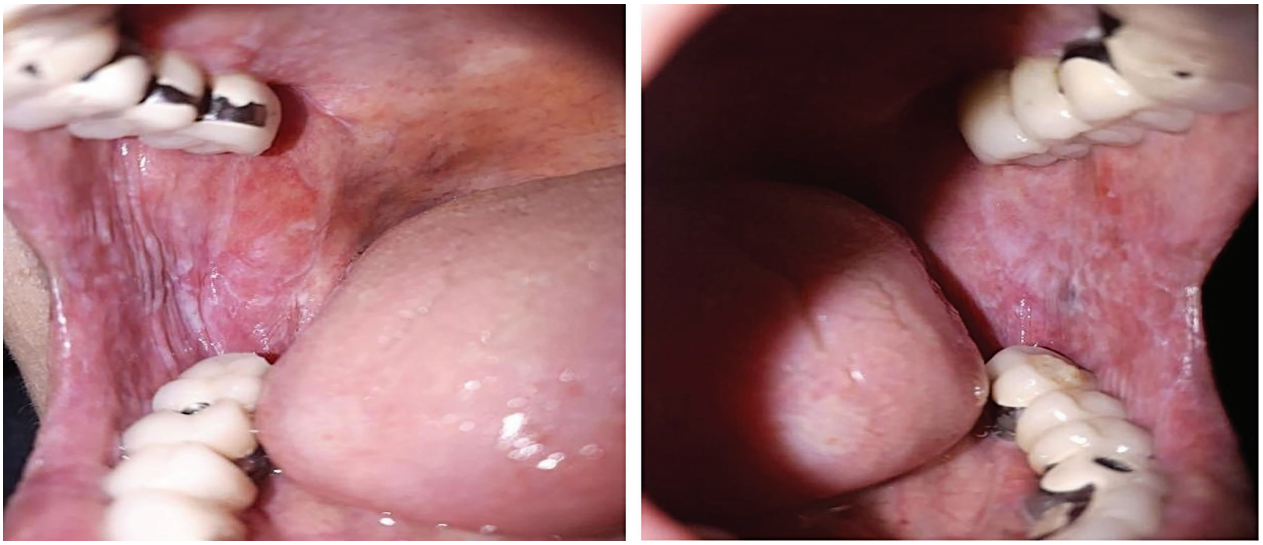

**Figure 1.** Reticular lesions affecting the buccal mucosa

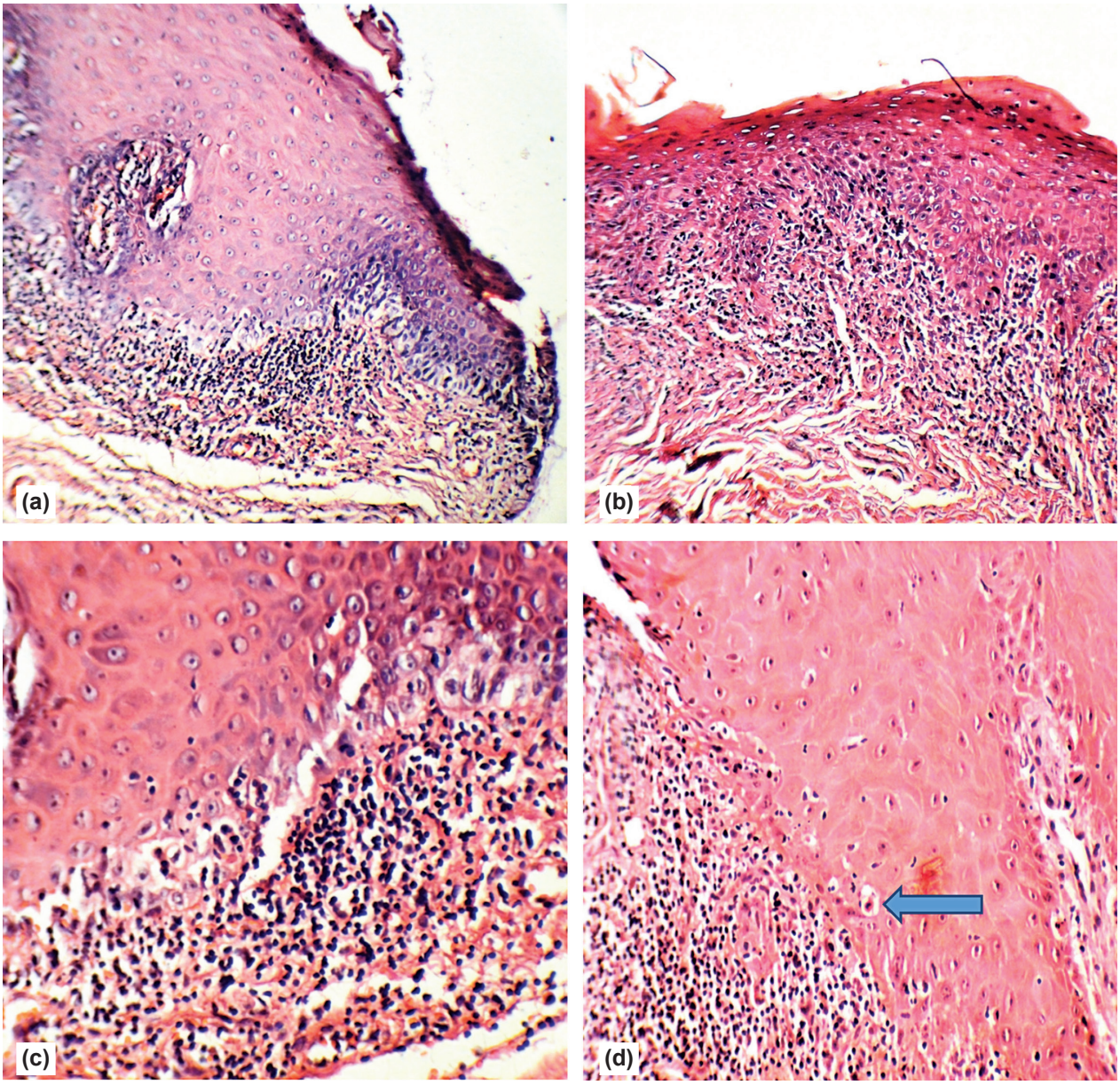


**Figure 2.** a) Band-like infiltration of the connective tissue subjacent to the epithelium (H&E×40). b) Basal cell hydropic degeneration (H&E×100). c) Basal cell hydropic degeneration and band-like lymphocyte infiltration (H&E×100). d) Basal cell hydropic degeneration and a Civatte body marked by the arrow (H&E×400)

OLP can be diagnosed by its clinical features, a biopsy is necessary to confirm the diagnosis and exclude dysplasia or malignancy. The diagnosis was confirmed after ruling out leukoplakia, which presents as whitish plaques in the oral mucosa. Plaque OLP features white patches and networks, with secondary ulceration [1]. Leukoplakia, however, is described as a white patch or plaque that cannot be removed by rubbing, differentiating it from thrush [1,2]. In some cases, during histopathologic examinations, invasive yeast elements of *Candida* spp. can be seen infiltrating the epithelial cell layers. Some species such as *C. albicans*, *C. glabrata*, and *C. tropicalis* are more commonly found on lichen planus lesions [2]. To the best of our knowledge, this case is the first case of OLP accompanied by multidrug-resistant (MDR) *C. glabrata*. Until a few years ago, the use of the term 'MDR *Candida* spp.' was limited to a few case reports. Lately, the extensive use of antifungal agents for prophylaxis and therapy has

changed this condition. Nowadays, we encounter a rising number of invasive infections caused by MDR non-*albicans Candida* strains. Accordingly, *C. glabrata* strains are the most important subjects among these agents [6].

In the early 2000s, physicians observed the reduced susceptibility to fluconazole among *C. glabrata* strains. Therefore, echinocandins became the first-line treatment against this pathogen. A few years later, echinocandin resistance was reported among fluconazole-resistant *C. glabrata* isolates [6]. Notably, *C. glabrata* tends toward multi-azole non-susceptibility; the rate of echinocandin resistance is also increasing, at least in the USA [7]. In the current case, OLP was accompanied by *C. glabrata* resistance to nystatin, fluconazole, micafungin, and caspofungin. In a study performed by Arora *et al.*, all *C. glabrata* species isolated from the OLP patients were resistant to fluconazole [8]. Azole resistance in *C. glabrata* may be related to drug efflux via the upregulation of transporters. The upregulation of these transporters is driven by gain-of-function mutations in their major regulator. Also, another suggested mechanism of resistance is the emergence of a small colony or 'petite' mutant phenotype with decreased respiratory capacity secondary to the selective pressure of azole therapy [6].

The less toxic lipid formulations of amphotericin B are the most suitable treatment option for MDR *C. glabrata* [6]. This finding is consistent with the reports of Arora *et al.*, in which all *Candida spp*. isolated from OLP patients were susceptible to amphotericin B [8].

Amphotericin B binds to ergosterol in the cell membrane and can lead to cell death secondary to pore formation. Ergosterol is formed from a precursor called lanosterol. This biosynthesis involves a number of enzymes encoded by several genes. Accordingly, mutations in some of these genes have been associated with amphotericin B resistance in *Candida* spp. [9].

In this patient, nystatin showed no remarkable effects. In a similar study, a susceptibility test of *C. albicans* isolated from OLP patients was conducted. Among the species isolated, resistance to fluconazole and itraconazole was observed. None of the strains of genotypes B and C of *C. albicans* presented drug resistance to nystatin [10].

There are several topical and systemic medications for OLP. Topical medications not only are effective but also have fewer side effects.

Tretinoin and isotretinoin (as topical retinoids) have been used to treat OLP, mainly in the treatment of atrophic-erosive forms, though topical corticosteroids are more effective than retinoids. Systemic corticosteroids are used in specific situations such as the failure of topical approaches and the presence of recalcitrant, erosive OLP or the involvement of skin, genitals, esophagus, and scalp in generalized OLP. Cryosurgery is a good option for erosive, drug-resistant OLP, but lesions may develop in the recovering wounds [1].

Today, the standard suggested treatment for OLP is topical corticosteroids [11]. This patient had used fluocinolone acetonide 0.1% solution as a topical steroid two to three times per day for at least six months to control the ulcers and erythema. Ultimately, the candida superinfection in this patient was treated with amphotericin B, resulting in both objective and subjective relief.

## CONCLUSION

To sum up, in a patient with OLP, *C. glabrata* was identified and found to be resistant to fluconazole, nystatin, micafungin, and caspofungin. This study can help physicians in the management of similar cases. Also, this case is the first to report the detection of OLP superinfected with an MDR strain of *C. glabrata*.

**Conflict of interest:** None declared.

## REFERENCES

1. Scully C, Carrozzo M. Oral mucosal disease: Lichen planus. Br J Oral Maxillofac Surg. 2008;46(1):15-21.
2. Lundstrom IM, Anneroth GB, Holmberg K. Candida in patients with oral lichen planus. Int J Oral Surg. 1984;13(3):226-38.
3. Ghajari A, Lotfali E, Ahmadi NA, et al. Isolation of different species of candida in patients with vulvovaginal candidiasis from Damavand, Iran. Arch Clin Infect Dis. 2018 (In Press).
4. Garcia-Cuesta C, Sarrion-Pérez M-G, Bagán JV. Current treatment of oral candidiasis: A literature review. J Clin Exp Dent. 2014;6(5):e576.
5. Wayne P. Reference method for broth dilution antifungal susceptibility testing of yeasts, approved standard. CLSI document M27-A2. 2002.
6. Colombo AL, Júnior JN, Guinea J. Emerging multidrug-

resistant Candida species. Curr Opin Infect Dis. 2017;30(6):528-38.

7. Farmakiotis D, Kontoyiannis DP. Epidemiology of antifungal resistance in human pathogenic yeasts: current viewpoint and practical recommendations for management. Int J Antimicrob Agents. 2017;50(3):318-24.
8. Arora S, Verma M, Gupta S, et al. Phenotypic variability and therapeutic implications of Candida species in patients with oral lichen planus. Biotech Histochem. 2016;91(4):237-41.
9. Arendrup MC, Patterson TF. Multidrug-resistant Candida: epidemiology, molecular mechanisms, and treatment. J Infect Dis. 2017;216(suppl_3):S445-S51.
10. Li J, Sun H, Zhang Q. Antifungal susceptibility test of genotypes of *Candida albicans* from patients with atrophic or erosive oral lichen planus. Shanghai Kou Qiang Yi Xue. 2011;20(3):300-3.
11. Piroozmand P, Mousavi M, Akbari K. What are the non-steroidal treatments of oral lichen planus? J Res Dent Sci. 2017;14(2):128-135.

 