Clinical and dermoscopic study of periorbital hyperpigmentation (POH) and quality of life in POH patients based on the MELASQOL scale: a case-control study

Anu George T, MBBS
Vinutha Rangappa, MD*
Jayadev Betkerur, MD

Department of Dermatology, JSS Medical College and Hospital, JSS Academy of Higher Education and Research, Mysore, Karnataka, India

**Corresponding author:*
Vinutha Rangappa, MD
Department of Dermatology, JSS Medical College and Hospital, JSS Academy of Higher Education and Research, Mysore, Karnataka, India
Email: drvinutharangappa@gmail.com

Received: 22 April 2020
Accepted: 10 July 2020

Background: Periorbital hyperpigmentation (POH), a common problem of multifactorial etiology, is obvious on the face and can affect patients' quality of life (QoL). It is essentially a clinical diagnosis, but dermoscopy might aid in further classification of the disease. Also, it might give us a clue regarding the etiology and help in the treatment, as different types of POH respond to varying treatments. We aimed to assess clinical, dermoscopic patterns and quality of life using the Melasma Quality of Life (MELASQOL) scale in POH and to compare it with controls.

Methods: Detailed histories were obtained from 100 patients with POH. The clinical and dermoscopic examination was done, and the obtained results were compared against 100 controls. The MELASQOL scale was used to assess QoL.

Results: Family history ($P = 0.013$), lack of sleep ($P = 0.003$), stress ($P = 0.001$), and eye rubbing ($P = 0.01$) were the probable risk factors. Blotchy pattern ($P < 0.0001$), speckled pattern ($P < 0.0001$), and telangiectasia ($P = 0.007$) were the significant dermoscopic findings. Controls showed pseudoreticular ($P < 0.001$) and superficial dilated veins ($P < 0.0001$). Quality of life was affected in 30.6% of patients; it was more affected in grade 4 POH.

Conclusion: Dermoscopy will aid in the classification of POH. Blotchy pattern, speckled pattern, and telangiectasia are the typical dermoscopic patterns, more so in higher grades. QoL may be affected in POH. However, MELASQOL is not adequate to assess QoL in POH.

Keywords: periorbital hyperpigmentation, dermoscopy, quality of life, MELASQOL

Iran J Dermatol 2021; 24: 172-178

DOI: 10.22034/ijd.2021.136456

INTRODUCTION

Periorbital hyperpigmentation (POH) is a common problem presenting as bilateral homogenous brown to black pigmentation, primarily involving the lower eyelids but sometimes extending to the upper eyelids, eyebrows, temporal regions, malar regions, and lateral nasal root [1,2]. It is common in females with an early adulthood onset and has multifactorial etiology [3]. Being a cosmetically visible dermatological condition, POH is psychologically distressing and can affect the quality of life (QoL) of an individual.

Dermoscopy is a non-invasive technique that helps in the diagnosis by visualizing subtle clinical patterns of skin lesions and subsurface

skin structures that are not visible to the naked eye [4]. Essentially, POH is a clinical diagnosis, and dermoscopy can be used as an additional tool for classifying the different patterns of POH.

Though various dermoscopic patterns have been described, there seems to be no consensus among the authors. Dermoscopic evaluation of POH is essential, particularly in the determination of the degree and pattern of pigmentation. This can aid in the treatment, as different types of POH respond to varying types of treatment [1]. By combining clinical findings and dermoscopic patterns, clues regarding the etiology of POH can be attained, facilitating the initiation of appropriate treatment.

In this study, we intended to assess the clinical presentation, risk factors, dermoscopic patterns, and QoL in POH. We also evaluated the usefulness of the Melasma Quality of Life (MELASQOL) scale in POH patients.

PARTICIPANTS AND METHODS

This case-control study was carried out from November 2017 to August 2019 after obtaining permission from the Institutional Ethics Committee. One hundred consecutive clinically diagnosed POH cases aged between 18 to 50 years along with 100 age and gender-matched controls (healthy attendants of patients) were included in the study. Those patients who were on topical medication for POH in the past four weeks were excluded.

After informed consent, the patients' demographic details, history and clinical examination pertaining to the disease were noted. Risk factors like family history, slee*p* < 6 hours/day, watching TV for more than 8 hours/day, stress, and the habit of rubbing eyes regularly were assessed in all cases and controls. Stress was examined using the Perceived Stress Scale [5]. Grading of POH in the Indian population (in comparison to surrounding skin) was done as follows [3]:

- 0 – Skin color comparable to other facial skin areas.
- 1 – Mild infraorbital pigmentation.
- 2 – Pronounced pigmentation.
- 3 – Deep dark color, all eyelids involved.
- 4 – Grade 3 with extension beyond infraorbital fold.

Grading of POH was confirmed both by the investigator and a consultant dermatologist.

Dermoscopic examination of the periorbital area was done using a Dermlite DL4 (3Gen, Inc, USA) dermoscope. There are no approved tests or accepted questionnaires to assess the QoL of POH patients. However, since this disease resembles melasma in many aspects, we used the MELASQOL scale [6].

Statistical tests employed were the chi-squared, Fisher, Mann Whitney, and ANOVA tests. Mean, median, standard deviation, and percentages were used for descriptional statistics. $P < 0.05$ was considered statistically significant. Univariate analysis was used to assess risk factors. All tests were conducted using SPSS 21.0 version for windows.

RESULTS

The mean age was 29.03 years (SD +/- 7.9) among the cases and 25.22 years (SD +/- 6.26) among the controls. The majority of cases (43%) belonged to the 26-35 years' age group. The male to female ratio in cases and controls was 1:3.34 and 1:1.5, respectively. A female preponderance was noted in the cases (n = 77).

None of the cases belonged to grade 0 or grade 1 POH. Grade 4 POH was seen in 43% (n = 43), grade 3 in 41% (n = 41), and grade 2 in 16% (n = 16). The mean age in those with grade 2 POH was 24.69 (SD+/-5.47) years, grade 3 was 27.83 (SD+/- 7.01) years, and grade 4 was 31.79 (SD+/-8.55) years. The higher age group had more severe POH ($P = 0.0003$). In grades 2-4, there was a female preponderance of 93.8% in grade 2, 73.2% in grade 3, and 74.4% in grade 4 compared to 6.3% in grade 2, 26.8% in grade 3, and 25.6% in grade 4 in males. Comparison between the grades of POH and gender was not significant ($P = 0.2191$) (Figure 1).

Among the cases, the most common occupation was housewives (37%), followed by students (22%) and engineers (11%). Housewives were the most common group to seek medical care for POH. Comparison between the grades of POH and occupation was not significant ($P = 0.9$). Mean duration of pigmentation (in months) was 53.19 (SD+/-62.72), 45.63(SD+/-54.28) and 39.02(SD+/-42.64) in grade 4, 2, and 3 respectively ($P = 0.5$).

Risk factors like family history, sleep for less than 6 hours, stress, and habit of rubbing eyes regularly were significantly associated with POH, whereas factors like usage of eye cosmetics or

Figure 1. Clinical grades of periorbital hyperpigmentation: (a) control, (b) Grade 2, (c) Grade 3, (d) Grade 4.

spectacles, and watching TV or a computer screen for more than 8 hours were not associated with POH (Table 1) Comparison between the grades of POH and risk factors yielded no significant results ($P > 0.05$).

A history of systemic illness (anemia, atopy, thyroid dysfunction, diabetes, or hypertension) was seen in 27% of cases ($P = 0.0001$). Atopy ($P = 0.002$) and anemia ($P = 0.013$) were most significantly associated with POH. Within the grades, 48.1% in grade 3, 44.4% in grade 4, and 7.4% in grade 2 had a history of systemic illness with no statistical significance ($P = 0.3$).

Dermoscopic patterns observed in POH include pseudoreticular (74%), blotchy (71%), superficial dilated veins (46%), speckled (27%), telangiectasia (7%) and reticulate (2%) patterns. In controls, we observed the pseudoreticular (100%), superficial dilated veins (72%), and blotchy (19%) patterns (Table 2). On comparison of dermoscopic patterns with grades, the blotchy ($P = 0.02$) and speckled ($P = 0.02$) patterns were more common with grade 4, while the pseudoreticular ($P = 0.02$) pattern and superficial dilated veins ($P = 0.02$) were more common with grade 3 (Figure 2).

MELASQOL was used to assess the QoL of POH patients. A study showed that the concise form of MELASQOL has the same effect in measuring QoL in patients with melasma as the complete form [7]. Hence, the concise MELASQOL was used for assessing QoL in our study. It was found that QoL was affected in 30.6%, neutral in 5.7%, and was not affected in 63.7% of POH cases. The mean MELASQOL score was 27.31 (SD+/-14.53), 29.44 (SD+/-14.75), and 30.07 (SD+/-17.13) in grades 2, 3, and 4, respectively, with no statistical significance ($P = 0.8$) (Table 3).

DISCUSSION

Currently, POH is a common aesthetic concern, particularly among females. Though common, the etiology is not well understood, and the treatment remains unsatisfactory. Diagnosis is often made on clinical grounds. Non-invasive techniques like dermoscopy can help in assessing the severity and probable cause [3,8-10].

As observed by others [9,11], POH in our patients

Table 1. Risk factors of periorbital hyperpigmentation (POH)

Risk factors	Group		*P*-value
	POH n (%)	Control n (%)	
Family history			
No	73 (73%)	87 (87%)	0.013
Yes	27 (27%)	13 (13%)	
Sleep < 6 hours/day			
No	66 (66%)	84 (84%)	0.003
Yes	34 (34%)	16 (16%)	
Watching TV >8 hours/day			
No	98 (98%)	100 (100%)	0.2
Yes	2 (2%)	0 (0%)	
Watching computer >8 hours/ day			
No	88 (88%)	87 (87%)	0.8
Yes	12 (12%)	13 (13%)	
Stress			
No	49 (49%)	72 (72%)	0.001
Yes	51 (51%)	28 (28%)	
Usage of spectacles			
No	74 (74%)	82 (82%)	0.2
Yes	26 (26%)	18 (18%)	
Regular eye rubbing			
No	65 (65%)	81 (81%)	0.01
Yes	35 (35%)	19 (19%)	
Use of eye cosmetics			
No	73 (73%)	72 (72%)	0.09
Yes	27 (27%)	28 (28%)	

Abbreviations: n, number; POH, periorbital hyperpigmentation.

Table 2. Dermoscopic patterns of periorbital hyperpigmentation (POH)

Dermoscopic patterns	Group		*P*-value
	POH n (%)	Control n (%)	
Pseudoreticular			
No	26 (26%)	0 (0%)	<0.0001
Yes	74 (74%)	100 (100%)	
Blotchy			
No	29 (29%)	81 (81%)	<0.0001
Yes	71 (71%)	19 (19%)	
Reticulate			
No	98 (98%)	100 (100%)	0.2
Yes	2 (2%)	0 (0%)	
Speckled			
No	73 (73%)	100 (100%)	<0.0001
Yes	27 (27%)	0 (0%)	
Superficial dilated veins			
No	54 (54%)	28 (28%)	<0.0001
Yes	46 (46%)	72 (72%)	
Telangiectasia			
No	93 (93%)	100 (100%)	0.007
Yes	7 (7%)	0 (0%)	

Abbreviations: n, number; POH, periorbital hyperpigmentation.

was common in the age group of 26-35 years. However, Sheth *et al.* reported POH in younger ages (16-25 years) [2]. A female preponderance (77%) was seen as they are more likely to seek medical care for POH [2,6,8,9]. Housewives (37%) were the most commonly affected group, followed by students (22%) and engineers (11%).

Factors like family history, lack of sleep, stress, and regular rubbing of eyes were associated with the risk of developing POH. Goodman *et al.* stated that POH has a familial inheritance pattern [12]. Stress and fatigue play significant roles in the development of POH [13]. The often-implicated reasons like watching TV or using a computer for long hours and using eye cosmetics or spectacles were not associated with a higher risk of POH. We have compared our findings against the risk factors related to POH from previous studies (Table 4). No study has agreed upon a single risk factor for POH. It seems multiple factors have a role in causing POH. Systemic illnesses like anemia and atopy can also contribute to POH. This may be explained by frequent rubbing of eyes in atopics

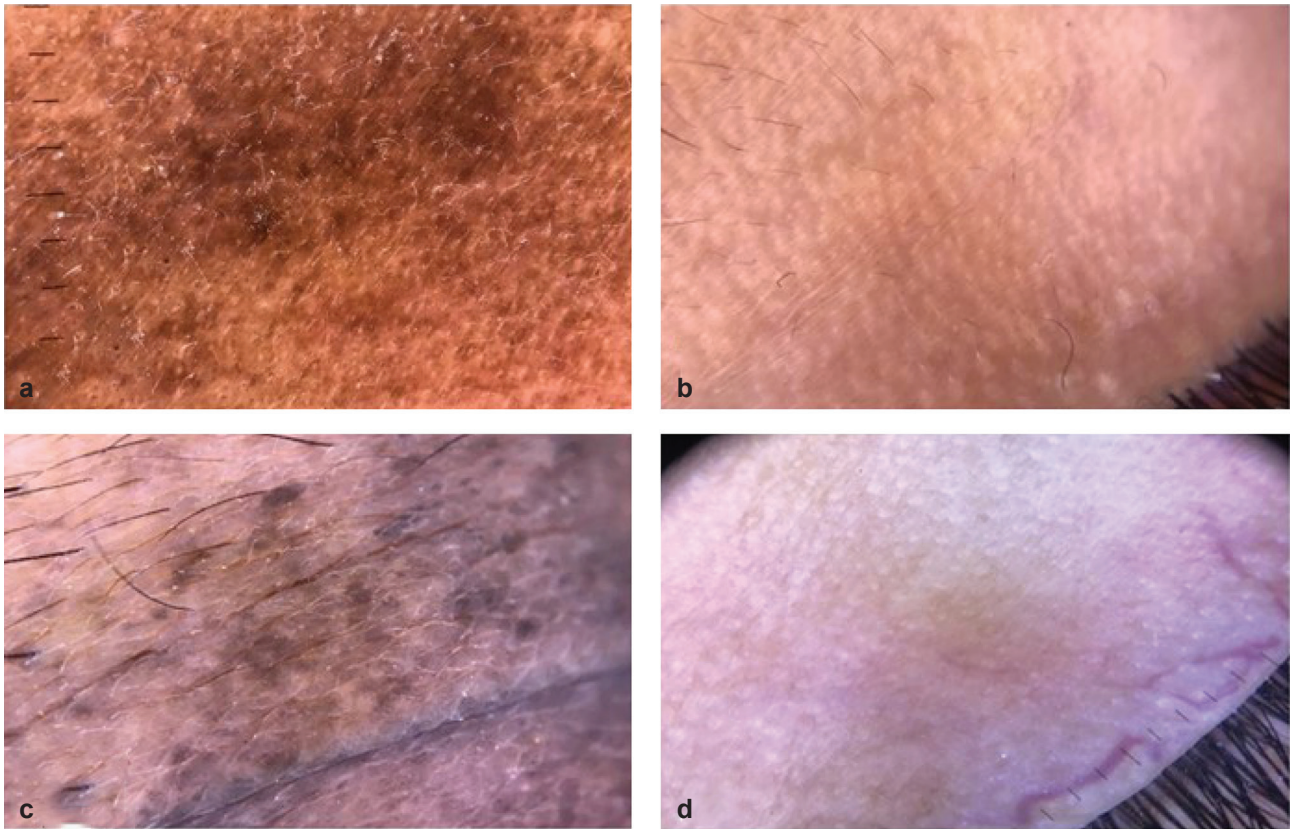

Figure 2. Dermoscopic (Dermlite DL4 with 10× magnification and cross-polarized & unpolarized lights) patterns of periorbital hyperpigmentation: (a) blotchy, (b) pseudoreticular, (c) speckled, (d) telangiectasia.

Table 3. Mean Melasma Quality of Life (MELASQOL) score in different periorbital hyperpigmentation (POH) grades

		MELASQOL	
		Mean	**SD**
POH grade	2.00	27.31	14.53
	3.00	29.44	14.75
	4.00	30.07	17.13
	Total	29.37	15.67

Abbreviations: MELASQOL, mean melasma quality of life; n, number; POH, periorbital hyperpigmentation; SD, Standard deviation.

and vasoconstriction in anemia [1,2,14].

Grading of POH was done according to the severity of pigmentation, and this grading was compared with age, gender, occupation and risk factors. Grade 4 was found to be the predominant grade, followed by grade 3 and grade 2, respectively. This was in contrast to a previous study, where grade 2 was more common, followed by grade 3 [11]. Higher age was found to be associated with higher grades of POH.

Table 4. Comparison of periorbital hyperpigmentation (POH) risk factors across different studies

Risk factor	Studies concerning POH and their findings in percentages		
	Present study (%)	**Sheth *et al.* [2] (%)**	**David *et al.* [11] (%)**
Family history	27	63	43.2
Lack of sleep	34	40	20.4
Watching TV >8 hours /day	2	10.5	19.2
Watching computer > 8 hours/day	12	2.5	8.4
Stress	51	71	15.2
Usage of spectacles	26	12	17.6
Regular eye rubbing	35	32.5	56.8
Use of eye cosmetics	27	36.5	

Abbreviations: POH, periorbital hyperpigmentation.

Most patients showed multiple dermoscopic patterns. Among these, the blotchy, speckled and telangiectasia patterns were significantly associated with POH. The pseudoreticular pattern and superficial dilated veins may not be of significance in POH patients as these were also seen in controls. Within the grades, grade 4 showed predominant blotchy and speckled patterns, while the pseudoreticular pattern and superficial dilated veins were associated with grade 3. Multiple patterns can be present in a single individual. The blotchy, speckled, and telangiectasia patterns could be considered as the typical patterns of POH. Studies on dermoscopy of POH have described various patterns with no consensus. Jage *et al.* described dermoscopic patterns as blotches, exaggerated pigment network, coarse speckled, fine speckled, globules, telangiectases, superficial dilated vessels, atrophy, and exaggerated skin markings [9]. Mostafa *et al.* described them as erythema, telangiectasia, pseudonetwork, blotches, and multicomponent [10]. Gaon *et al.*, in their case series, described them as pigmented, vascular, and mixed types [8]. Some authors have also classified dermoscopic patterns as mixed, epidermal, and dermal [3]. The dermoscopic changes seen in melasma are predominantly pigmentary patterns with brown reticular networks and scattered dark brown granules in epidermal types. In the dermal type, there is uniform dark brown to grey pigmentation, while the mixed type shows features of both the epidermal and dermal types. Vascular involvement is minimal [15]. Though clinically melasma and POH resemble each other, the dermoscopic findings vary.

We assessed QoL using the MELASQOL tool. The QoL was not affected in 63.7% of cases remained neutral in 5.7%. Though not statistically significant, QoL was harmed more in higher grades of POH. There seem to be few studies assessing QoL in POH. Ranjan *et al.* studied QoL in POH patients before and after treatment showing a higher mean Dermatology Life Quality Index (DLQI) in pretreatment patients and observed a significant improvement in QoL post-treatment [16]. While using the MELASQOL tool, we observed that the questions were not pertinent to POH, thus making it difficult to assess the QoL. Hence, we believe that there is a need to develop a specific tool to evaluate QoL in POH.

The most important limitations of our study included the difficulty in taking lower eyelid photos due to the comparatively larger diameter of the dermoscope and the difficulty in assessing QoL due to absence of a representative scoring system.

CONCLUSION

Periorbital hyperpigmentation (POH) commonly affects females, and higher grades are seen in slightly older patients. Family history, lack of sleep, stress, and regular eye rubbing are the probable risk factors for developing POH. The diagnosis is often clinical. However, the dermoscopic examination may help in assessing the severity. Though multiple patterns can be seen in a single individual, the blotchy, speckled, and telangiectasia patterns could be the typical dermoscopic patterns in POH, especially in higher grades. A consensus on dermoscopic findings in POH needs to be achieved. The QoL may be harmed in POH, particularly with higher grades. Using the MELASQOL scale in POH may not be helpful in assessing QoL. There is a need to develop consensus about the dermoscopic pattens of POH and to develop a tool for evaluating QoL in POH.

Conflicts of interest: None declared.

REFERENCES

1. Sarkar R, Ranjan R, Garg S, et al. Periorbital hyperpigmentation: a comprehensive review. J Clin Aesthetic Dermatol. 2016;9(1):49–55.
2. Sheth PB, Shah HA, Dave JN. Periorbital hyperpigmentation: a study of its prevalence, common causative factors and its association with personal habits and other disorders. Indian J Dermatol. 2014;59(2):151–7.
3. Ahuja SK, Deshmukh AR, Khushalani SR. A study of dermatoscopic pattern of periorbital hypermelanosis. Pigment Int. 2017;4(1):29–34.
4. Nischal KC, Khopkar U. Dermoscope. Indian J Dermatol Venereol Leprol. 2005;71(4):300–3.
5. Cohen S, Kamarck T, Mermelstein R. A global measure of perceived stress. J Health Soc Behav.1983;24(4):385-96.
6. Lieu TJ, Pandya AG. Melasma quality of life measures. Dermatol Clin. 2012;30(2):269–80, viii.
7. Yalamanchili R, Shastry V, Betkerur J. Clinico-epidemiological study and quality of life assessment in melasma. Indian J Dermatol. 2015;60(5):519.

8. Gáon NQ, Romero W. Dermoscopy in periorbital hyperpigmentation: an aid in the clinical type diagnosis. Surg Cosmet Dermatol. 2014;6(2):171–2.
9. Jage M, Mahajan S. Clinical and dermoscopic evaluation of periorbital hyperpigmentation. Indian J Dermatopathol Diagn Dermatol. 2018;5(1):42–7.
10. Mostafa WZ, Kadry DM, Mohamed EF. Clinical and dermoscopic evaluation of patients with periorbital darkening. J Egypt Women's Dermatol Soc. 2014;11(3):191.
11. David BG, Menon RR, Shankar R. A clinico-epidemiological study of periorbital melanosis. Int J Res Dermatol. 2017;3(2):245–50.
12. Goodman RM, Belcher RW. Periorbital hyperpigmentation. An overlooked genetic disorder of pigmentation. Arch Dermatol. 1969;100(2):169–74.
13. Gathers R. Periorbital hypermelanosis. In: Paul K (Eds). Dermatology for skin of color. New York: McGraw Hill; 2009. 341–3.
14. Huang Y-L, Chang S-L, Ma L, et al. Clinical analysis and classification of dark eye circle. Int J Dermatol. 2014;53(2):164–70.
15. Nanjundaswamy BL, Joseph JM, Raghavendra KR. A clinico dermoscopic study of melasma in a tertiary care center. Pigment Int. 2017;4(2):98-103.
16. Ranjan R, Sarkar R, Garg VK, et al. A comparative study of two modalities, 4% hydroquinone versus 30% salicylic acid in periorbital hyperpigmentation and assessment of quality of life before and after treatment. Indian J Dermatol. 2016;61(4):413–7.

