Clinicopathological features of granulomatous skin lesions

Maryam Khalili, MD [1]
Simin Shamsi Meymandi, MD [2]
Saman Mohammadi, MD [1]
Mahin Aflatoonian, MD [1*]
Elahe Kooshesh, MD [3]

1. Department of Dermatology, Kerman University of Medical Sciences, Iran
2. Pathology and Stem Cell Research Center, Kerman University of Medical Sciences, Iran
4. Department of Dermatology, Afzalipour Hospital, Kerman University of Medical Sciences, Iran

*Corresponding author:
Mahin Aflatoonian, MD
Department of Dermatology, Kerman University of Medical Sciences, Iran
E-mail: aflatoonian@kmu.ac.ir, maaflatoonian@gmail.com

Received: 1 January 2022
Accepted: 4 May 2022

Background: Granulomatous skin lesions are characterized by aggregation of activated histiocytes. Granulomatous skin lesions are classified as xanthomatous, necrobiotic, tuberculoid, sarcoidal, and foreign body types. This study evaluates the clinicopathological features of patients with granulomatous skin lesions.

Methods: We conducted a cross-sectional study of 232 skin biopsies diagnosed as granulomatous skin lesions over ten years from patients referred to Afzalipour Hospital, Kerman, Iran. Demographics, clinical features of lesions, and pathological characteristics were recorded. Then, the correlation of the final diagnosis with the demographic and clinical features of the patients was assessed via the independent t-test and chi-squared test.

Results: Most patients were in their third decade of life, with a male-to-female ratio of 1.05 to 1. The most common types of granuloma were tuberculoid (60.3%), necrobiotic (12.5 %), and foreign body type (11.2%). Infectious disease was the most common cause of granulomatous lesions (64.2 %); leishmaniasis constituted approximately 96% of cases. The most common causes of non-infectious granulomatous skin diseases were foreign body granuloma (26.2%), granuloma annulare (23.2%), and xanthogranuloma (12.1%). There was a significant correlation between dermatologic disease type and disease duration ($P = 0.024$).

Conclusion: In the current study, the most common type of granuloma was tuberculoid, followed by necrobiotic and foreign body type granulomas. Infectious diseases were the most common cause of granulomatous skin lesions. Furthermore, the most common granulomatous skin diseases were leishmaniasis, foreign body granuloma, and granuloma annulare. The least common granulomatous skin lesions were sporotrichosis and gout.

Keywords: granuloma, pathology, skin

Iran J Dermatol 2023; 26: 79-84

DOI: 10.22034/ijd.2022.322506.1484

INTRODUCTION

Granulomatous skin lesions are characterized by aggregation of activated histiocytes. Originating from myeloid cells of the bone marrow, monocytes mature and enter the blood circulation to reach tissues, where they are known as histiocytes. Activation of major histocompatibility type II (MHC II) and T helper 1 (TH1)-associated lymphocytes secondary to recognition

Please cite this article as: Khalili M, Shamsi Meymandi S, Mohammadi S, Aflatoonian M, Kooshesh E. Clinicopathological features of granulomatous skin lesions. Iran J Dermatol. 2023;26(2):79-84. doi: 10.22034/ijd.2022.322506.1484.

of foreign antigens leads to the release of chemokines and cytokines [interlukin-2 (IL-2), interferon (INF)-gamma, tumor necrosis factor (TNF)-α, IL-6, IL-17] that convert activated histiocytes to epithelioid histiocytes cells, eventuating in granulomatous inflammation [1-5].

Granulomatous skin lesions are classified as xanthomatous, necrobiotic (palisading or interstitial), tuberculoid, sarcoidal, and foreign body types. Several factors, including the presence of necrobiosis (collagen and elastin degeneration), central caseating necrosis, presence or absence of lymphocytes in inflammation, type of giant cells (foreign body giant cells, Langerhans cells, and Touton giant cells), and pattern of distribution of histiocytes have essential roles in distinguishing different types of granuloma. A definite diagnosis can be difficult in many cases due to similarities in clinical and pathological features [1-5]. Therefore, additional diagnostic methods such as smear and culture from the lesion, special staining (such as Alcian blue for mucin, Ziehl-Neelsen for tuberculosis, Giemsa for leishmaniasis, and Fite-Faraco for leprosy), polarized light for detection of foreign material, and molecular techniques such as polymerase chain reaction (PCR), as well as clinicopathological correlation, can help make the correct diagnosis [1-5]. In this study, we evaluated the clinicopathological features of patients with granulomatous skin lesions referring to Afzalipour Hospital of Kerman, Iran.

METHODS

We conducted a retrospective cross-sectional study of 232 skin biopsies diagnosed as granulomatous skin lesions from patients referred to Afzalipour Hospital over ten years. Firstly, demographic features (age and sex) and clinical features of lesions (duration, site, and number of differential diagnoses) were recorded. Then, pathological features (final diagnosis, type of inflammatory cells, and type of granuloma [xanthomatous, necrobiotic, sarcoidal, tuberculoid, and foreign body]) were evaluated. Finally, the correlation of the final diagnosis with the demographic and clinical features of the patients was assessed.

Statistical analysis

Data were analyzed by SPSS 16 (software IBM, Armonk, NY, USA). Frequency, percentage, mean, and standard deviation were used for descriptive analysis. Independent t and chi-squared tests were utilized to evaluate the correlation between quantitative and qualitative data with the final diagnosis, respectively.

Ethical consideration

This study was approved in ethical committee of Kerman university of medical sciences with ethical code of IR.KMU.AH.REC.1396.2164.

RESULTS

Two hundred and thirty-two patients with granulomatous skin lesions with a mean age of 36.53 ± 21.86 years (range 1 month–88 years) were evaluated. The mean duration of lesions was 12.93 ± 8.63 months (range 3 weeks–10 years). The male-to-female ratio was 1.05 to 1, with males constituting 51.3% of cases (Table 1). The

Table 1. Frequency of granulomatous dermatoses based on the sex of the patients and the duration of the lesions

Granulomatous skin disease	Frequency N (%)	Male N (%)	Female N (%)	Duration Mean ± SD (months)
Leishmaniasis	144 (62.1)	83 (69.7)	61 (53.9)	12.53 ± 1.62
Foreign body granuloma	26 (11.2)	13 (10.9)	13 (11.5)	18.17 ± 7.94
Granuloma annulare	23 (9.9)	7 (5.8)	16 (14.2)	9.83 ± 2.50
Xanthogranuloma	12 (5.2)	5 (4.2)	7 (6.2)	6.18 ± 1.21
Granulomatous rosacea	5 (2.1)	1 (0.8)	4 (3.5)	23 ± 5.98
Necrobiosis lipoidica	5 (2.1)	3 (2.5)	2 (1.8)	21.3 ± 11.59
Sarcoidosis	4 (1.7)	0 (0)	4 (3.5)	7.25 ± 2.42
Granulomatous cheilitis	3 (1.3)	1 (0.8)	2 (1.8)	27.33 ± 22.40
Xanthoma	2 (0.9)	1 (0.8)	1 (0.8)	12
Cutaneous Crohn's disease	2 (0.9)	0 (0)	2 (1.8)	72
Leprosy	2 (0.9)	1 (0.8)	1 (0.8)	24
Tuberculosis	2 (0.9)	2 (1.6)	0 (0)	3
Gout	1 (0.4)	1 (0.8)	0 (0)	60
Sporotrichosis	1 (0.4)	1 (0.8)	0 (0)	5

mean number of clinical differential diagnoses was 3.20 ± 1.61 (range 0–5); more than half of them (59.1%) correlated with the final diagnosis. The most common type of granuloma was tuberculoid (60.3%), followed by necrobiotic (12.5 %), foreign body type (11.2%), xanthomatous (12.1%), and sarcoidal (3.8%). The most and least common granulomatous diseases were leishmaniasis (62.1%) and sporotrichosis (0.4%), respectively (Table 1, 2, Figures 1-6).

The most common site of involvement was the upper limb (39.9%); other sites in descending order were the head and neck (35.5%), lower limbs (18.4%), trunk (3.9%), and genitalia (2.2%). The inflammatory cells other than histiocytes were lymphocytes (54.9%), giant cells (29.8%), plasma cells (14%), neutrophils (6.8%), and eosinophils (4.3%). There was no significant correlation between the type of granulomatous disease and demographic features of the patients ($P > 0.05$); however, there was a significant correlation between the type of dermatologic disease and duration of disease ($P = 0.024$) (Table 1, 2).

In the present study, patients affected by leishmaniasis were classified into three groups: acute (less than 2 years), chronic (2 years or more), and lupoid types (development of new apple-jelly papules within or around the site of previous leishmaniasis scar). Most of the leishmaniasis cases were acute (81.9%). Acute and chronic types were most common in males, while the lupoid type was most common in females. The mean age of the cases in the chronic type was higher than other types of leishmaniasis ($P > 0.05$) (Table 3).

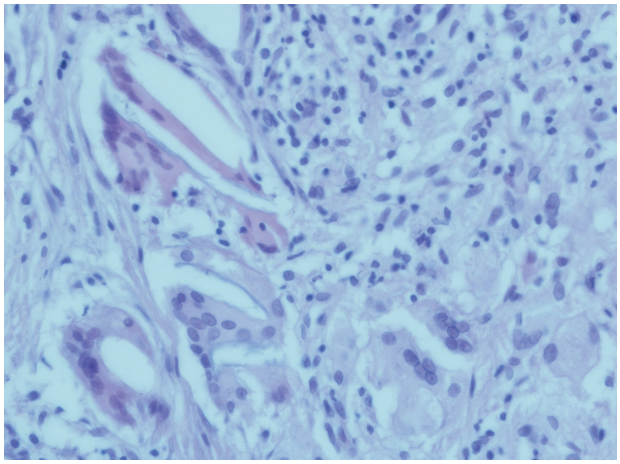

Figure 1. Foreign body granuloma; numerous foreign body type giant cells, histiocytes, and lymphocytes infiltrated around keratin materials secondary to a ruptured epidermoid cyst (H&E ×400).

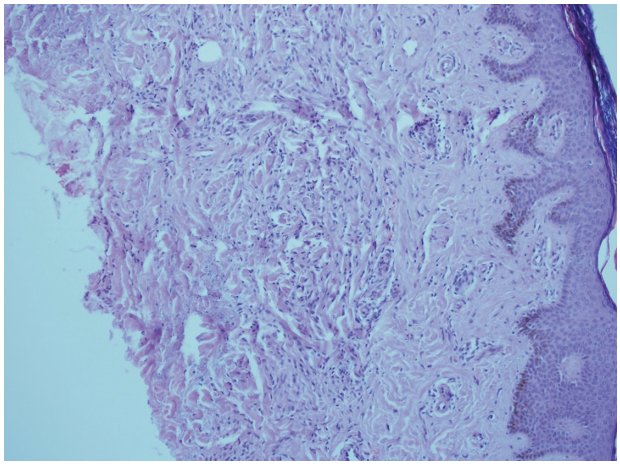

Figure 2. Granuloma annulare; palisaded granuloma including epithelioid histiocytes and lymphocytes surrounding basophilic degenerative collagen fibers (H&E ×40).

Table 2. Frequency of granulomatous skin lesions based on age

Granulomatous skin disease	Age groups (years)								
	0-10	11-20	21-30	31-40	41-50	51-60	61-70	71-80	81-90
Leishmaniasis	20 (13.9)	20 (13.9)	22 (15.3)	17 (11.8)	18 (12.5)	14 (9.7)	11 (7.6)	10 (6.9)	12 (8.3)
Foreign body granuloma	4 (15.4)	6 (23.1)	6 (23.1)	2 (7.7)	1 (3.8)	3 (11.5)	3 (11.5)	1 (3.8)	0 (0)
Granuloma annulare	5 (21.7)	2 (8.7)	4 (17.4)	3 (13)	4 (17.4)	3 (13)	2 (8.7)	0 (0)	0 (0)
Xanthogranuloma	7 (63.6)	1 (9.1)	1 (9.1)	2 (18.2)	1 (9.1)	0 (0)	0 (0)	0 (0)	0 (0)
Granulomatous rosacea	0 (0)	0 (0)	0 (0)	2 (40)	3 (60)	0 (0)	0 (0)	0 (0)	0 (0)
Necrobiosis lipoidica	0 (0)	0 (0)	0 (0)	0 (0)	1 (20)	2 (40)	1 (20)	1 (20)	0 (0)
Sarcoidosis	0 (0)	0 (0)	1 (25)	0 (0)	1 (25)	2 (50)	0 (0)	0 (0)	0 (0)
Granulomatous cheilitis	0 (0)	1 (33.3)	1 (33.3)	0 (0)	0 (0)	1 (33.3)	0 (0)	0 (0)	0 (0)
Xanthoma	0 (0)	0 (0)	0 (0)	1 (100)	0 (0)	0 (0)	0 (0)	1	0 (0)
Cutaneous Crohn's disease	0 (0)	0 (0)	0 (0)	0 (0)	1 (50)	1 (50)	0 (0)	0 (0)	0 (0)
Leprosy	0 (0)	0 (0)	0 (0)	1 (50)	0 (0)	1 (50)	0 (0)	0 (0)	0 (0)
Tuberculosis	0 (0)	0 (0)	0 (0)	1 (50)	0 (0)	1 (50)	0 (0)	0 (0)	0 (0)
Gout	0 (0)	0 (0)	0 (0)	0 (0)	0 (0)	0 (0)	1 (100)	0 (0)	0 (0)
Sporotrichosis	0 (0)	0 (0)	0 (0)	0 (0)	1 (100)	0 (0)	0 (0)	0 (0)	0 (0)

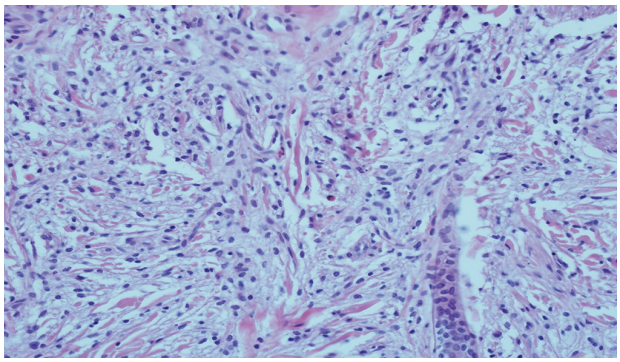

Figure 3. Juvenile xanthogranuloma; infiltrations of foamy epithelioid histiocytes, lymphocytes, some eosinophils, and Touton giant cells with a wreath-like arrangement of nuclei (H&E, f: ×400, g: ×400).

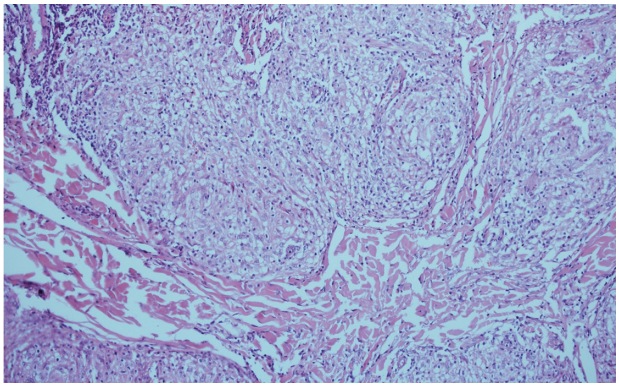

Figure 5. Sarcoidosis; numerous well-defined granulomas (naked tubercles) including epithelioid histiocytes and nearly devoid of lymphocytic infiltration (H&E ×100).

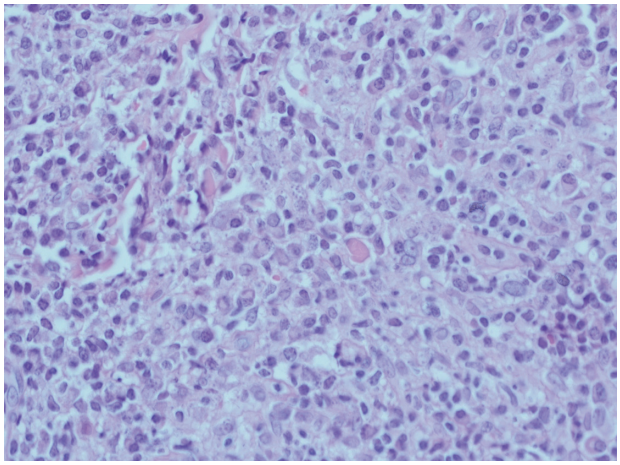

Figure 4. Leishmaniasis; mixed infiltration of epithelioid histiocytes, lymphocytes, and plasma cells with numerous amastigotes within macrophages (H&E ×400).

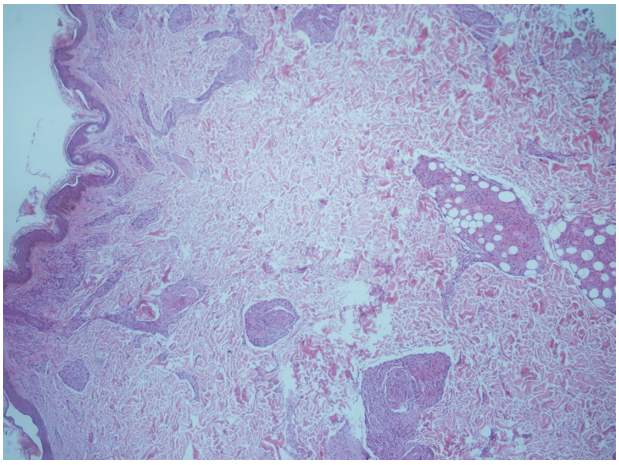

Figure 6. Tuberculoid leprosy; linear granulomas within dermis and perineural areas, including epithelioid histiocytes, lymphocytes and plasma cells (H&E ×40).

Table 3. Demographical features of leishmaniasis patients based on type of leishmaniasis

Type of leishmaniasis	Acute	Chronic	Lupoid	*P*-value
Sex N (%)				
Female	48 (40.7)	5 (41.7)	5 (41.7)	0.170
Male	70 (59.3)	7 (58.3)	7 (58.3)	
Age, years (mean ± SD)	36.88 ± 1.18	43.76 ± 8.06	43.76 ± 8.06	0.807
Most common site (%)	Head and neck (46.9%)	Head and neck (43.7%)	Head and neck (43.7%)	0.476

DISCUSSION

In the present study, infectious disease was the most common cause (64.2%) of granulomatous skin lesions, consistent with most prior studies [6-11]. The most common cause of infectious diseases was leishmaniasis, similar to a study in Pakistan [6]. We could not correlate the type of leishmaniasis with the demographic features of patients and the site of involvement, in line with Meymandi *et al.* [7]. The majority of cases of leishmaniasis in the current study had the tuberculoid pattern of granuloma (91.7%), while the remaining (including chronic type) had a xanthomatous pattern.

In the current study, the most common granulomatous skin diseases were leishmaniasis (62.1%), foreign body granuloma (11.2%), and granuloma annulare (9.9%). In contrast to the present study, the most common granulomatous skin diseases in two studies in India were leprosy and tuberculosis. This can be due to differences in geographical regions, environmental

factors, and socioeconomic factors [8,9].

In the present study, non-infection granulomatous diseases constituted 35.7 % of cases. The most common causes were foreign body granuloma (26.2%), granuloma annulare (23.2%), and xanthogranuloma (12.1%). In the study by Mohan *et al.,* non-infectious granulomas constituted a small percentage of granulomatous diseases (12.1%) due to the high prevalence of infectious diseases such as tuberculosis and leprosy in India. In that study, the most common causes of non-infections granuloma were sarcoidosis (21.1%) and granuloma annulare (15.4%) [10].

In the current study, foreign body granuloma was most commonly reported in the head and neck (46%) and in those younger than 40 years old (69.2%), with an equal ratio in both genders. In the study by Gautam *et al.* in India, foreign body granulomas were observed in 18.9% of granulomatous skin diseases, most commonly in the head and neck area. Moreover, the most common cause of foreign body granuloma in the latter study, as in our study, was ruptured epidermal cysts [11].

In the current study, granuloma annulare was the second most common non-infectious granulomatous skin disease. It was more prevalent in females (69.6%), in the upper limbs (56.5%), and in those aged under 40 years (60%). Moreover, all cases had necrobiotic patterns (including interstitial and palisading patterns in 58% and 48%, respectively). Similarly, in other studies, granuloma annulare predominantly occurred in females and in the extremities. Furthermore, the age of patients varied from 8–77 years, with the vast majority in the decades 3–5 of life, with a mean disease duration of 10–20 months [12-15].

Juvenile xanthogranuloma was our study's third most prevalent non-infectious granulomatous skin disease. It was most commonly seen in females (58.3%), in the head and neck areas (50%), and in those who were under ten years old (58.3%). Likewise, other studies recorded it most frequently in the head and neck and within the first decade of life. Previous studies reported a male-to-female ratio of 1–1.4 to 1 [16-18].

Granulomatous rosacea is a relatively rare granulomatous skin disease that presents as monomorphic brownish-red firm papules that predominantly involve periorificial areas of the face. It is most commonly observed in middle-aged females. The disease duration varies between 6 months to 4 years [19,20]. In the current study, granulomatous rosacea constituted a small percentage of granulomatous skin lesions (2.1%), with a female-to-male ratio of 4 to 1. Most cases were in the fifth decade, and the remaining was in the fourth decade of life. The average duration of the disease was approximately two years. Pathology assessment demonstrated epithelioid histiocytes intermixed with lymphoplasma cells developing a non-caseating tuberculoid granuloma.

Necrobiosis lipoidica is another type of granulomatous skin lesion with the arrangement of collagens in tier-like horizontal layers. Vasculitis, microangiopathy secondary to diabetes with thickened-wall blood vessels, plasma cell infiltrations, and septal panniculitis are other pathological characteristics of the lesions. It is usually observed in females with a female-to-male ratio of 3 to 1, appearing in the third to fourth decades of life [21,22]. In the current study, in contrast to other studies, males were involved more commonly than females (male-to-female ratio 1.5 to 1), and all patients were older than 40 years, with a mean disease duration of nearly 21 months.

The present study's least common granulomatous skin lesions were sporotrichosis and gout, with only one case of each disease.

CONCLUSION

In the current study, the most common types of granuloma were tuberculoid, followed by necrobiotic and foreign body type granulomas. Infectious diseases were the most common cause of granulomatous skin lesions. The most common infectious granulomatous skin disease was leishmaniasis. The leading causes of non-infectious granulomatous skin diseases were foreign body granuloma, granuloma annulare, and xanthogranuloma. The least common granulomatous skin lesions were sporotrichosis and gout. There was a significant correlation between dermatologic disease type and disease duration.

Acknowledgement

We would like to thank the staff of archive of dermatopathology for recording the information

Authors contributions

All authors contributed to the study conception and design. Data collection and analysis were performed by Elaheh Kooshesh, Maryam Khalili,

Saman Mohammadi, and Mahin Aflatoonian. The first draft of the manuscript was written by Mahin Aflatoonian and all authors commented on previous versions of the manuscript. All authors read and approved the final manuscript.

Funding source

No funding was received for conducting this study.

Conflict of interest: None declared.

REFERENCES

1. El-Khalawany M, Meraag I, Eassa B, et al. Clinicopathological features and the practice of diagnosing infectious cutaneous granulomas in Egypt. Int J Infect Dis. 2011;15(9):e620-6.
2. Shah KK, Pritt BS, Alexander MP. Histopathologic review of granulomatous inflammation. J Clin Tuberc Other Mycobact Dis. 2017;7:1-2.
3. Tronnier M, Mitteldorf C. Histologic features of granulomatous skin diseases. Part 1: Non-infectious granulomatous disorders. J Dtsch Dermatol Ges. 2015;13(3):211-6.
4. George VP, Srinivasan S. Histopathological spectrum of granulomatous skin lesions: a review. J Basic Clin Appl Health Sci. 2019;2(3):95–104.
5. Mitteldorf C, Tronnier M. Histologic features of granulomatous skin diseases. J Dtsch Dermatol Ges. 2016;14(4):378-88.
6. Qureshi R, Sheikh RA, ul Haque A. Chronic granulomatous inflammatory disorders of skin at a tertiary care hospital in Islamabad. Int J Pathol. 2018:31-4.
7. Meymandi SS, Dabiri S, Eslammanesh T, et al. Immunopathology of anthroponotic cutaneous leishmaniasis and incidental diagnostic tool of metastatic granuloma: a case-control study. Microb Pathog. 2021;152:104654.
8. Chakrabarti S, Pal S, Biswas BK, et al. Clinico-pathological study of cutaneous granulomatous lesions-a 5 yr experience in a tertiary care hospital in India. Iran J Pathol. 2016;11(1):54.
9. Grover S, Agale SV, D'Costa GF, et al. Clinico-histopathological spectrum of infectious granulomatous dermatoses in Western India-A representative study from Mumbai. J Clin Diagn Res. 2016;10(4):EC10.
10. Mohan H, Bal A, Dhami GP. Non-infectious granulomatous dermatitis: a clinicopathological study. J Cutan Pathol. 2006;33(12):767-71.
11. Gautam K, Pai RR, Bhat S. Granulomatous lesions of the skin. J Pathol Nepal. 2011;1(2):81-6.
12. Piette EW, Rosenbach M. Granuloma annulare: clinical and histologic variants, epidemiology, and genetics. J Am Acad Dermatol. 2016;75(3):457-65.
13. Kim KH, Shur KB, Lee JH, et al. The clinicopathologic study of granuloma annulare. Korean J of Dermatol. 2001;39(8):861-5.
14. Thornsberry LA, English JC. Etiology, diagnosis, and therapeutic management of granuloma annulare: an update. Am J Clin Dermatol. 2013;14(4):279-90.
15. Rodríguez-Garijo N, Tomás-Velázquez A, Estenaga A, et al. Granuloma annulare subtypes: sonographic features and clinicopathological correlation. J Ultrasound. 2021:1-7.
16. Janssen D, Harms D. Juvenile xanthogranuloma in childhood and adolescence: a clinicopathologic study of 129 patients from the kiel pediatric tumor registry. Am J Surg Pathol. 2005;29(1):21-8.
17. Pajaziti L, Hapçiu SR, Pajaziti A. Juvenile xanthogranuloma: a case report and review of the literature. BMC Res Notes. 2014;7(1):1-3.
18. Cypel TK, Zuker RM. Juvenile xanthogranuloma: case report and review of the literature. Can J Plast Surg. 2008;16(3):175-7.
19. Lee GL, Zirwas MJ. Granulomatous rosacea and periorificial dermatitis: controversies and review of management and treatment. Dermatol Clin. 2015;33(3):447-55.
20. Kelati A, Mernissi FZ. Granulomatous rosacea: a case report. J Med Case Rep. 2017;11(1):1-2.
21. Kota SK, Jammula S, Kota SK, et al. Necrobiosis lipoidica diabeticorum: a case-based review of literature. Indian J Endocrinol Metab. 2012;16(4):614.
22. Reid SD, Ladizinski B, Lee K, et al. Update on necrobiosis lipoidica: a review of etiology, diagnosis, and treatment options. J Am Acad Dermatol. 2013;69(5):783-91.