

# A rare case of scalp dermatofibrosarcoma protuberans

Sam K Touisserkani, MD <sup>1</sup>  
Azin Ayatollahi, MD <sup>2\*</sup>  
Kambiz Kamyab, MD <sup>3</sup>

1. Private Office, Tehran, Iran
2. Center for Research and Training in Skin Diseases and Leprosy, Tehran University of Medical Sciences, Tehran, Iran
3. Dermatopathology Department, Razi Hospital, Tehran University of Medical Sciences, Tehran, Iran

\*Corresponding author:

Azin Ayatollahi, MD  
Center for Research and Training in Skin Diseases and Leprosy, Tehran University of Medical Sciences, Tehran, Iran.  
Email: azinay@gmail.com

Received: 18 June 2021

Accepted: 17 August 2021

Dermatofibrosarcoma protuberans (DFSP) is a malignant, slow-growing, locally aggressive tumor of the skin with a high rate of recurrence. It is a very uncommon malignant skin tumor, especially in the head and neck area (10-15% of cases). This case report discusses a rare case of scalp DFSP.

**Keywords:** dermatofibrosarcoma protuberans, malignant, mixed tumor, scalp

Iran J Dermatol 2023; 26: 147-149

DOI: [10.22034/ijd.2021.291222.1388](https://doi.org/10.22034/ijd.2021.291222.1388)

## INTRODUCTION

Dermatofibrosarcoma protuberans (DFSP) is a relatively uncommon soft tissue low-grade malignant neoplasm, which most frequently affects the dermis and subcutis. It is a locally aggressive tumor and rarely metastasizes. DFSP represents a negligible proportion of cancer cases—less than 0.1%. Nearly half of DFSP cases are on the trunk, while the head and neck are affected in 10-15% of cases <sup>1,2</sup>. DFSP commonly occurs in adults aged 20-50 years. It is often misdiagnosed, and diagnostic delays with a median delay of 3 to 5 years commonly occur <sup>3</sup>.

Herein, we present a rare case of scalp DFSP in a 31-year-old woman with a relatively early diagnosis.

## CASE PRESENTATION

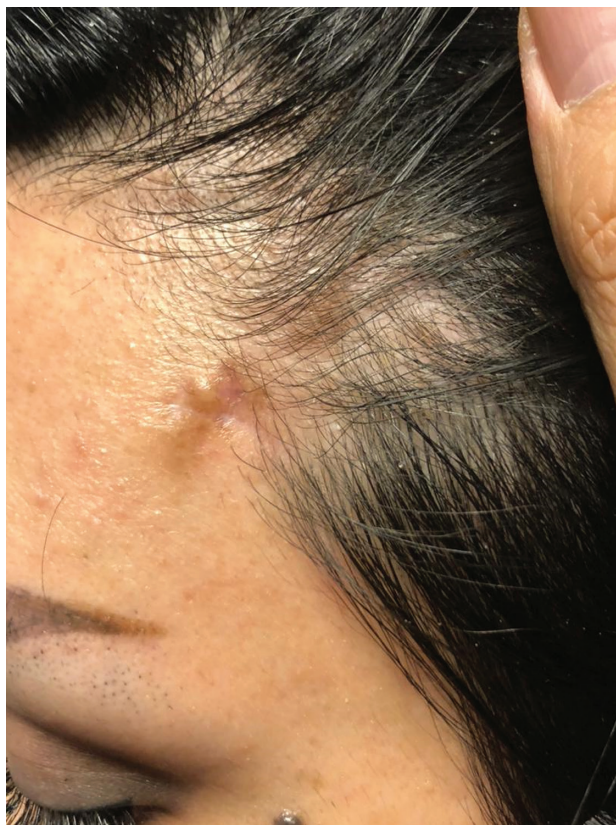We admitted a 31-year-old female who complained

of raised, painless lesions on her left lateral forehead for one year. On physical examination, two collinear lesions, a 1 cm firm brown nodule and a plaque, were observed (Figures 1 and 2). The remainder of the examination was unremarkable. A diagnostic workup for metastases was done, returning negative. A punch biopsy was taken. The histopathology reported uniform hypocellular spindle cell proliferation with lamellar collagen fibrosis in the upper to deep dermis. Adjacent to subcutis fat, a portion of spindle cell proliferation with a storiform pattern was noted (Figures 3 and 4). Immunohistochemical staining was positive for CD34 (Figure 5). The results were in favor of DFSP. The patient underwent wide local excision to the periosteum with 3 cm surgical margins. The removed tissue mass was sent to the pathologist. The frozen section procedure reported

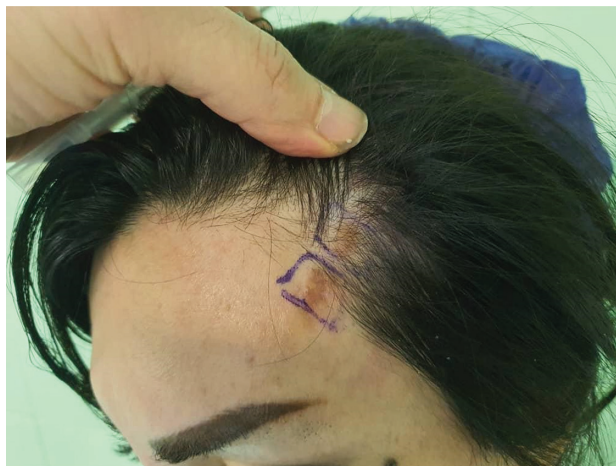Copyright: ©Iranian Journal of Dermatology. This is an Open Access article distributed under the terms of the [Creative Commons Attribution-NonCommercial 4.0 Unported License](https://creativecommons.org/licenses/by-nc/4.0/), which permits unrestricted use, distribution, and reproduction in any medium, provided the original work is properly cited.



Please cite this article as: Ayatollahi A, Touisserkani SK., Kamyab K. A rare case of scalp dermatofibrosarcoma protuberans. Iran J Dermatol. 2023; 26(3): 147-149.



**Figure 1.** The lesions on the left aspect of the forehead.

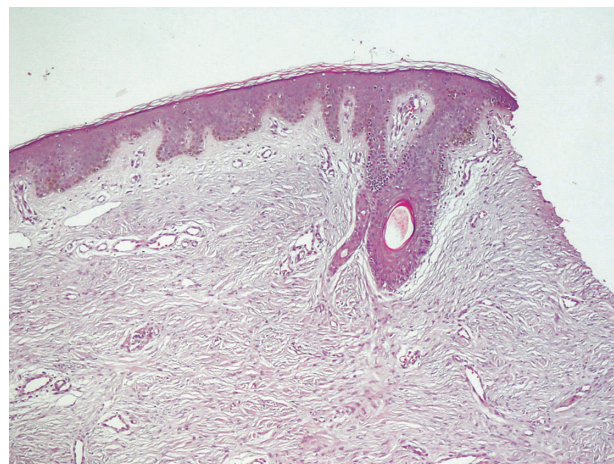


**Figure 2.** Another view of the lesions on the left aspect of the forehead.

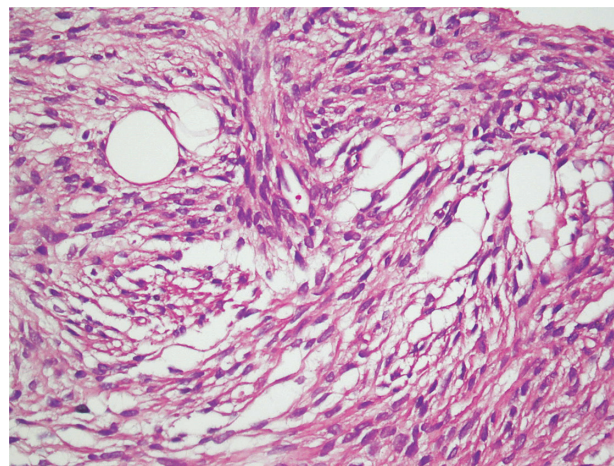
that the periosteum was affected. Extra curettage of the periosteum was done. A local flap and a skin graft were used for reconstruction.

### **Ethical considerations**

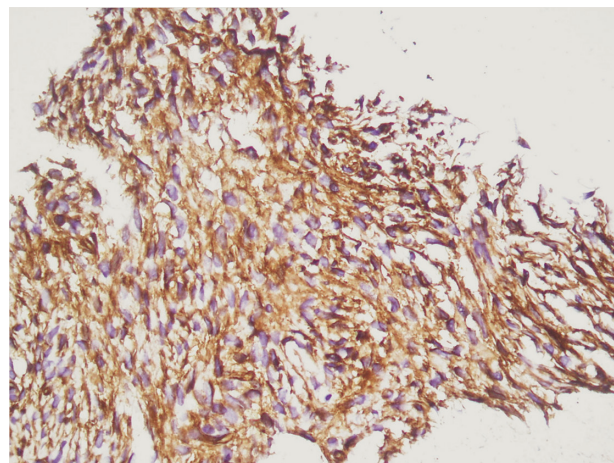
Informed consent was obtained from the patient for publication.



**Figure 3.** Histopathological section of the lesion (H&E stain, 10×)



**Figure 4.** Histopathological section of the lesion (H&E stain, 40×)



**Figure 5.** Immunostaining for CD34 (400×).

### **DISCUSSION**

Dermatofibrosarcoma protuberans (DFSP) is an uncommon malignant tumor, usually seen in adults



aged 20 to 50. It is a slow-growing, locally aggressive tumor with a great tendency for local recurrence. Metastasis is rare. The trunk and proximal limbs are the most common sites of involvement; the head and neck are rarely involved. The lesion may present as a small asymptomatic papule or non-indurated patch. The tumor has the potential to increase in size and form a nodule gradually, or it can convert into an atrophic or sclerotic plaque. DFSP may vary in size from a few millimeters to a few centimeters. Its differential diagnoses are sclerosing basal cell carcinoma, morphea, hypertrophic scar, keloid, and anetoderma <sup>1,4</sup>.

A monotonous storiform growth pattern of cytologically uniform tumor cells, with hyperchromatic and elongated nuclei, and a characteristic honeycomb pattern of infiltration into the subcutaneous fat are the classic histological features of DFSP. The small tumor cells with large, spindle-shaped nuclei embedded uniformly in the collagen stroma, parallel to the skin surface, are seen in the plaque type of DFSP. The nodular type displays the most distinctive features, including densely packed cells and irregular, intersecting bands that give rise to a storiform pattern. Immunohistochemically, DFSP is characterized by a positive reaction for CD34 <sup>5</sup>.

The treatment of choice is wide surgical excision with adequate margins of 3 to 5 cm <sup>4</sup>.

## CONCLUSION

As DFSP is a very rare tumor, especially in the head and neck area, it is important to consider the diagnosis of DFSP in head and neck lesions. All suspicious, persistent lesions should be biopsied.

To reduce the risk of recurrence and metastases, it is recommended to excise the lesion with sufficient margins as soon as possible.

## Authors contributions

Azin Ayatollahi: Drafting the manuscript

Sam K Touisserkani: Surgical procedure and revising the manuscript

Kambiz Kamyab: Pathological diagnosis and revising the manuscript

## Acknowledgments

None.

## Funding

None.

**Conflict of interest:** None declared.

## REFERENCES

1. Smola MG, Soyer HP, Scharnagl E. Surgical treatment of dermatofibrosarcoma protuberans. A retrospective study of 20 cases with a review of the literature. *Eur J Surg Oncol.* 1991; 17:447–53.
2. Chang CK, Jacobs IA, Salti GI. Outcomes of surgery for dermatofibrosarcoma protuberans. *Eur J Surg Oncol.* 2004; 30:341–5.
3. Valdivielso-Ramos M, Torrelo A, Campos M, et al. Pediatric dermatofibrosarcoma protuberans in Madrid, Spain: multi-institutional outcomes. *Pediatr Dermatol.* 2014;31(6):676–682.
4. Bogucki B, Neuhaus I, Hurst EA. Dermatofibrosarcoma protuberans: a review of the literature. *Dermatol Surg.* 2012; 38:537–51.
5. Dimitropoulos VA. Dermatofibrosarcoma protuberans. *Dermatol Ther.* 2008;21(6):428–32.