

# Treatment of Vitiligo with Blister Grafting Technique

Masoud Maleki, MD  
Zari Javidi, MD  
Mohammad Ebrahimi –rad, MD  
Hamid Hamidi, MD

Dermatology Department, Mashhad  
University of Medical Sciences, Imam  
Reza Hospital, Mashhad, Iran

Corresponding author:  
Masoud Maleki, MD  
Imam Reza Hospital,  
Mashad, Iran  
Email: Maleki@mums.ac.ir

Received: May 24, 2008  
Accepted: August 10, 2008

## Abstract

**Background:** Surgical treatments of vitiligo are punch grafting, blister grafting, flip-top transplantation, split skin grafting, etc aiming at rebuilding of melanocytic population in those patients who do not respond to medical treatment. The objective of this study was determination of efficacy of blister grafting technique in the treatment of vitiligo.

**Methods:** This study was done on 10 patients with vitiligo of face and /or distal extremities who had received different medical treatments including PUVA and had not responded, and their diseases were stable. Blister in recipient site was created by cryotherapy and in donor site by using vacuum device. Then donor site blister was transferred to the recipient site and both sites were covered by dressing.

**Results:** 10 patients (8 females & 2 males) with mean age of  $31.2 \pm 11.4$  years entered the study. After 1-6 weeks, first signs of repigmentation were observed and after 4 months complete repigmentation occurred in 7 patients (70%) In two patients, a repigmentation of more than 50% was observed while in one patient no pigmentation was seen which was related to errors in surgical technique.

**Conclusion:** Blister grafting surgery in limited patches of vitiligo which have not responded to medical treatments gives excellent results of prolonged repigmentation without any scar formation. (*Iran J Dermatol 2008;11: 55-59*)

**Keywords:** vitiligo, blister graft, repigmentation

## Introduction

Vitiligo is an acquired idiopathic condition characterized by focal regions of depigmentation resulting from absence of active melanocytes.

Disease can affect all parts of the body and depigmented patches can demonstrate different sizes and shapes. Vitiligo may induce grater psychological problems for the patients<sup>1</sup>.

Among surgical procedures used for the management of vitiligo patients is suction blister grafting technique that is used for stable patches.

The aim of this method is to transfer active melanocytes to depigmented region through blister induction and separation of epidermis and transferring it to the vitiligo region. To induce blister in donor site and in recipient site vacuum suction device and cryo with liquid nitrogen is used, respectively<sup>2,3</sup>.

In a few days melanocytes penetrate into the depigmented area and start to produce pigments. Pigment complementation of the region and color homogenization with surrounding skin takes place within months and in this way, inactive melanocytes

are replaced by active melanocytes and definite treatment is yielded. Considering that suction blister graft has a grate impact in complete remedy of depigmented lesions, we decided to evaluate the efficacy of this method in vitiligo patients who had received topical treatments and phototherapy (PUVA) for a long time without appropriate response.

## Patients & Methods

In this study 10 vitiligo patients who were in a stable state of disease and had received different medical treatments including phototherapy (PUVA therapy) were selected. Patients younger than 20 years of age (due to the pain during the surgical procedure) and those whose disease was in an unstable condition were excluded from the study.

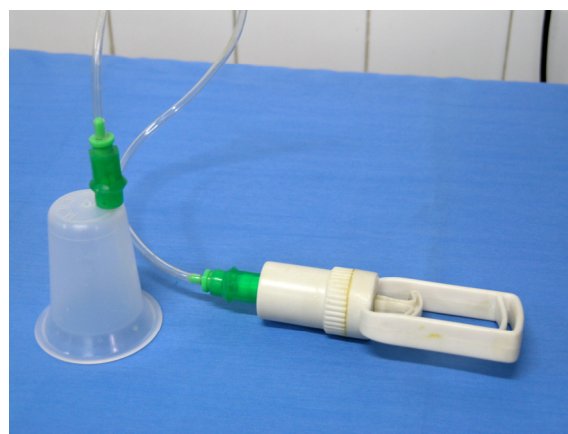It is important to determine vitiligo stability. Stable vitiligo is a condition in which neither depigmentation, enlargement, new lesions nor koebner phenomenon is identified in a certain time period<sup>4</sup>. There is no fixed agreement about this limit. The cases suggest 3 months to 2 years<sup>5-7</sup>.

The method of blister induction in the recipient site was as follows: the day before surgery, relatively intense cryotherapy was done in the recipient site affected by vitiligo. Cryotherapy was performed with liquid nitrogen and cotton swab through two cycles of 15-20 seconds with 20 second intervals.

For blister induction in donor sites, we used a vacuum device named Yuexiao which is made in China for relieving muscle and joint pain (figure 1).

Method of blister induction in the donor site was so that on the day of surgery, after selecting the donor site which was the medial aspect of the thigh (on the condition that no macule or patch of vitiligo exists in the site) clearing with povidon- iodine and then normal saline was performed and after local anesthesia, the site was attached to the vacuum device and the patient was recommended to pull the device piston regularly to produce high negative pressure. Because of the pain during suction, diazepam was administered intramuscularly (5-10mg stat) for some patients, but in spite of diazepam and local anesthesia which was introduced several times, patients still suffered some degrees of pain. After about 3-5 hours, the blister was ready and was taken by scalpel or scissor and was put in a normal saline containing dish and the donor site was dressed with antibiotic ointment and vaseline gauze. While dressing the donor site, another person took the blister of the recipient site. Occasionally after taking the roof of blister, a thin translucent layer may present which should be taken carefully.

When the recipient site got ready, graft was placed in the site and sutured with 6/0 nylon and then antibiotic ointment and vaseline gauze was put on it. To prevent disposition of the graft wet sterile



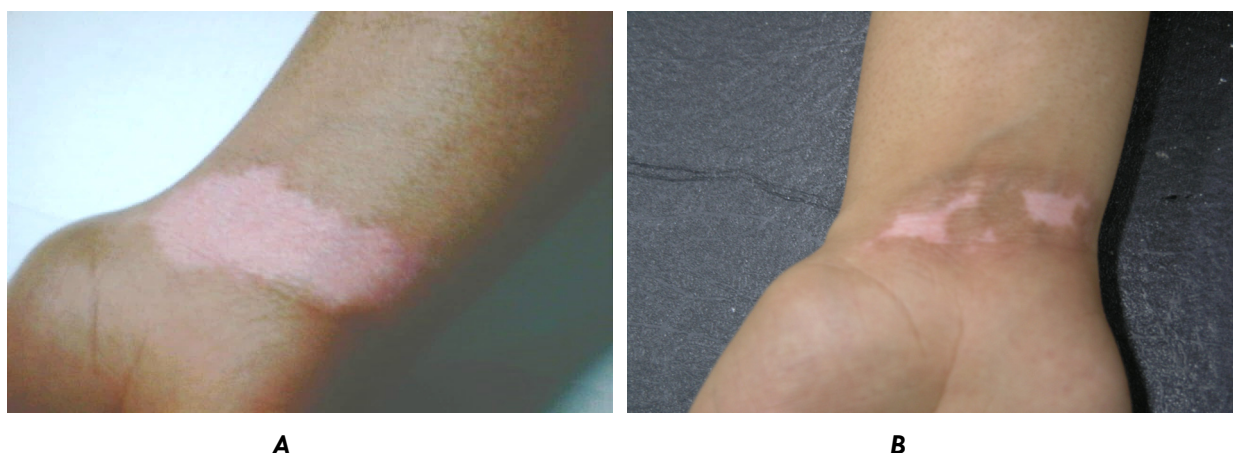
**Figure 1:** Vacuum device

cotton was applied and then with sterile gauze and compressive bandage, dressing of recipient site was performed to prevent any extra movement of the graft.

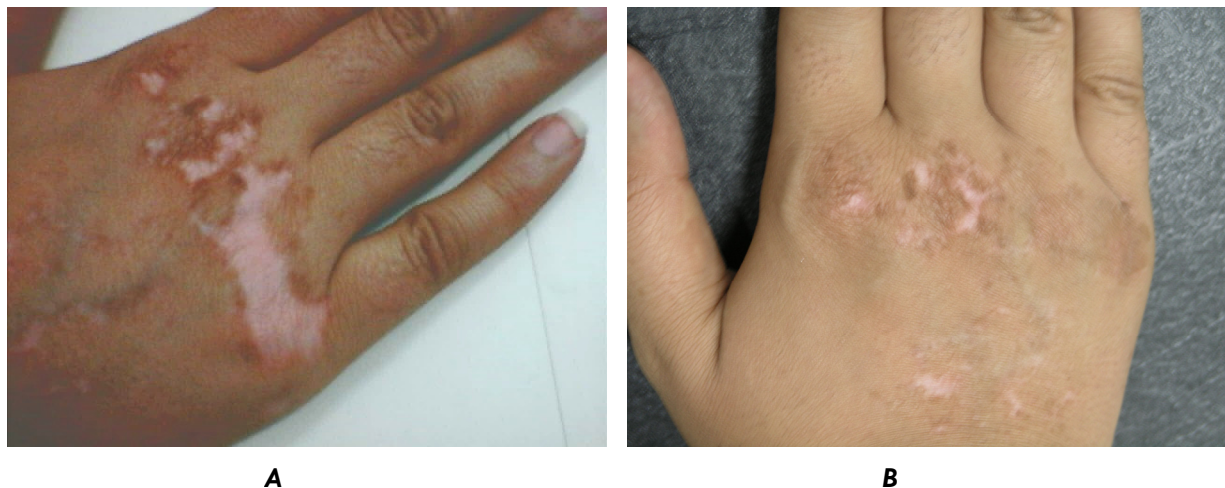After surgery, a course of antibiotic (cephalexin 500mg P.O. QID) for seven days was given and the patient was recommended to keep the site immobile for a week. Dressing was changed after a week and sutures were removed after 2 weeks. Scaling of the site was observed after 2-4 weeks and phototherapy was started at this time.

## Results

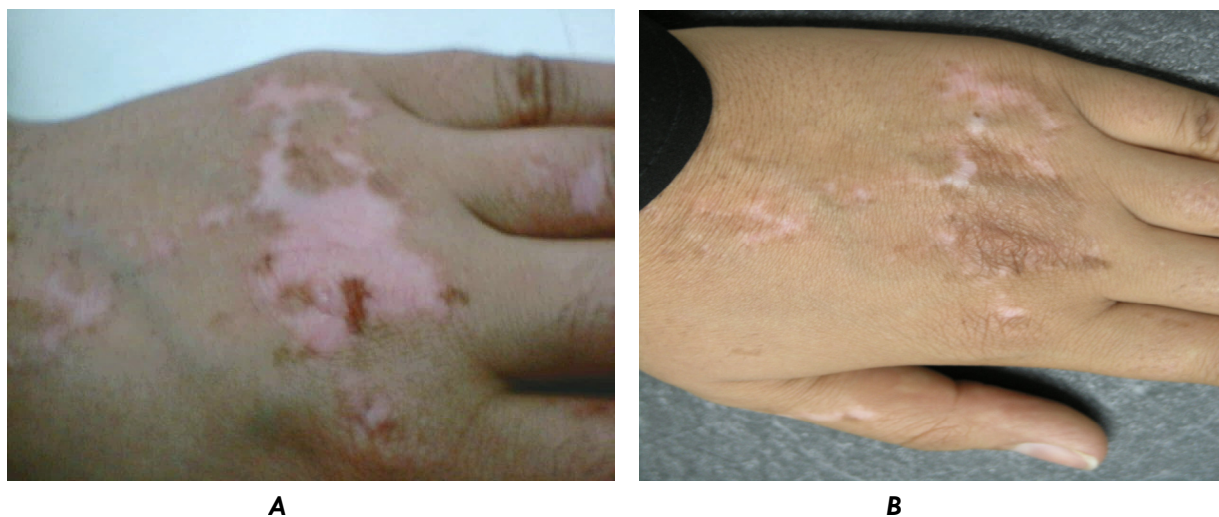
10 patients (8 females and 2 males) were included in this study with a mean age of  $31.2 \pm 11.4$  years. First signs of pigmentation appeared after 2-4 weeks in the grafted site and ultimately in 9 patients (90%) between 50-100% pigmentation appeared among whom 2 patients showed more than 50% repigmentation (figure 2) and 7 had complete (90-100%) repigmentation (figures 3,4) . In one patient, no pigmentation was



**Figure 2:** Patient No 1, a 28-year-old female with a vitiligo patch on the wrist; A: patient before surgery, B: Same patient two months after blister graft surgery (more than 50% repigmentation).



**Figure 3:** Patient No 2, a 27-year-old female patient with vitiligo over the dorsum of her right hand; A: patient before surgery, B: Same patient 2.5 months after blister graft surgery (complete repigmentation).



**Figure 4:** Patient No 3, a 35-year-old female patient with vitiligo over the dorsum of her left hand; A: patient before surgery, B: same patient 2 months after blister graft surgery (complete repigmentation).

observed which was related to errors in surgical technique. In all patients, pigmentation progressed beyond the graft margins but regressed to the graft boundaries in 20% of the patients following treatment cessation. Regression did not occur in the grafting site in any of the patients.

## Discussion

Vitiligo is a fairly common pigmentary disorder of skin resulting from a loss of melanin which causes depigmented skin, mucous membrane, eyes and sometimes hair bulbs, the cause of melanocyte destruction has remained unclear<sup>8</sup> but several theories have tried to explain the pathogenesis of vitiligo, such as autoimmunity<sup>9</sup>, self destructing

mechanisms<sup>10</sup>, neurals<sup>11</sup>, biochemical<sup>12</sup>, an imbalance of epidermal cytokines<sup>13</sup>, and genetic factors<sup>14</sup>.

The prevalence of the disease has been reported between 0.3% to 2 %<sup>15</sup>.

Vitiligo is not a life-threatening disease; however, it frequently induces emotional distress<sup>16</sup>.

A number of therapeutic options for repigmentation of vitiligo are available. Yet they commonly show unsatisfying outcomes<sup>17</sup>. Systemic or local administration of psoralen combined with UVA (PUVA) or topical corticosteroids are currently widely used<sup>18</sup>. The success rate of PUVA treatment is relatively good but recurrence after discontinuation is frequent.

Among the treatment methods for vitiligo are surgical procedures in which active melanocytes are transferred to the affected site.

Surgical treatments are satisfactory when they are tried on patients with a stable type of vitiligo, which is unresponsive to conventional therapies<sup>18-20</sup>. Njoo et al. recommended a surgical technique as first – line treatment of segmental vitiligo and vitiligo involving lips and finger tips<sup>21</sup>.

Considering the responsiveness to therapy, segmental and generalized vitiligo respond positively to surgical treatment when in a stable condition<sup>5</sup>.

The site of lesions also determines the degree of success of surgical treatment. For instance, the success rates of vitiligo treatments on finger and elbow are considerably lower than those on other sites<sup>22</sup>. Besides, the patient's motivation is also an important factor to be considered<sup>23</sup>.

There are various replenishment methods of melanocyte transplantation such as suction blister grafting (SBG), minigrafting (punch grafting), follicular grafting (FG), and cultured melanocyte transplantation<sup>24</sup>.

In systemic reviews by Njoo et al. on autologous transplantation methods, a success rate of 90% was reported in suction blister grafting technique<sup>21</sup>.

In other studies, time of blister induction is 2 hours but in the present study this time was 3-5 hours which is related to more equipped devices used in their studies.

Blister formation takes more time and is difficult to perform when the patients are young individuals. The weak dermoepidermal adherence found in aged persons makes the separation easier and faster.

Some techniques can reduce the time required for blister formation, such as intradermal injection of normal saline, application of heat, increasing negative pressure by 100 mmHg when small vesicles appear, and choosing the donor skin that overlies major trochanter<sup>25</sup>. In order to obtain more melanocytes from the epidermal sheet of blister roof, donor sites can be prepared using PUVA which was practiced in our study.

Local anesthesia in the donor area reduces the pain while creating the blister<sup>26</sup> but in our study despite the use of local anesthesia and diazepam administration patients experienced some levels of pain.

The disadvantages of the SBG method is as follows: it is not suitable for large areas, folded areas, palms and soles. It is time – consuming and

requires specific attention, as epidermal grafting is very easy to tear and to roll up.

This method offers a number of advantages: it shows excellent cosmetic results, which is appropriate for segmental vitiligo and vitiligo on the face and lip areas.

Other benefits include no stuck –on effect, no depigmentation, and no scarring on donor areas. The SBG technique has proved to be relatively safe, inexpensive, and not difficult. More importantly, it offers a high mean success rate<sup>6</sup>.

Considering the pain accompanying suction blister graft technique and the relatively long time needed for the procedure at present, research and finding methods to reduce pain and shorten the time required for blister induction could be valuable. In our study, 70% of patients achieved complete pigmentation and 20% showed pigmentation of more than 50% while one case was without any pigmentation as a result of inappropriate technique, so it seems that suction blister grafting technique, in case of suitable patient selection and meticulous surgical technique, is a very good method for the treatment of stable and localized or segmental vitiligo.

## Acknowledgment

The authors thank Dr. Mousa Mirshekar and Dr. Masoud Dadkhah for their assistance in surgical technique improvement.

## References

1. James WD, Berger TG, Elston DM (eds). *Andrews diseases of the skin*. Philadelphia: Saunders Elsevier ; 2006:860-63.
2. Falabella R. Repigmentation of leukoderma by autologous epidermal grafting . *J Dermatol Surg Oncol* 1984;10:136-44.
3. Falabella R. Grafting and transplantation of melanocytes for repigmentation vitiligo . *Int J Dermatol* 1989;28:363-69.
4. Mutalik S, Ginzburg A. Surgical management of stable vitiligo : a review with personal experience . *Dermatol Surg* 2000; 26:248-54.
5. Kim HY, Kang KY. Epidermal grafts for treatment of stable and progressive vitiligo . *J Am Acad Dermatol* 1999; 41:412-17.
6. Boersma BR, Westerhof W, Bos JD. Repigmentation in vitiligo vulgaris by autologous minigrafting : result in nineteen patients . *J Am Acad Dermatol* 1995; 33:990-95.
7. Hann SK, Im S, Bong HW, et al. Treatment of stable vitiligo with autologous epidermal grafting and PUVA. *J Am Acad Dermatol* 1995;32:943-48.

8. Drake LA, Dinehart SM, Farmer ER, et al. Guidelines of care for vitiligo. *J Am Acad Dermatol* 1996; 35:620-26.
9. Ongenat K, Van Geel K, Naeyert J-M. Evidence for autoimmune pathogenesis of vitiligo. *Pigment Cell Res* 2003; 16:1-11.
10. Yee C, Thompson JA, Roche P, et al. Melanocyte destruction after antigen – specific immunotherapy of melanoma: direct evidence of cell-mediated vitiligo. *J Exp Med* 2000; 192:1637-43.
11. Taneja A. Treatment of vitiligo. *J Dermatolog Treatment* 2002; 13:19-25.
12. Schallreuter KU, Wood JM, Pittelkow MR, et al. Regulation of melanin biosynthesis in the human epidermis by tetrahydrobiopterin. *Science* 1994; 263:1444-46.
13. Moretti S, Spallanzani A, Amato L, et al. New insight into pathogenesis of vitiligo: imbalance of epidermal cytokines at sites of lesions. *Pigment Cell Res* 2002; 15:87-82.
14. Kim SM, Chung HS, Hann SK. The genetics of vitiligo in Korean patients. *Int J Dermatol* 1998; 38:908-10.
15. Boisseau-Garsaud AM, Garsaud P, Cales-Quist D, et al. Epidemiology of vitiligo in the French west Indies (Isle of Martinique). *Int J Dermatol* 2000; 39:18-20.
16. Kovacs SO. Vitiligo. *J Am Acad Dermatol* 1998; 38:647-60.
17. Geel NV, Ogenat K, De Mil M, et al. Modified technique of autologous noncultured epidermal cell transplantation for repigmenting vitiligo: a pilot study. *Dermatol Surg* 2001; 27:873-76.
18. Ozdemir M, Centikale O, Wolf R, et al. Comparison of two surgical approaches for treating vitiligo: a preliminary study. *Int J Dermatol* 2002; 41:135-38.
19. Falabella R, Arrunategui A, Barona MI, et al. The minigrafting test for vitiligo: detection of stable lesions for melanocyte transplantation. *J Am Acad Dermatol* 1995; 32:228-32.
20. Kahn AM, Cohen MJ. Vitiligo: treatment by dermabrasion and epithelial sheet grafting. *J Am Acad Dermatol* 1995; 33:646-48.
21. Njoo MD, Westehof W, Bos D, et al. The development of guidelines for the treatment of vitiligo. *Arch Dermatol* 1999; 135:1514-21.
22. Lontz W, Olsson MJ, Moellmann G, et al. Pigment cell transplantation for treatment of vitiligo: a progress report. *J Am Acad Dermatol* 1994; 30:591-97.
23. Njoo MD, Bossuyt PMM, Westerhof W. Management of vitiligo: result of questionnaire among dermatologist in the Netherlands. *Int J Dermatol* 1999; 38:866-72.
24. Andreassi L, Pianigiani E, Andreassi A, et al. A new model of epidermal culture for surgical treatment of vitiligo. *Int J Dermatol* 1998; 37:595-98.
25. Gupta S, Shroff S. Modified technique of suction blistering for epidermal grafting in vitiligo. *Int J Dermatol* 1999; 38:306-09.
26. Gupta S, Kumar B. Epidermal grafting for vitiligo in adolescents. *Pediatric Dermatol* 2002; 19:159-62.