

Unusual Presentation of Granuloma Annulare in Periocular Area

Sima Rassai, MD
 Mohammad Radmanesh,
 MD

Department of Dermatology, Ahvaz
 Jondishapour Medical Sciences
 University, Ahvaz, Iran

Corresponding author:
 Sima Rassai, MD
 Imam Khomeini Hospital
 Ahvaz, Iran
 Email: Rassai_s@yahoo.com

Received: October 30, 2008
 Accepted: November 10, 2008

Abstract

Granuloma annulare is a benign, relatively common dermatosis of childhood and young adults. Lesions typically occur on the extremities. Localized facial and periocular involvement is rare. We describe a 25-year-old woman with asymptomatic skin-color, firm, and papular lesions on both periocular areas since 6 months ago. Histological examination revealed palisading necrobiotic granuloma, characterized by an acellular central area containing mucin surrounded by palisading histiocytes, suggestive of granuloma annulare. Granuloma annulare should be considered for any acquired papular lesions of the periocular area at any age to avoid multiple surgical excisions at a later stage of life. (*Iran J Dermatol* 2008;11: 168-170)

Keywords: granuloma annulare, eye, triamcinolone

Introduction

Granuloma annulare (GA) is a benign idiopathic dermatosis which primarily affects children and young adults.¹ It is clinically presented as papules, nodules or plaques in a discrete, or even more commonly, in a circular arrangement. They usually occur on the dorsum of hands or feet and less commonly on the arms, legs or trunk, and rarely on the face and scalp. It is very rarely reported in the periocular region.¹⁻³

Case Report

A 25-year-old woman was referred to our clinic with a few asymptomatic papules on the upper and lower eyelids which had been present for about 5-6 months.

Physical examination revealed a few 3-5 mm skin-colored dermal papules located in the upper and lower eyelids (Figures 1, 2). The papules were non-tender, firm and mobile. There were no overlying skin color changes. Simultaneously there were several non-tender, erythematous plaques near the right Achilles tendon (Figure 3).

Histopathologic study of the eyelid's papule showed well-defined area of necrobiosis in the dermis surrounded by fibroblasts and lymphohistiocytic infiltrates in a palisading pattern, suggestive of granuloma annulare (Figures 4,5).

Complete blood cell count, fasting blood sugar, two-hour glucose tolerance-test and chest

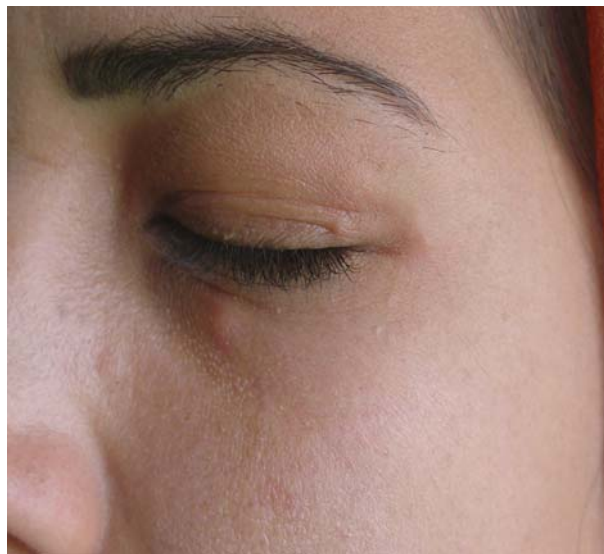

Fig 1: Upper and lower eyelid involvement

roentogram were normal. The patient herself had no remarkable past medical history but her mother had hyperlipidemia. The treated periocular papules were treated with intralesional triamcinolone acetonide with a concentration of 5-10 mg per ml on two separate occasions over two weeks intervals. For the plaques over the achilles tendon combined intralesional triamcinolone acetonide and cryotherapy was performed. Both areas improved with no recurrence after a two year follow-up (Figures 6,7).

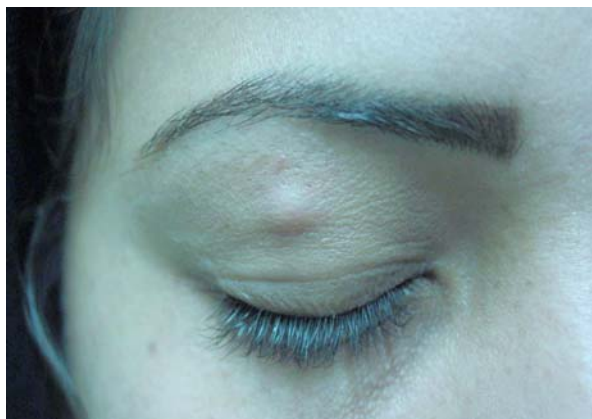

Fig 2: Upper eyelid involvement

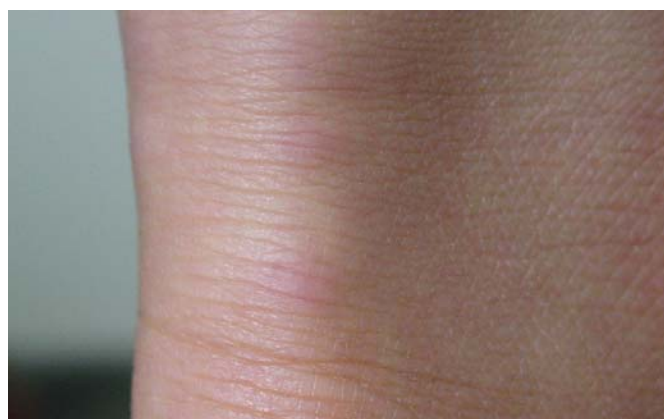

Fig 3: Achilles tendon involvement

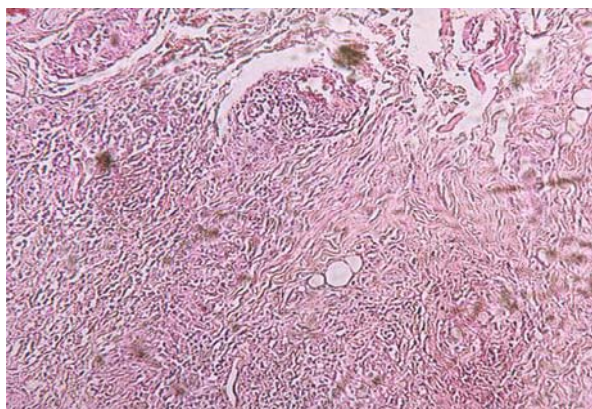


Fig 4: Granuloma annulare histopathologic findings (H&E staining with 100× magnification)

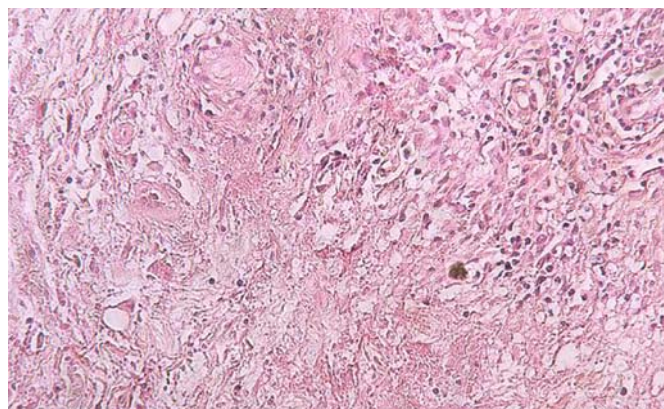


Fig 5: Granuloma annulare histopathologic findings (H&E staining with 200× magnification)

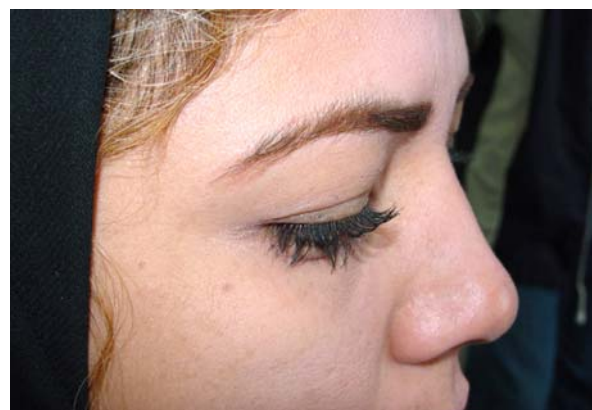

Fig 6: Improvement after treatment

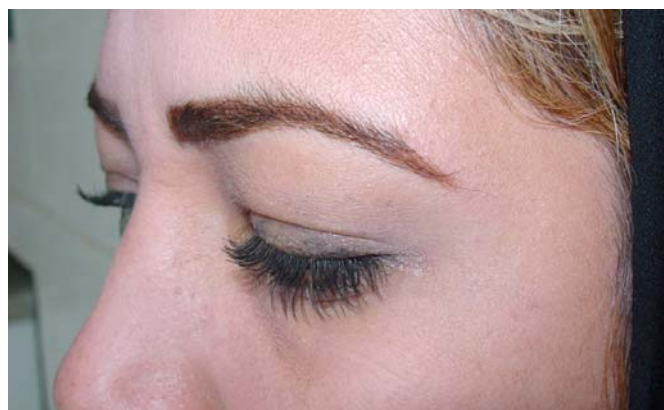

Fig 7: Improvement after treatment

Discussion

GA may clinically be observed as annular plaques, nodules or plaques in a localized or disseminated pattern. The plaque type is the most common form.¹ Subcutaneous GA is a variant of Granuloma Annulare that occurs either as a single or multiple lesions. The lateral aspect of the eyelid and the lateral canthus are sites of predilection for

periocular involvement. These lesions occur mainly during childhood and only rarely in adults.⁴

Periorbital GA has been rarely reported in dermatology and ophthalmology literature⁵⁻⁹ as solitary and occasionally multiple nodules.⁴

Typically GA is a self-limiting entity that may regress spontaneously.¹

Local steroid injection, psoralen and ultra violet light (PUVA) therapy and cryotherapy have been used with some success in refractory cases.¹ Our patient presented with an unusual periocular papular form and responded well to intralesional steroid.

References

1. Goldstein SM, Douglas RS, Binenbaum G, Katowitz JA. Paediatric periocular granuloma annulare. *Acta Ophthalmologica Scandinavica* 2003; 81:90-1.
2. McFarland JP, Kauh YC, Luscombe HA. Periorbital granuloma annulare. *Arch Dermatol* 1982; 118: 190-1.
3. McNeal S, Dawjl JR. Subcutaneous granuloma annulare: an unusual presentation in the eyelids and scalp. *Ann Plast Surg* 2005; 55: 648-6.
4. Ferry AP. Subcutaneous granuloma annulare ("pseudorheumatoid nodule") of the eyebrow. *J Pediatr Ophthalmol* 1977; 14:154-7.
5. Sanchez Tocino H, Galindo Ferrero A, Galindo Alonso J, et al. Granuloma annulare of the eyelid: an unusual presentation. *Arch Soc Esp Ophthalmol* 2004; 79: 397-400.
6. Ramaesh K, Bhagat S, Wharton SB, Singh J. Orbital nodular granuloma annulare in a juvenile diabetic. *Eye* 2002; 16: 670-3.
7. Cronquist SD, Stashower ME, Benson PM. Deep dermal granuloma annulare presenting as eyelid tumor in a child, with review of pediatric eyelid lesions. *Pediatr Dermatol* 1999; 16: 377-80.
8. Lawton AW, Karesh JW. Periocular granuloma annulare. *Surv Ophthalmol* 1985; 31:285-90.
9. Wojno T, Tenzle RR, Thomas M. Granuloma annulare of the eyelid. *Ann Ophthalmol* 1985; 17: 73-5.