

# Lipedematous Scalp: A Case Report

Hossein Shabanzadeh-Dehkordi, MD<sup>1</sup>  
Amir Farhad Kamkhah, MD<sup>2</sup>

1-Department of Dermatology  
2-Department of Pathology  
Shahrekord University of Medical Sciences,  
Shahrekord, Iran

*Corresponding author:*  
Hossein Shabanzadeh – Dehkordi, MD  
Shahrekord University of Medical Sciences,  
Shahrekord, Iran  
Email: dehkordi@yahoo.com

Received: May 26, 2008  
Accepted: October 6, 2008

## Abstract

Lipedematous scalp (LS) and Lipedematous Alopecia (LA) are uncommon disorders of unknown etiology, pathogenesis and treatment. They are characterized by thickening of the subcutaneous layer of the scalp and a boggy scalp on palpation. Also, hair loss or shortening of hair is seen in LA. In this report, we describe LS in a 42-year-old woman presented with a diffuse thickened and spongy scalp. To date, only 10 cases of LS and 18 cases of LA have been reported and we report the 11th case of LS but it seems to be more prevalent than reported. (*Iran J Dermatol* 2009;12: 26-30)

**Keywords:** alopecia, lipedematous, scalp

## Introduction

Lipedematous scalp (LS) and Lipedematous Alopecia (LA) are two uncommon disorders, which have been clinically characterized by thickening of the subcutaneous layer of the scalp and a boggy scalp on palpation. While there is no hair abnormality in LS, shortening of hair and hair loss are observed in the thickened part of the scalp in LA. Nevertheless, the etiology and pathogenesis of both disorders are unknown and no approved association with any other diseases is reported.

LS was first described by Cornbleet in 1935. The patient was a 44-year-old black woman who had complaints about thickening and softening of her scalp which felt like a cotton<sup>1</sup>. A few years later, Lee et al. reported the second case in a Korean woman<sup>2</sup>. Since then, ten cases, all in females, have been reported (Table 1).

In 1965 and for the first time, Coskey et al. introduce LA as a new term to describe the disorders observed in two black females aged 28 and 75 who were examined for the shortening of hair and thickening of the subcutaneous layer of the scalp<sup>3</sup>. So far, the total reported number of LA cases is 18, out of whom 14 cases were females and 4 cases were males. Considering the fact that the main pathology observed in both disorders are obvious increase in the diameter of the lipid tissue,

it is most probable that LS and LA are the same or two manifestations of one disease.

## Case Report

The patient was a 42-year-old woman who was visited for the softening of scalp and a continuous headache. The problem had started two years ago with a headache which became worse and continued for a longer period each time. Gradually, the vertex became soft and thickened. Even though she had been examined by different physicians, her problem was gradually aggravated and she had complaints about headaches all over her head as well as a feeling of pain and stiffness in her neck when visited. She had no history of taking medications, underlying systemic diseases or head trauma (Figure 1).

Considering the patient's age, hair density was normal and no apparent abnormality was seen. The appearance of the scalp skin seemed normal. When pressing the scalp down, it felt spongy and soft and became depressed but returned to the same level after the pressure was removed. The patient had tenderness and a severe pain during the examination. The spongy feeling was observed in the whole scalp but in the margins of the hair growth. The patient had no family history for such diseases and her children were normal. Blood biochemical analysis was normal.

**Table 1:** Reported cases of *Lipematous scalp (LS)* and *Lipematous Alopecia (LA)*

Author, year	Age, sex, race	Duration	Association	Scalp thickness
<b>Lipematous scalp</b>				
Cornbleet, 1935	44,F,B	6 years	-	-
Lee, 1994	32,F,A	3 years	-	10.7
Scheufler, 2003	51,F,W	5 years	Fever, headache, Syncopal attacks	15 mm
Bukhari, 2004	51,F,A	6 months	Hypercholesterolemia, Supraventricular tachycardia	19.2 mm
Martin, 2005	48,F,W	2 months		10.8 mm
High, 2005	55,F,B	?	DLE	10-15
Darion, 2006	10,F,A	6 months	Asthma, headache	9.8 mm
Yasar, 2007	62,F,W	50 years	positive family history	18 mm
Mansur, 2007	46,F,W		Nevus lipomatosus	13 mm
Kavak, 2008	50,F,W		Hypertension	10.8 mm
Shabanzadeh, 2008	42,F,A	2 years	Headache, scalp tenderness, Neck stiffness	17 mm
<b>Lipematous alopecia</b>				
Coskey, 1961	28,F,B	2 years		15 mm
	75,F,B	1 years	Diabetes mellitus	10 mm
Curtis, 1964	62,F,B	15 years	Skin and joint hyperelasticity	15 mm
Kane, 1998	49,F,B	4 months		12.6 mm
Fair, 2000	18 F,B		Renal insufficiency	9 mm
Ikejima, 2000	30,M,A	7 years		16 mm
Tiscornia, 2002	69,F,W	6 months		10 mm
Mohsin <sup>21</sup> , 2004	?, F,W			
Martin, 2005	77,F,W	1 years		11 mm
	59,F,W	1 years	Sjogrens syndrome	9.2 mm
High, 2005	57,F,B	10 years	DLE	12-15 mm
Piraccini, 2006	48,M,W	10 years	Androgenetic alopecia	11 mm
	53,M,W	4 year		12 mm
Yasar, 2007	45,F,W	1 years		10 mm
	49,M,W	4 months		12 mm
Moravvej, 2007	45,F,A	5 years	Freckles, café-au-lait spots	10.7 mm
Yip <sup>22</sup> , 2008	67,F,W	10 year		?

A:asian B: black F: female M: male W: white

Biopsy of the scalp showed normal epidermis, the diameter of dermis was obviously reduced while the diameter of lipid layer had extremely increased and as a result had reached the limit of superficial dermis. Mucin deposition was not observed by Alcian blue staining. Hair follicles and Adnexes were normal (Figure2).

Considering the patient's complaints i.e. headaches and neck stiffness and pain, she was referred to consult a neurologist and a neurosurgeon. CT scan and MRI were normal. Obstruction and CSF leakage, as possible causes of headaches and scalp swelling, were ruled out.

The maximum thickness of scalp measured by MRI was 17 mm which was observed in the vertex area. The thickness of other parts was slightly less (Figure3,4).

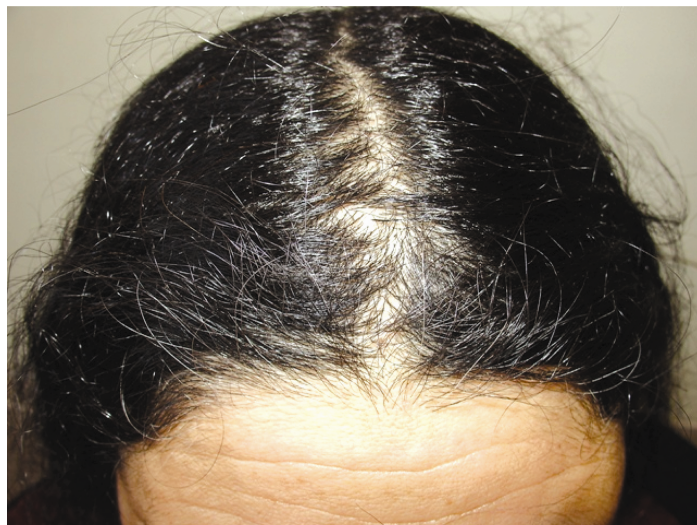## Discussion

LS is an uncommon disorder which is mainly characterized by spongy swelling and increase of

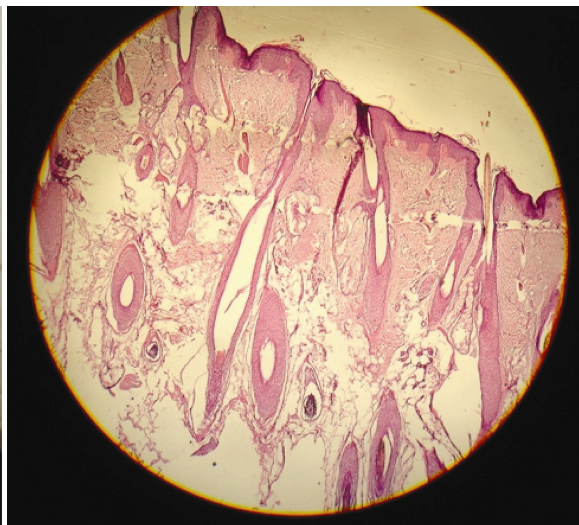
the scalp thickness without any noticeable hair loss. When hair loss is included, the term LA is applied<sup>4</sup>. Most of the cases reported so far are black women, although reports of men and white patients are increasing. As a consequence, the previous opinion about these disorders being limited to a specific race is now questionable. Nevertheless, the higher number of female patients could be related to the role of female hormones in the pathogenesis of the disease.

The thickness of scalp is naturally 5-6 mm<sup>5</sup>. For the cases reported so far, the thickness is ranging between 10 to 18 mm measured with different methods including a needle introduced into the scalp, ultrasonography, MRI and CT scan which is about 2-3 times more than the normal range. For the case reported in this article, the scalp thickness measured by MRI was 17 mm which is 3 times more than normal.

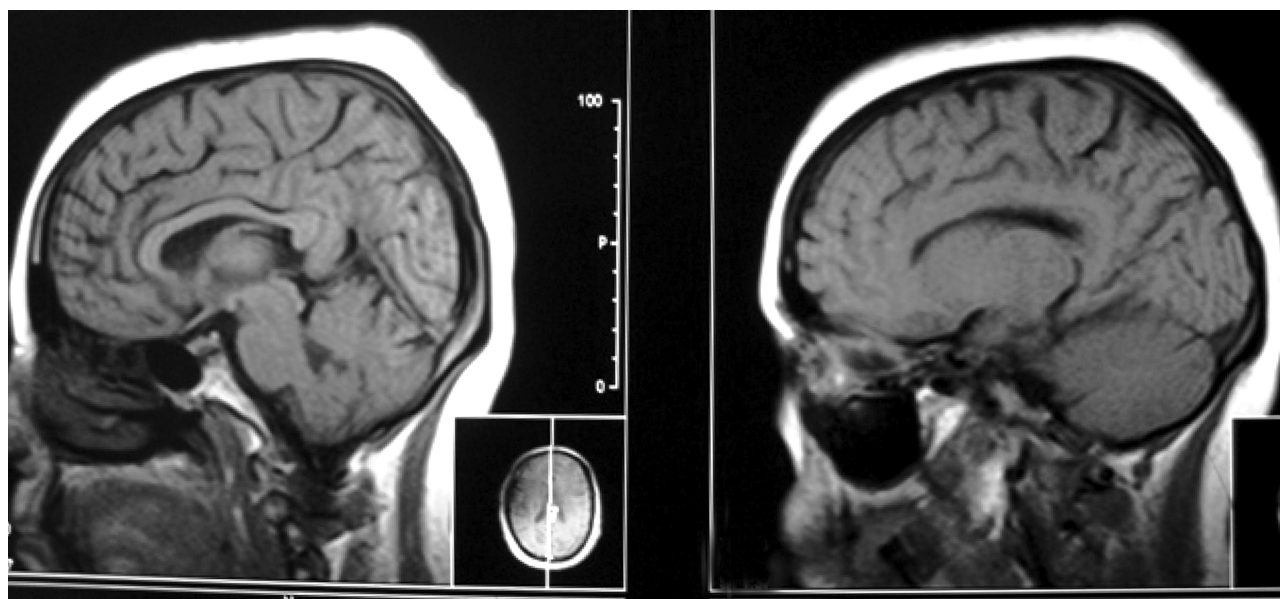
To date, it is not known if the movement of the lipid tissue toward the skin surface is compensatory



**Figure 1:** Clinical manifestations of lipedematous alopecia: boggy scalp without hair loss



**Figure 2:** Histopathology view; the diameter of dermis was obviously reduced while the diameter of lipid layer had extremely increased(H&E\*10)



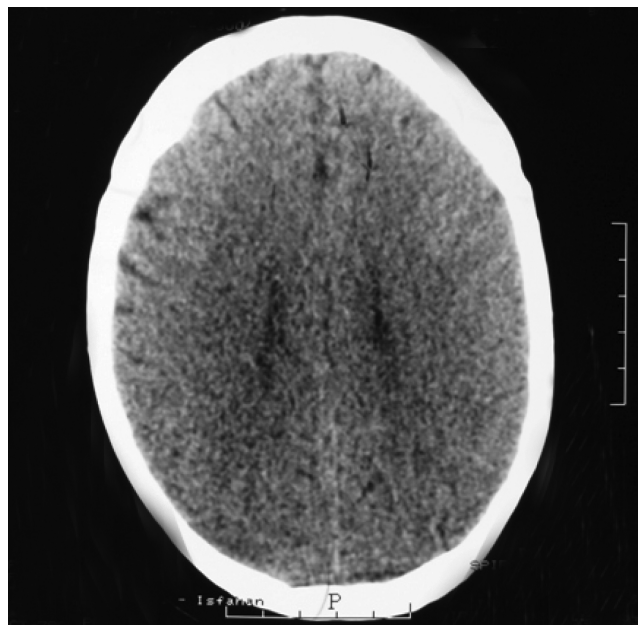
**Figure 3:** MRI imaging demonstrated no abnormality in brain and thickness of scalp measured as 17 mm

or reactive. The important pathology in a report by Fair et al. is demonstrated to be lipid tissue edema together with disruption and degeneration of lipid tissue without hypertrophy<sup>6</sup>. Martin, Moravvej and Tiscornia observed dilated lymphatic vessels<sup>7,8,9</sup>. Since lymphangiectasia is only reported in patients with LA it could be the cause of hair loss seen in such patients. The thickening of lipid tissue and its hyperplasia have also been reported in some cases<sup>7,9,10</sup>. Coskey reported free-floating lipid

droplets in subcutaneous layer. Mucin deposition in superficial dermis was observed in one case<sup>11</sup>. Linear telangiectasia is also described through dermoscopy<sup>12</sup>.

In some cases, scalp thickening is localized while it is widespread in others. In our patient, all hair-bearing areas of the scalp were asymmetrically thickened.

So far, four male patients have been reported. This indicates the effect of X chromosome or



**Figure 4:** CT-scan amaging: thickening of the scalp is prominent

female hormones on the etiology of the disease. Meanwhile, the number of patients having different races; 9 black, 14 white and 6 Asian patients, shows that in spite of previous views, these diseases are prevalent in all races and there is no limitation to a specific race.

Concomitant diseases include diabetes mellitus<sup>3</sup>, asthma<sup>5</sup>, sjogren's syndrome<sup>7</sup>, freckles and café-au-lait on the trunk<sup>8</sup>, androgenetic alopecia<sup>12</sup>, skin hyperelasticity and joint laxity<sup>13</sup>, renal insufficiency<sup>14</sup>, nevus lipomatosus<sup>16</sup>, hyperlipidemia<sup>17</sup>, hypertension<sup>18</sup>. In one case, LA occurred in a patient with DLE after several years<sup>19</sup>.

It seems that these associations are accidental and to date, there is no evidence of any specific disease associated with LS and LA. In addition, Lipedema of the lower legs can occur in the shin, leg and buttocks (but not foot) and is painful with a histology similar to LS and LA but no concomitance has been reported yet.

The progression of LS and LA in most patients is gradually continued for a period of few years and is stabilized afterwards. It is also interesting to know that so far, in none of the reported cases of LS, hair loss has been observed in the lipedematous areas even several years after the diagnosis which shows that LS is not a precursor or an introduction to LA.

Despite the use of systemic<sup>13</sup> and intralesional steroid<sup>20</sup> for the treatment of these disorders, a

permanent and satisfactory result has not been obtained so far and the treatment is symptomatic.

## References

1. Cornbleet T. Cutis verticis gyrata? Lipoma? Arch Dermatol Syphilol 1935; 32: 688.
2. Lee JH, Sung YH, Yoon JS, Park JK. Lipedematous scalp, . Arch Dermatol 1994;130: 802-3.
3. Coskey RJ, Fosnaugh RP, Fine G. Lipedematous alopecia. Arch Dermatol 1961; 84:619-22.
4. Scheufler O, Kania NM, Heinrichs CM, Exner K. Hyperplasia of the subcutaneous adipose tissue is the primary histopathologic abnormality in lipedematous scalp. Am J Dermatopathol 2003; 25: 248-52.
5. Garn MS, Selby S, Young R. Scalp thickness and fat-loss theory of balding. Arch Dermatol Syphilol 1954, 70: 601-8.
6. Fair KP, Knoell KA, Patterson JW, Rudd RJ, Greer KE. Lipedematous alopecia: a clinicopathologic, histologic and ultrastructural study. J Cutan Pathol 2000; 27: 49-53.
7. Martín JM, Monteagudo C, Montesinos E, Guijarro J, Llombart B, Jordá E. Lipedematous scalp and lipedematous alopecia: A clinical and histologic analysis of 3 cases. J Am Acad Dermatol 2005; 52: 152-6.
8. Moravvej-farshi H, Mohtasham N. An unusual case of lipedematous alopecia. Arch Iran Med 2007; 10: 532-4.
9. Tiscornia JE, Molezzi A, Hernandez MI, Kien MC, Chouela EN. Lipedematous alopecia in a white woman. Arch Dermatol 2002; 138: 1517-8.
10. Yaşar S, Mansur AT, Göktay F, Sungurlu F, Vardar Aker F, Ozkara S. Lipedematous scalp and lipedematous alopecia: report of three cases in white adults. J Dermatol 2007; 34: 124-30.
11. Kane KS, Kwan T, Baden HP, Bigby M. Women with new-onset boggy scalp. Arch Dermatol 1998; 81: 802-3.
12. Piraccini BM, Voudouris S, Pazzaglia M, Rech G, Vicenzi C, Tosti A. Lipedematous alopecia of the scalp. Dermatol Online J 2006; 12: 6.
13. Curtis JW, Heising RA. Lipedematous alopecia associated with skin hyperelasticity. Arch Dermatol 1964; 89: 819-20.
14. Bridges AG, von Kuster LC, Estes SA. Lipedematous alopecia. Cutis 2000; 65: 199-202.
15. Rowan DM, Simpson A, Wong KP. Lipedematous scalp in a child. Pediatric Dermatol 2006; 23: 276-8.
16. Mansur AT, Yasar S, Aydingöz IE, Göktay F, Ozdemir N, Sungurlu F. Colocalization of lipedematous scalp and nevus lipomatosus superficialis: a case report. J Cutan Pathol 2007; 34: 342-5.
17. Bukhari I, Al Mulhim F, Al Hoqail R. Hyperlipidemia and lipedematous scalp. Ann Saudi Med 2004; 24: 484-5.



18. Kavak A, Yuceer D, Yildirim U, Baykal C, Sarisoy HT. Lipedematous scalp: A rare entity. *J Dermatol* 2008; 35: 102-5.
19. High WA, Hoang MP. Lipedematous alopecia: An unusual sequela of discoid lupus, or other co-conspirators at work? *J Am Acad Dermatol* 2005; 53: 157-61.
20. kejima A, Yamashita M, Ikeda S, Ogawa H. A case of lipedematous alopecia occurring in a male patient. *Dermatology* 2000; 201: 168-70.
21. Mohsin RM. Lipedematous alopecia, a rare form of diffuse hair loss (Poster abstract). *J Am Acad Dermatol* 2004; 50: p90.
22. Yip L, Mason G, Pohl M, Sinclair R. Successful surgical management of lipoedematous alopecia. *Australas J Dermatol* 2008; 49: 52-4.