

Evaluation of the Primary Response of Basal Cell Carcinoma to Aminolevulinic Acid Photodynamic Therapy

Zohreh Tehranchinia¹, MD
 Hoda Rahimi¹, MD
 Mohammad Shahidi-Dadras¹, MD
 Ali Farnaghi¹, MD
 Mahsa Seyed Ahadi², MD
 Maral Seyed Ahadi³

1. Skin Research Center, Shahid Beheshti Medical University, Tehran, Iran
 2. Townsville Hospital, Townsville, Australia.
 3. Tehran University of Medical Sciences, Tehran, Iran.

Corresponding Author:
 Zohreh Tehranchinia, MD;
 Skin Research Center, Shahid Beheshti University of Medical Sciences, Shohada-e Tajrish Hospital, Shahr-dari St, 1989934148, Tehran, Iran

Received: May 9, 2010
 Accepted: July 28, 2010

Abstract

Background: Basal Cell Carcinoma (BCC) is the most common type of skin cancer in human beings. Photodynamic therapy (PDT) is a novel therapeutic method which may be regarded as a non-invasive useful alternative for traditional treatments of BCC. This study was designed with the aim of evaluating the primary response of BCC to PDT.

Methods: This clinical trial was performed on 28 BCC lesions. Patients were treated with ALA-PDT monthly for 1-6 sessions and evaluated for clinical response, cosmetic results and probable side effects.

Results: Twenty three out of 28 lesions showed response to PDT (9 showed complete response and 14 showed partial response). The cosmetic result was excellent or good in 77.5% of the cases. In 92.8% of the cases, no or mild side effects were observed. Patients with a positive history of radiotherapy responded less ($p < 0.05$). No significant relationship was found between patients' age, sex, localization, diameter or type of BCC with clinical response.

Conclusion: PDT might be a good therapeutic option in the treatment of BCC, especially the superficial type, with high efficacy and few side effects. (*Iran J Dermatol 2010;13: 71-77*)

Key words: basal cell carcinoma, photodynamic therapy, photo chemotherapy.

Introduction

Non-melanoma skin cancers (NMSC) are the most common tumors in humans. The incidence of NMSC is continuously rising (3–8% per year). About 40–50% of the patients with a history of non-melanoma skin tumor will develop further NMSCs within 5 years¹. Basal cell carcinoma (BCC) is the most common skin cancer with significant local tissue invasion and morbidity².

For many years, simple surgical excision was the conventional treatment modality for BCC. However, as BCC usually occurs on sun-exposed areas of the body (such as the face and scalp), development of new therapeutic strategies with excellent cosmetic outcomes and minimal scar formation is of increasing interest. Furthermore, all nonsurgical approaches such as cryotherapy, radiation therapy,

excisional curettage and cautery, laser and topical cytotoxic drugs (5-fluorouracil, chemical peels, etc.) are quite nonspecific and do not target the tumor itself, thus leading to undesirable side effects in the surrounding tissue including scar formation or other cosmetically disfiguring events¹.

Photodynamic therapy (PDT) is a novel treatment modality for patients with BCC which has the advantages of being noninvasive and causing minimal damage to the surrounding tissue, because of the relatively selective uptake of photosensitizer by malignant cells^{3,4}. Furthermore, PDT could be used as a valuable alternative option in patients who are not appropriate candidates for surgical excision such as patients with large lesions⁵, patients with multiple BCCs due to previous radiotherapy, patients with residue or recurrence of

the tumor after other therapeutic modalities ⁶⁻⁸, patients who are under anticoagulant therapy ⁵, patients with Gorlin syndrome ⁹⁻¹¹, immunosuppressed or post-transplant patients ^{12,13}, diabetic patients ¹², and patients susceptible to keloid or hypertrophic scar formation ¹².

Several studies on the application of PDT in the treatment of superficial BCC have reported high but different response rates ^{5,11-13}. Furthermore, the results of PDT on nodular ^{2,5,6,14} and pigmented ⁵ BCCs have been controversial. Thus, this study was designed to evaluate the efficacy of topical PDT in the treatment of different types of BCC and the factors affecting its response rate.

Patients and Methods

This clinical trial was performed on 12 patients (8 males and 4 females) with BCC. Patients were recruited from a dermatology clinic after the clinical diagnosis of BCC was made by a dermatologist. The diagnosis was confirmed by an incisional biopsy of the lesion. In cases who had multiple lesions in the same anatomical region, a single biopsy was taken from the thickest lesion and other clinically similar lesions were treated accordingly. Patients received comprehensive information regarding the rationale, treatment protocol, and probable side effects of the photodynamic therapy and signed an informed

consent form. Patients were excluded from the study for any of the following reasons: age less than 18, history of any type of photodermatoses or dermatoses that may be aggravated by light exposure (such as porphyria, xeroderma pigmentosa, lupus, etc.), consumption of phototoxic drugs within the last 30 days, pregnancy or lactation, receiving any other treatment for the lesion within the last 6 months, rodent ulcer, morpheaform and infiltrative types as assessed clinically or histologically. In addition, antinuclear antibody (ANA) was checked in all patients before the initiation of treatment to screen for probable photosensitization susceptibility and ANA positive patients were excluded.

For patients who entered the study, topical aminolevulinic acid (ALA) in the form of 20% weight-based ALA/water-in-oil cream was applied with a thickness of approximately 1 mm on the lesion covering 1 cm of the surrounding tumor-free skin. After application of the cream, the lesion area was covered by light-proof non-adhesive dressing to prevent exposure to light. After 6-8 hours, the occlusive dressing was removed and the remaining cream was gently cleaned off and the patient received illumination from Waldmann PDT 1200 (Waldmann Medizintechnik, VS-Schwennigen, Germany) which produced a circular field of

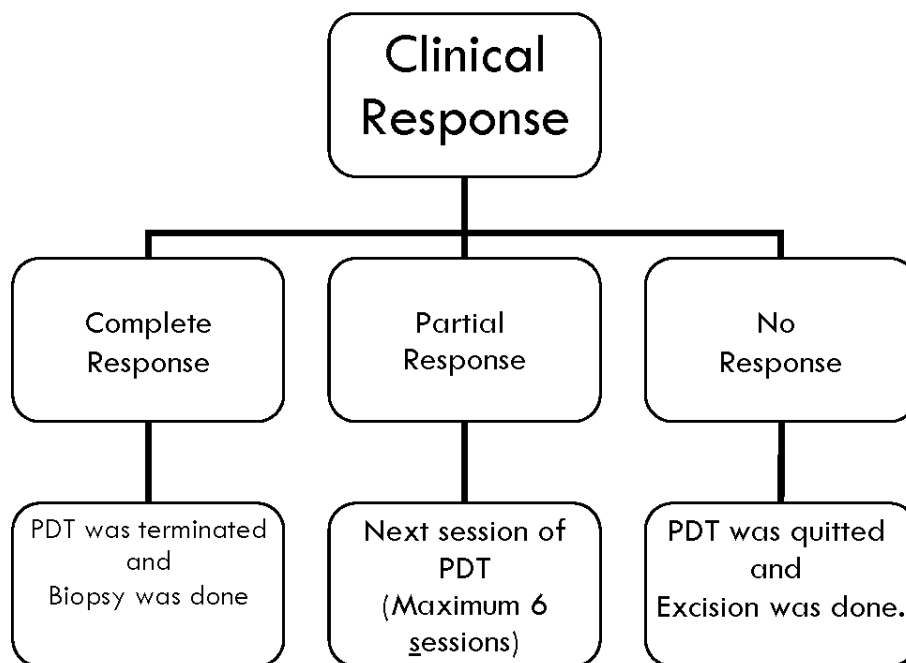


Figure 1. Treatment protocol of ALA-PDT for BCC according to clinical response

incoherent red light with a diameter of 15 cm and a wave length of 630 nm (range 600-730 nm). Each lesion was irradiated with a dose of 120 J/cm² and an intensity of 200 mW/cm². A margin of the normal skin approximately equal to the size of the lesion was included in the irradiation field. A hand-held electric fan was used close to the treatment site to reduce pain and discomfort and patients' eyes were covered with special shields during irradiation. Icepacks and zinc oxide ointments were prescribed for 24 hours after PDT to decrease post-treatment erythema and edema and the ointment administration was continued for 2 weeks. Follow-up assessment was performed by the same investigator every month. At each visit, photographs of each lesion were taken and clinical response was determined by inspection and palpation, and probable adverse effects were recorded. Clinical response was defined as Complete Response (CR) when there was no visible or palpable lesion, Partial Response (PR) when the diameter of the lesion reduced but it was still visible or palpable and No Response (NR) when the diameter of the lesion did not reduce. At each session, if the lesion showed NR, it was referred for surgical excision but if PR was detected, another treatment cycle was administered (with a maximum of 6 sessions and the

lesions which did not show complete response after 6 sessions of treatment were excised). Whenever CR was observed in a lesion, the treatment was terminated (Figure 1), and the lesion was assessed for cosmetic results on the basis of a 4-point scale; 1) excellent: no scarring, atrophy, or induration, slight or no redness or change in pigmentation compared to the adjacent skin; 2) good: no scarring, atrophy, or induration, moderate redness or increase in pigmentation compared to the adjacent skin; 3) moderate: slight to moderate scarring, atrophy, or induration; and 4) poor: extensive scarring, atrophy, or induration. At the same time, with the patient's consent, a post-treatment biopsy was performed on lesions with complete response for the purpose of serial histologic examination and confirmation of clinical assessment.

Statistical analysis

Collected data were statistically analyzed by Chi square, Fisher's exact and Kruskal-Wallis test. P- value less than 0.05 considered as significant.

Results

A total of 28 BCC lesions belonging to 12 patients (8 males and 4 females) were included in

Table 1. Evaluation of the relationship between response rate of BCC to PDT and associated factors

	Complete response n (%)	Partial response n (%)	Incomplete response n (%)
BCC type			
Superficial	4(67)	2(33)	0
Nodular	3(20)	10(67)	2 (13)
Pigmented	2 (29)	2 (29)	3 (42)
BCC localization			
Face	6(46)	6 (46)	1 (8)
Scalp	3(23)	7 (54)	3 (23)
Ear	0	1 (50)	1 (50)
Sex			
Female	5(36)	5 (36)	4 (28)
Male	4(29)	9(64)	1 (7)

BCC: basal cell carcinoma; PDT: photodynamic therapy.

Table 2. Evaluation of the relationship between response rate of BCC to PDT and history of radiotherapy ($p < 0.05$)

	Complete response n (%)	Partial response n (%)	Incomplete response n (%)
History of radiotherapy			
Positive	3(18)	9 (53)	5 (29)
Negative	6(55)	5(45)	0

BCC: basal cell carcinoma; PDT: photodynamic therapy.

our study and treated with ALA-PDT. The mean age of the patients was 59.1 years (ranging from 22 to 72 years).

From these 28 BCCs, 15 lesions were nodular, 7 pigmented and 6 lesions were superficial. Thirteen lesions were located on the face, 13 on the scalp and 2 on the ear.

The mean diameter of the BCC lesions was 20 mm in the longest axis (ranging from 2 to 100 mm). All patients completed the treatment course and 3, 4, 1, 2, and 18 lesions needed 1, 3, 4, 5, and 6

sessions of PDT, respectively. The average number of treatment sessions was 4.9 (range: 1-6). The history of radiotherapy was positive for 17 and negative for 11 lesions.

From 28 treated lesions, 23 showed response to PDT, 9 lesions showed complete response (Figure 2) and 14 lesions showed partial response (Figure 3). For three of the lesions with CR, biopsy was performed after completion of the treatment course and complete resolution of BCC was confirmed in all three cases. From 9 lesions with CR, the final

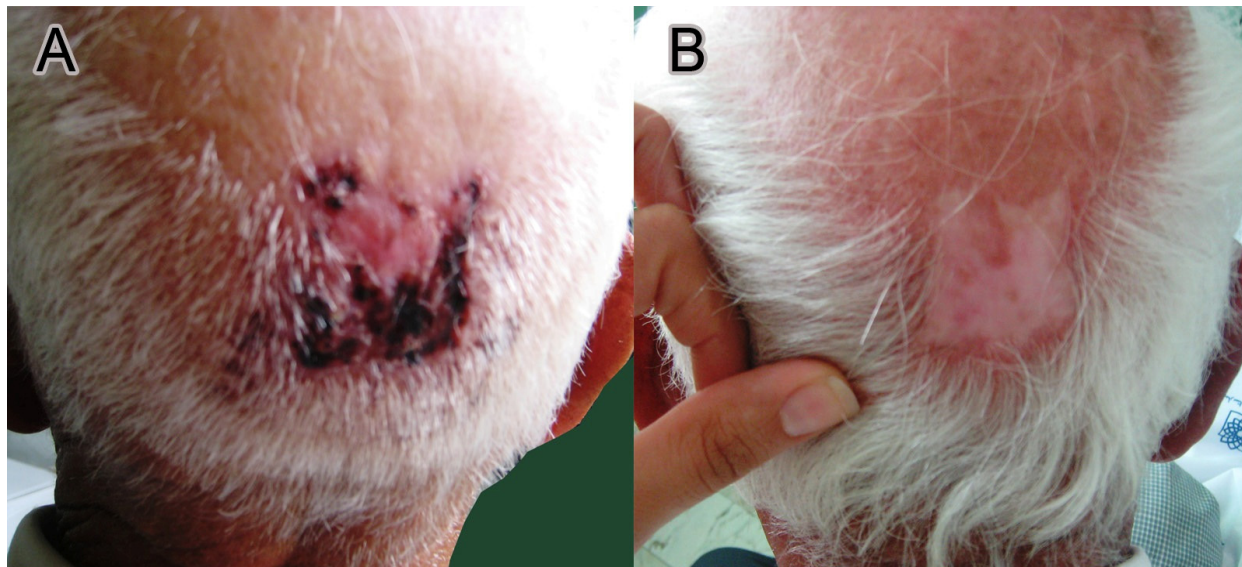


Figure 2. Basal cell carcinoma of the scalp: A) before PDT; B) with complete response after PDT

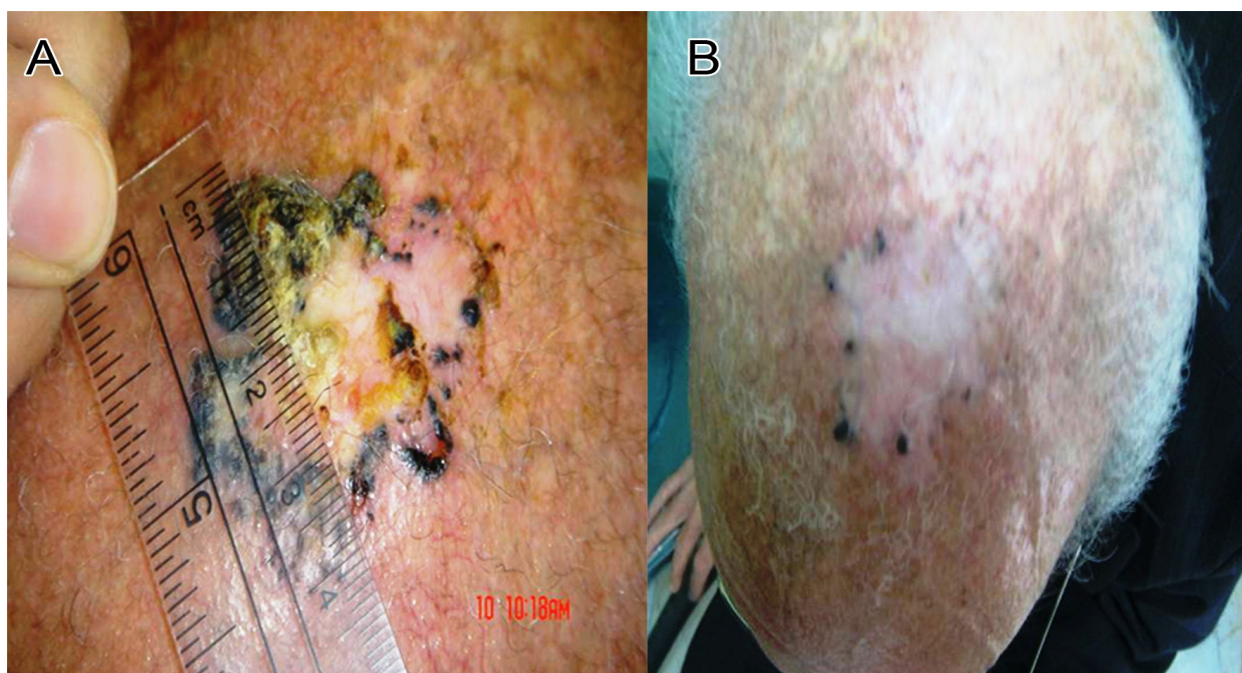


Figure 3. Pigmented BCC of the scalp: A) before PDT; B) with partial response after PDT.

cosmetic result was excellent in 5 lesions, good in 2 lesions and moderate in the remaining 2 lesions. No serious adverse events or deaths were encountered during this study. None of the patients discontinued the study as a result of an adverse effect. Only pain was reported in 11 cases which was mild in 9 and severe in 2 patients.

The mean age of the patients with CR, PR and NR was 53.6, 62.4 and 60 years, respectively. No significant relationship was found between age of patients and clinical response to PDT. The mean diameter of the lesions was 13 mm in cases with CR, 28.3 mm in those with PR and 9 mm in those with NR. No significant relationship was found between the diameter of the lesions and the response rate. Complete response was observed in 4 cases (67%) of superficial BCCs, 3 cases (20%) of nodular BCCs and 2 cases (29%) of pigmented BCCs (Table 1). Although response rate was higher in superficial BCCs, no statistically significant relationship was found between the clinical type of BCC and the response rate. Some degrees of clinical response were seen in all lesions with no previous history of radiotherapy including CR in 55% and PR in 45% of the cases. However, only 18% of the lesions with a positive history of radiotherapy showed CR (Table 2). Thus, a significant relationship was found between positive history of radiotherapy and poor response to PDT ($p < 0.05$). No significant relationship was found between patients' sex, localization of the lesions and adverse events and the response rate (Table 1).

Discussion

For superficial BCC, complete response rate has been reported to be 80-100% in different studies^{15,17}. In our study, all superficial BCCs showed some degrees of response to PDT. This response was complete in 67% and partial in 33% of our cases. This difference in efficacy could be partially attributed to enrolment of only small-sized lesions in most of the previous studies, whereas our study included several large BCCs which would have been difficult to treat by conventional methods. Similarly, Madan et al, recently reported that none of the "giant" BCCs showed complete response to PDT, and all of them required at last excision¹⁸. Furthermore, in our study, all cases with partial response showed more than 80% reduction in diameter at the end of treatment course so these lesions could be expected to achieve complete response if their treatment continued and they received more sessions of PDT.

In our trial, 29% of the pigmented BCCs (pBCCs) showed complete response to PDT. However, Pintion et al, reported no CR in any of the four pBCCs in their study¹⁵.

Treatment of nodular BCCs (nBCCs) yielded controversial results. The CR rate varies from 10% in a report by Wolf et al,¹⁹ to 94% in a report by Mosterd et al²⁰. The CR rate of nBCCs was 20% in our study. A possible explanation of these differences is that some of these studies included only a small number of cases. Furthermore, different criteria were used to evaluate complete response and different treatment schedules _regarding the duration of ALA administration before irradiation, wave length and dose of irradiation_ were applied¹⁵. Finally, in some studies, some additional strategies were used. For instance, Rhodes et al, used methyl-ALA (instead of ALA) to improve the penetration of photosensitizer into the tumor². However, in another study by Kujipers et al, no difference was found between methyl-ALA and ALA in the treatment of BCC²¹. Thompson et al, used multifiber light delivery with direct contact to tumor surface to improve the efficacy of PDT and reported a 75% complete response rate for nBCC²².

In our study, ALA-PDT was well tolerated and no adverse events were observed in most of the cases. Only two cases reported severe pain. The adverse events of PDT have been reported to be insignificant in other studies, as well. Wang et al, found that patients who received PDT for their BCCs experienced pain which was similar to cryotherapy²³.

In our study, the cosmetic outcome was graded as excellent or good in 77.5% of the cases. It was reported 79-93% in previous studies. Several studies showed that the cosmetic outcome of PDT was superior to cryotherapy^{23, 24}; Basset-Seguín reported an excellent cosmetic outcome with PDT in 60% of the cases that was similar to our results but was a better outcome compared to cryotherapy (16% excellent)²⁵. In our study, the cosmetic result was evaluated immediately after completing the treatment protocol. However, as Vinciullo et al reported,²⁶ a better response throughout time could be expected since further gradual improvement in cosmetic results is not uncommon.

We found no significant relationship between response rate to PDT and patients' age, sex, and localization of the tumor, mean diameter of the lesions, and clinical type of BCC. The only variable that had a significant relationship with response rate was history of radiotherapy. In other words,

response rate was lower in patients with a positive history of radiotherapy. To our knowledge, this relationship has not been evaluated and reported to date. However, further studies are required to confirm such an association.

At last, it should be mentioned that BCC is not a life threatening cancer. Therefore, different factors such as efficacy, cosmetic results, patient's opinion and cost effectiveness should be considered in determining the treatment of choice for each patient. Weston et al, showed that patients prefer PDT over conventional therapies of BCC²⁷ and its cost effectiveness has been proven, too²⁸. Regarding these points, in addition to high efficacy and better cosmetic results, PDT can be a suitable therapeutic option for patients with BCC, especially sBCC. However, we had some limitations in this study; for example, we could not perform biopsy after completion of the treatment for all lesions because of ethical issues. Further studies are recommended to compare different regimens of PDT and factors that improve its efficacy.

References

1. Kuijpers DI, Thissen MR, Neumann MH. Basal cell carcinoma treatment options and prognosis, a scientific approach to a common malignancy. *Am J Clin Dermatol* 2002; 3:247-59.
2. Rhodes LE, Rie M, Enstrom Y, Groves R, Morken T, et al. Photodynamic therapy using topical methyl aminolevulinate vs surgery for nodular basal cell carcinoma. *Arch Dermatol* 2004; 140:17-23.
3. Szeimies RM, Karrer S. Towards a more specific therapy: targeting nonmelanoma skin cancer cells. *Br J Dermatol* 2006; 154(S1):16-21.
4. Tierney E, Barker A, Ahdout J, Hanke CW, Moy RL, Kouba DJ. Photodynamic therapy for the treatment of cutaneous neoplasia, inflammatory disorders, and photoaging. *Dermatol Surg* 2009; 35: 725-46.
5. Kaviani A, Ataie-Fashtami L, Fateh M, Sheikhbahaei N, Ghodsi M, Zand N, Djavid GE. Photodynamic therapy of head and neck basal cell carcinoma according to different clinicopathologic features. *Lasers Surg Med* 2005; 36:377-82.
6. Horn M, Wolf P, Wulf HC, Warloe T, Fritsch C, Rhodes LE, et al. Topical methyl aminolaevulinate photodynamic therapy in patients with basal cell carcinoma prone to complications and poor cosmetic outcome with conventional treatment. *Br J Dermatol* 2003; 149:1242-9.
7. Soler AM, Warloe T, Berner A, Giercksky KE. A follow-up study of recurrence and cosmesis in completely responding superficial and nodular basal cell carcinomas treated with methyl 5-aminolaevulinate-based photodynamic therapy alone and with prior curettage. *Br J Dermatol* 2001; 145: 467-71.
8. Soler AM, Warloe T, Tausjø J, Giercksky KE. Photodynamic therapy for residual and recurrent basal cell carcinoma after radiotherapy using topical 5-aminolevulinic acid or methylester aminolevulinic acid. *Acta Oncol* 2000; 39:605-9.
9. Itkin A, Gilchrist BA. Aminolevulinic acid blue light photodynamic therapy for treatment of multiple basal cell carcinomas in two patients with nevoid basal cell carcinoma syndrome. *Dermatol Surg* 2004; 30:1054-61.
10. Chapas AM, Gilchrist BA. Broad area photodynamic therapy for treatment of multiple basal cell carcinomas in a patient with nevoid basal cell carcinoma syndrome. *J Drug Dermatol* 2006; 5(S2):3-5.
11. Madan V, Lancaster JA, Allan D, Lear JT, et al. Nodular basal cell carcinoma in Gorlin's syndrome treated with systemic photodynamic therapy and interstitial optical fiber diffuser laser. *J Am Acad Dermatol* 2006; 55: S86-9.
12. Braathen LR, Szeimies RM, Basset-Seguín N, Bissonnette R, Foley P, et al. Guidelines on the use of photodynamic therapy for nonmelanoma skin cancer: an international consensus. *International Society for Photodynamic Therapy in Dermatology*, 2005. *J Am Acad Dermatol* 2007; 56: 125-43.
13. Perrett CM, McGregor JM, Warwick J, Karran P, Leigh IM, Proby CM, Harwood CA. Treatment of post-transplant premalignant skin disease. A randomized inpatient comparative study of 5-fluorouracil cream and topical phototherapy. *Br J Dermatol* 2007; 156: 320-8.
14. Wulf HC, Pavel S, Stender I, Bakker-Wensveen CA. Topical photodynamic therapy for prevention of new skin lesions in renal transplant recipients. *Acta Derm Venereol* 2006; 86:25-8.
15. Calzavara-Pinton PG. Repetitive photodynamic therapy with topical aminolaevulinic acid as an appropriate approach to the routine treatment of superficial non-melanoma tumours. *J Photochem Photobiol B* 1995; 29: 53-7.
16. Fai D, Arpaia N, Romano I, Vestita M, Cassano N, Vena GA. Methyl-aminolevulinate photodynamic therapy for the treatment of actinic keratoses and non-melanoma skin cancers: a retrospective analysis of response in 462 patients. *G Ital Dermatol Venereol* 2009; 144: 281-5.
17. Bernard P, Dupuy A, Brun P, Sasko A, Duru G, Nicoloyannis N, Decuyper L, Grob JJ. Therapeutic modalities and economic assessment in the treatment of superficial basal cell carcinomas and multiple actinic keratoses by French dermatologists. *Ann Dermatol Venereol* 2007; 134: 527-33.
18. Madan V, West CA, Murphy JV, Lear JT. Sequential treatment of giant basal cell

- carcinomas. *J Plast Reconstr Aesthet Surg* 2009; 62: e368-72.
19. Wolf P, Rieger E, Kerl H. Topical photodynamic therapy with endogenous porphyrins after application of 5-aminolevulinic acid. An alternative treatment modality for solar keratoses, superficial squamous cell carcinomas, and basal cell carcinomas? *J Am Acad Dermatol* 1993;28: 17-21.
 20. Mosterd K, Thissen MR, Nelemans P, Kelleners-Smeets NW, Janssen RL, et al. Fractionated 5-aminolaevulinic acid-photodynamic therapy vs. surgical excision in the treatment of nodular basal cell carcinoma: results of a randomized controlled trial. *Br J Dermatol* 2008;159: 864-70.
 21. Kuijpers DJ, Thissen MR, Thissen CA, Neumann MH. Similar effectiveness of methyl aminolevulinic acid and 5-aminolevulinic acid in topical photodynamic therapy for nodular basal cell carcinoma. *J Drugs Dermatol* 2006; 5: 642-5.
 22. Thompson MS, Andersson-Engels S, Svanberg S, Johansson T, Palsson S, et al. Photodynamic therapy of nodular basal cell carcinoma with multifiber contact light delivery. *J Environ Pathol Toxicol Oncol* 2006; 25:411-24.
 23. Wang I, Bendsoe N, Klinteberg CA, Enejder AM, et al. Photodynamic therapy vs. cryosurgery of basal cell carcinomas: results of a phase III clinical trial. *Br J Dermatol* 2001; 144:832-40.
 24. Fayer D, Corbett M, Heirs M, Fox D, Eastwood A. A systematic review of photodynamic therapy in the treatment of pre-cancerous skin conditions, Barrett's oesophagus and cancers of the biliary tract, brain, head and neck, lung, oesophagus and skin. *Health Technol Assess* 2010; 14: 1-288.
 25. Basset-Seguin N, Ibbotson SH, Emtestam L, Tarstedt M, Morton C, Maroti M, Calzavara-Pinton P, Varma S, Roelandts R, Wolf P. Topical methyl aminolaevulinic acid photodynamic therapy versus cryotherapy for superficial basal cell carcinoma: a 5 year randomized trial. *Eur J Dermatol* 2008; 18:547-53.
 26. Vinciullo C, Elliott T, Francis D, Gebauer K, Spelman L, Nguyen R, Weightman W, et al. Photodynamic therapy with topical methyl aminolaevulinic acid for 'difficult-to-treat' basal cell carcinoma. *Br J Dermatol* 2005; 152:765-72.
 27. Weston A, Fitzgerald P. Discrete choice experiment to derive willingness to pay for methyl aminolevulinic acid photodynamic therapy versus simple excision surgery in basal cell carcinoma. *Pharmacoeconomics* 2004; 22:1195-208.
 28. Caekelbergh K, Annemans L, Lambert J, Roelandts R. Economic evaluation of methyl aminolaevulinic acid-based photodynamic therapy in the management of actinic keratosis and basal cell carcinoma. *Br J Dermatol* 2006; 155:784-90.