

Twenty nail dystrophy associated with lichen planus in a child: A case report

Manisha Makkar, MD
Pinki Pandey, MD
Alok Dixit, MD
Kalyani Kapur, MD
NC Mahajan, MD

*Department of pathology, MM Institute
of Medical Sciences and Research,
Mullana 133203, Ambala, India*

*Corresponding author:
Pinki Pandey, MD
Department of pathology, MM Institute
of Medical Sciences and Research,
Mullana 133203, Ambala, India
Email: pnkdxt@yahoo.co.in*

Conflict of interest: None to declare

*Received: February 5, 2011
Accepted: May 24, 2011*

Twenty Nail Dystrophy (TND) is a rare acquired idiopathic nail dystrophy characterized by excess longitudinal ridging, distal notching, splitting, loss of nail luster and thinning of nail plates that may affect 1 to 20 nails. It occurs as a common manifestation of various dermatoses affecting the nail unit like lichen planus, psoriasis, atopic dermatitis, onychomycosis, vitiligo and alopecia areata, but isolated cases without an associated disease are rare. TND is a manifestation of diverse underlying processes; therefore its histology will vary; however, histologic data on TND are only available in very few published reports. We are documenting the histologic features of TND in a 12-year-old boy who presented with thin rough opaque lusterless nail plates with longitudinal ridging of the twenty nails without any systemic involvement.

Keywords: lichen planus, twenty nail dystrophy, trachyonychia

Iran J Dermatol 2011; 14: 113-116

INTRODUCTION

Twenty Nail Dystrophy (TND) is a rare acquired idiopathic nail dystrophy characterized by excess ridging and loss of nail luster that may affect 1 to 20 nails. The term twenty nail dystrophy was introduced by Samman in 1965 and further emphasized by Hazelrigg et al in 1977¹. It may occur either as an isolated nail abnormality, as well as a common manifestation of various dermatoses affecting the nail unit². TND is a manifestation of diverse underlying processes; therefore, its histology will vary. However, histologic data on TND are only available in very few published reports³. We are documenting the histologic features of TND in a 12-year-old boy who presented with thin rough opaque lusterless nail plates with longitudinal ridging of the twenty nails without any systemic involvement.

CASE REPORT

A 12-year-old boy was visited at our dermatology

department with dystrophy of all twenty nails for nine months. The changes were first noted in the finger nails followed by similar involvement of the toe nails. Nail examination was quite conspicuous and revealed the presence of alternating elevations and depressions (ridging) and/or pitting, lack of luster, roughening (similar to a sandpaper),

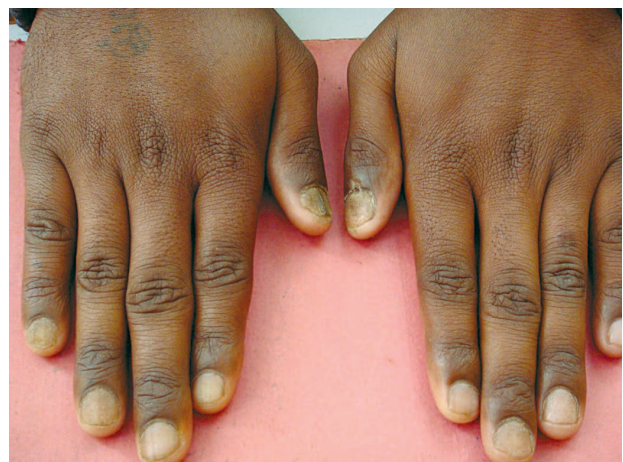

Figure 1. Rough, opaque, lusterless nails showing nail thinning and longitudinal striations on the finger nails.

splitting and a muddy, grayish-white color discoloration involving all the nails of the fingers and toes (Figures 1, 2). Skin lesions were absent and no mucosal involvement was detected. Both drug and family histories were unremarkable. Past medical history and review of systems were noncontributory. On the physical examination, there were no signs of eczema, lichen planus or psoriasis. Culture for dermatophytes and yeasts were negative. Routine tests including liver and renal function tests were normal.

A biopsy specimen of the nail matrix was obtained from the lateral portion of the right middle finger measuring 0.1 cm in length. The biopsy specimen was processed and hematoxylin-eosin stained sections were prepared. Histological examination

revealed marked changes confined primarily to the epidermis. They were apparent in the form of hyperkeratosis and a corresponding prominent hypertrophy of the stratum granulosum. There were numerous relatively coarse keratohyaline granules associated with marked acanthosis affecting the stratum malpighii and rete ridges. Vacuolar degeneration of the basal cell layer was notable in various areas. The papillary dermis showed band-like mononuclear cell infiltrates (Figures 3). Few necrotic keratinocytes (civatte bodies) were also seen (Figure 4). The morphological changes and histologic findings were fairly conducive to form the diagnosis of twenty nail dystrophy associated with lichen planus.

DISCUSSION

Twenty nail dystrophy (TND), also known as trachyonychia, is seen in adults and rarely in children. It is known to affect both genders. It is a clinical entity and describes a spectrum of nail plate surface abnormalities resulting in nail roughness. It is characterized by loss of luster, thinning of nail plates, bluish brown discoloration, longitudinal ridging, distal notching and splitting. Excessive longitudinal ridging is the hallmark of TND⁴. However, all 20 nails need not be affected, and as few as 1 or as many as 20 nails may be affected. Nail dystrophy may develop simultaneously in all nails, but also develops insidiously over a longer period of time⁵.

It is a rare disease with only a handful of reports

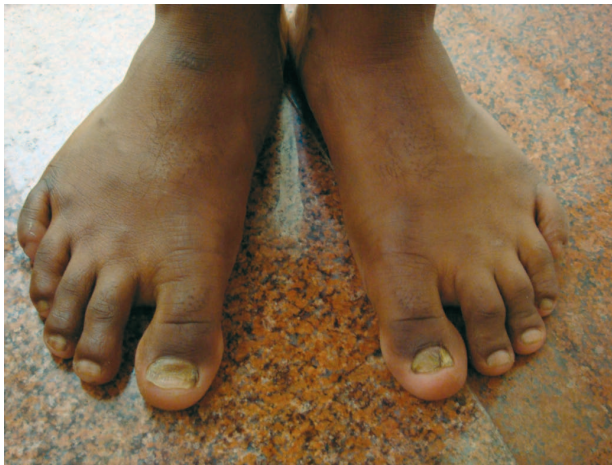

Figure 2. Rough, opaque, lusterless nails showing nail thinning and longitudinal striations on the toe nails.

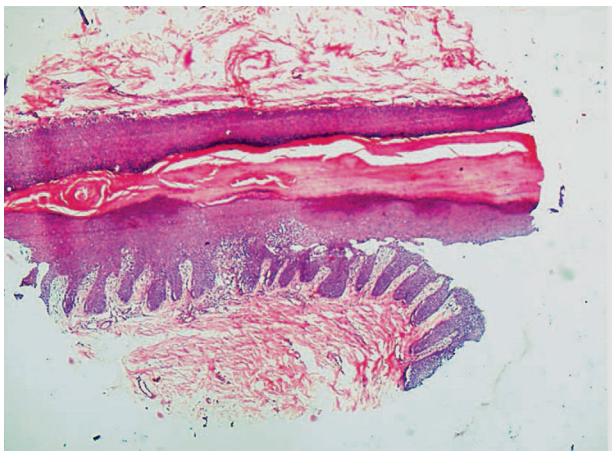


Figure 3. Photomicrograph of proximal nail fold and nail matrix showing hyperkeratosis, hypergranulosis, vacuolar alteration of basal layer and the lymphocytic inflammatory infiltrate accentuated at the base of the rete ridges. (H&E*40)

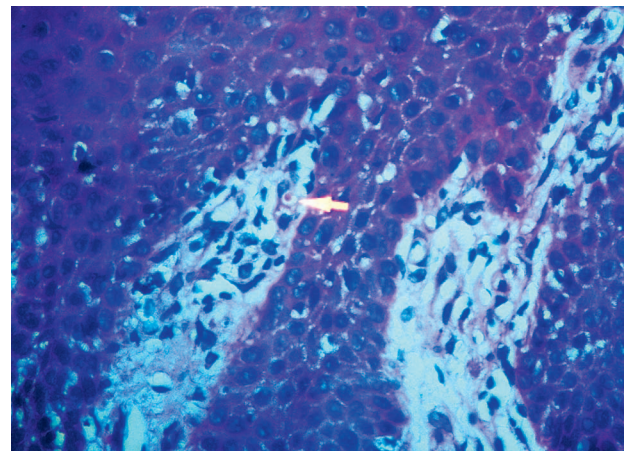


Figure 4. Photomicrograph showing pink staining necrotic keratinocytes (civatte bodies) (arrow) in papillary dermis. (H&E*400)

in literature which are associated with lichen planus, eczema, psoriasis and alopecia areata. Isolated cases without an associated disease are still rare ^{3,5,6}. In our case, personal and family histories for any other cutaneous or systemic disease were unremarkable. Also, the rest of the cutaneous and systemic examination was normal.

Its clinical appearance might vary in the degree of the severity of the nail dystrophy ⁷. It is an inflammatory disorder of the nail unit characterized by nail plate roughness associated with longitudinal ridging that may give the nails an opaque sandpapered appearance or less frequently, diffuse regular superficial pits may make the nails shiny. These nail changes may be accompanied by a grey opaqueness of the nail plate which becomes brittle and splits at the free edge ⁸.

Although the clinical features are highly suggestive, histopathological examination is required to confirm the diagnosis. Histologically, there is compact orthokeratosis and wedge shaped hypergranulosis. The granular cells appear increased in size and contain coarse and more abundant keratohyaline granules. The acanthosis is irregular and affects spinous layer of the rete ridges as well as the suprapapillary plates. The rete ridges show irregular lengthening and some of them are pointed at lower end giving a saw tooth appearance. The basal layer shows vacuolar alteration and necrosis of basal keratinocytes. The infiltrate in upper dermis is band-like and is composed entirely of lymphocytes intermingled with macrophages. Necrotic keratinocytes are present in most cases of lower epidermis and papillary dermis. They are also referred to as colloid, hyaline, cytoid or civatte bodies. They average 20µm in diameter and have a homogenous eosinophilic appearance and are Periodic Acid-Schiff (PAS) positive and diastase-resistant. All the above features were present in our case. However, as TND is a manifestation of diverse underlying processes, its histology will vary. Spongiosis may be prominent in cases associated with atopic dermatitis. Although very few published reports have included histologic findings on TND, Tosti et al ³ reported the clinical features and pathological findings of 23 patients with TND/idiopathic trachyonychia; more than 80% of the nail biopsy specimens revealed focal spongiotic changes, and the rest of the cases showed psoriasiform or lichen planus compatible

features. They concluded that disturbance of nail matrix kinetics secondary to various underlying inflammatory disorders may be responsible for the development of these nail changes, raising the possibility that the degree of inflammation directly correlates with the severity of nail changes. They also concluded that TND may involve all 20 nails or be limited to one or several digits. This may explain the different degrees of nail involvement in our patient.

TND may be caused by several inflammatory diseases that disturb nail matrix keratinization such as lichen planus, psoriasis, eczema, pemphigus vulgaris and alopecia areata. There are no clinical criteria to distinguish trachyonychia caused by different inflammatory skin diseases. In order to make a correct diagnosis, longitudinal nail biopsy involving the proximal nail matrix is necessary. Patients with only nail involvement should also be examined for other nail disorders, especially for psoriasis. Nail changes in psoriasis consist mainly of onycholysis and pitting of the nail plate which may be opaque, thickened at its distal edge and detached so that finger assumes a rush-pith like appearance ⁵.

TND differs from typical nail involvement in lichen planus because of its monomorphic appearance, i.e. longitudinal ridging affects the nail plate surface uniformly involving all the 20 nails and no longitudinal splitting or pterygium are seen. In TND due to lichen planus, clinical nail changes resemble those seen in lichen planus but other manifestations of lichen planus are usually absent.

As the etiology and pathogenesis of TND remains unclear, there has not been a successful treatment yet. TND is believed to be self-limiting and in often resolves spontaneously in children. However, various treatment modalities have been tried like topical steroids alone or in combination with salicylic acid and tretinoin, intralesional and systemic steroids, topical 5-fluorouracil, griseofulvin and tazarotene with variable success ^{1,3,9}. Our case is being treated with oral griseofulvin (10mg/kg body weight in divided doses) for a period of 6 months to be followed up every month until the completion of treatment and there seems to be an apparent restoration of nails. However, the cornerstone of therapy is intralesional corticosteroid therapy ¹⁰. If this regimen fails, oral steroid is used to arrest

inflammation and prevent scarring. Triamcinolone acetonide can be given intramuscularly at a dose of 0.5-1mg/kg/month for 3-6 months^{5,11}. Even topical PUVA has been used successfully for the treatment of finger nails in a patient with TND.

As TND is a rare disorder and very few cases of TND have been histologically proved, we felt it was necessary to report the histologic findings of TND associated with lichen planus in our patient. Early recognition, treatment and diagnosis is very important for both the patient and the care provider.

REFERENCES

1. Hazelrigg DE, Duncan WC, Jarratt M. Twenty- nail dystrophy of childhood. *Arch Dermatol* 1977; 113:73-5.
2. Tosti A, Fanti PA, Morelli R, Bardazzi F. Spongiotic Trachonychia. *Arch Dermatol* 1991; 127: 584-5.
3. Tosti A, Bardazzi F, Piraccini BM, Fanti PA. Idiopathic trachonychia (twenty- nail dystrophy): A pathological study of 23 patients. *Br J Dermatol* 1994; 131:866-72.
4. Nandedkar-Thomas MA, Scher RK. An update on disorders of the nails. *J Am Acad Dermatol* 2005; 52: 877-87.
5. Tosti A, Piraccini BM, Cambiaghi S, Jorizzo M. Nail lichen planus in children: clinical features, response to treatment, and long term follow-up. *Arch Dermatol* 2001; 137: 1027-32.
6. Sehgal VN, Sharma S, Khandpur S. Twenty-nail dystrophy originating from lichen planus. *Skinmed* 2005;4:58-9.
7. Grover C, Khandpur S, Reddy BS, Chaturvedi KU. Longitudinal nail biopsy: utility in 20-nail dystrophy. *Dermatol Surg* 2003; 29:1125-9.
8. Baran R, Dawber RP, Richert B. Physical signs. In: Baran R, Dawber RP, de Berker DA, Haneke E, Tosti A, editors. *Diseases of the Nails and their Management*. London: Blackwell Science; 2001:67-9.
9. Soda R, Diluviol L, Bianchi L, Chimenti S. Treatment of trachonychia with tazarotene. *Clin Exp Dermatol* 2005; 30: 301-2.
10. Khandpur S, Reddy BS. An association of twenty- nail dystrophy with vitiligo. *J Dermatol* 2001; 28: 38-42.
11. Khoo BP, Giam YC. A pilot study on the role of intralesional triamcinolone acetonide in the treatment of pitted nails in children. *Singapore Med J* 2000; 41: 66-8.