Case report: sporotrichoid form of lupus vulgaris

Mousumi Roy Bandyopadhyay, MD
DN Gangopadhyay, MD
Somnath Sarkar, MD
Mrinal Besra, MD

Department of Dermatology, School of Tropical Medicine, Kolkata, India

Corresponding Author:
Mousumi Roy Bandyopadhyay, MD
Department of Dermatology, School of Tropical Medicine, Kolkata, India
Email: mousumi_pgi@rediffmail.com

Conflict of interest: none to declare

Received: 20 February 2014
Accepted: 3 May 2014

Lupus vulgaris, a common form of cutaneous tuberculosis, usually has different patterns including the plaque form, ulcerative and mutilating form, vegetative form, tumor-like form, and papular and nodular form. Lupus vulgaris commonly appears on the normal skin as a solitary lesion. However, certain uncommon forms are identified that pose a diagnostic dilemma. Sporotrichoid-like spread has been rarely reported. Atypical presentations of cutaneous tuberculosis are not very uncommon but are frequently overlooked in the clinical practice, leading to a late diagnosis and increased morbidity. We report two cases of lupus vulgaris with a sporotrichoid pattern. Our patients presented with the characteristic morphologic features of lupus vulgaris (LV) in a different distribution pattern. The diagnosis was supported by laboratory investigations, histopathological examination, and an excellent response to antitubercular therapy. Both cases demonstrated a linear arrangement of lesions mimicking sporotrichosis. We emphasize that cutaneous tuberculosis can occur in an unusual form in an immunocompetent person. The aim of this communication is to bring this often overlooked but definitely curable clinical entity to attention.

Keywords: cutaneous tuberculosis, lupus vulgaris, Mycobacterium tuberculosis, sporotricoid form

Iran J Dermatol 2014; 17: 72-75

INTRODUCTION

Lupus vulgaris is an extremely chronic and progressive form of skin tuberculosis that occurs in individuals with moderate to high degrees of immunity to *Mycobacterium tuberculosis* [1]. It is the most common variant of cutaneous tuberculosis accounting for about 59% of secondary skin tuberculosis cases in India, with an average prevalence of 0.37% among skin patients [2]. The disease is acquired either exogenously by direct inoculation of the bacilli into the skin or endogenously by activation of a dormant focus. The face is the most commonly affected site in Western countries with frequent involvement of the nose and cheeks. In India, however, lower extremities, especially the buttocks, are most frequently affected [3]. Clinically, lupus vulgaris presents in five general patterns: plaque form, ulcerative and mutilating form, vegetative form, tumor-like form, papular and nodular form [4]. Unusual forms, such as frambesiform, gangrenous, or ulcerovegetating types have also been reported [5]. Lupus vulgaris commonly appears on the normal skin as a solitary lesion although it may develop at the site of a primary inoculation, in the scar of scrofuloderma, or at the site of a BCG vaccination [6,7]. Sporotrichoid-like spread has been rarely reported [1]. Atypical presentations of cutaneous tuberculosis are not very uncommon but are frequently overlooked in the clinical practice, leading to a late diagnosis and increased morbidity. We report two cases of lupus vulgaris with a sporotrichoid pattern.

CASE REPORT

Case 1

A 44-year-old female presented with asymptomatic, gradually progressive multiple ulcerated

plaques on the right hand and forearm appearing one after another following trauma in a linear pattern of 7 months' duration. She had no systemic complaints and her family history was not contributory. Cutaneous examination revealed multiple, well defined, ulcerated erythematous plaques of different sizes with necrosis and irregular areas of scarring in a sporotrichoid pattern on the right hand and forearm (Figure 1a). Lesions were slightly tender. Regional lymphadenopathy was present. Systemic examinations were within normal limits. All the hematologic and biochemical investigations were normal except for an elevated erythrocyte sedimentation rate (50 mm in 1st hr). Tissue smear was negative for both fungi and acid fast bacilli. Mycobacterial culture was positive while fungal culture showed no growth. The Mantoux test was 10 x 12 mm with 5 tuberculin units. Chest x-ray was normal. Histopathological examination revealed tuberculoid granuloma in the papillary dermis. Asteroid body or neutrophilic infiltrations were not present in the section. The features correlated with a diagnosis of Lupus vulgaris (Figure 1b). Hence, the sporotrichoid form of lupus vulgaris was diagnosed. She was also advised to take antitubercular therapy consisting of four drugs (isoniazid, rifampicin, pyrazinamide, ethambutol) for 2 months, followed by two drugs (isoniazid, rifampicin) for the next 4 months. The lesions started healing after one month and subsequently resolved completely with puckered scarring (Figure 1c).

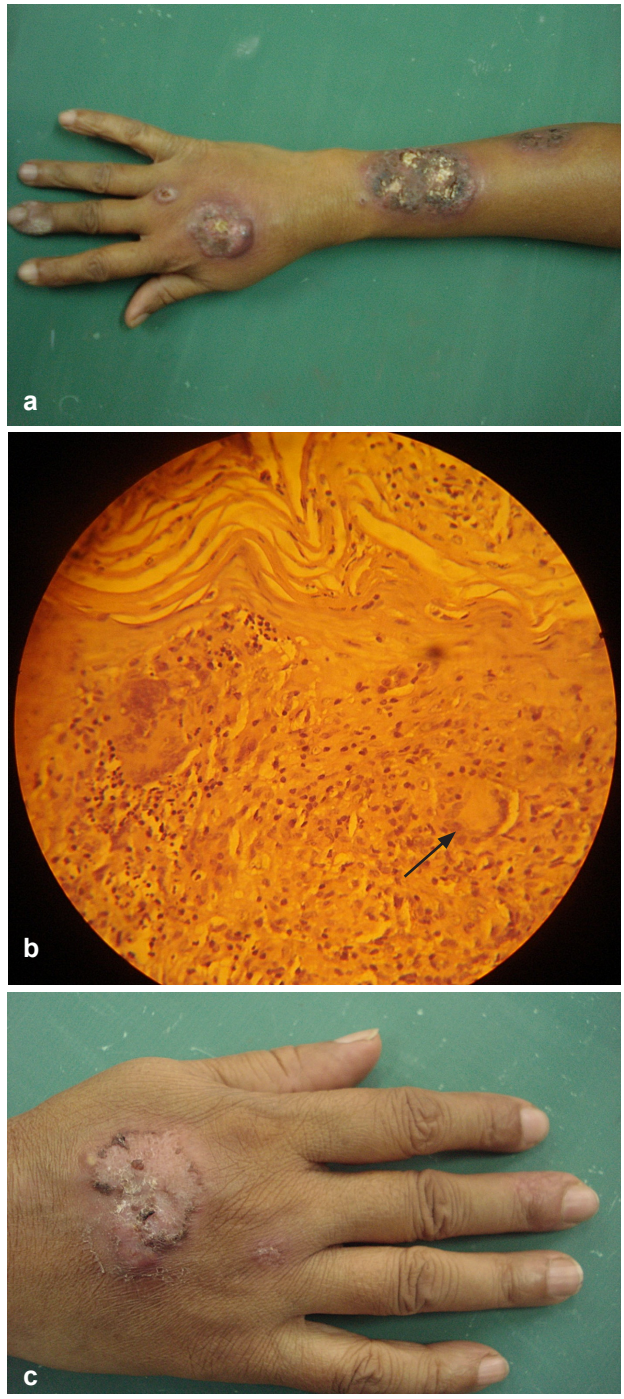

Figure 1. (a) Multiple, well defined, ulcerated erythematous plaques with necrosis and irregular areas of scarring in a sporotrichoid pattern over right hand and forearm. **(b)** Microphotograph showing tuberculoid granuloma(arrow) in the papillary dermis. (H&E x40). **(c)** Healing of the lesion after I month of antitubercular therapy.

Case 2

A 56-year-old male presented with asymptomatic, gradually progressive multiple plaques over the right side of the face appearing one after another in a linear pattern of 10 months' duration. He had no systemic complaints and his family history was not contributory. Cutaneous examination revealed multiple, well defined, plaques of different sizes with thick crusts in a sporotrichoid pattern over the right side of the face involving the forehead, nose, right infraorbital region, and right mandibular region (Figure 2a). Regional lymphadenopathy was present. Systemic examination was within normal limits. His ESR was elevated (40 mm/1st hour). Mantoux test showed an induration of 20×15 mm (with 5 tuberculin unit). Chest x-ray was normal. Smear from the biopsy specimen failed to demonstrate any fungus or acid fast bacilli. Tissue smear for leishman bodies was done to rule out cutaneous leishmaniasis which was negative.

Mycobacterial and fungal cultures from the tissue revealed no growth. Histopathologic examination of a plaque revealed tuberculoid granuloma in the papillary dermis. There were no asteroid bodies or neutrophilic infiltrations (Figure 2b). The histopathological features were suggestive of lupus vulgaris. Similar to the first case, he was also advised to take antitubercular therapy consisting of four drugs (isoniazid, rifampicin, pyrazinamide, ethambutol) for 2 months, followed by two drugs (rifampicin and isoniazid) for the next 4 months. The lesions resolved completely at the end of the therapy (Figure 2c).

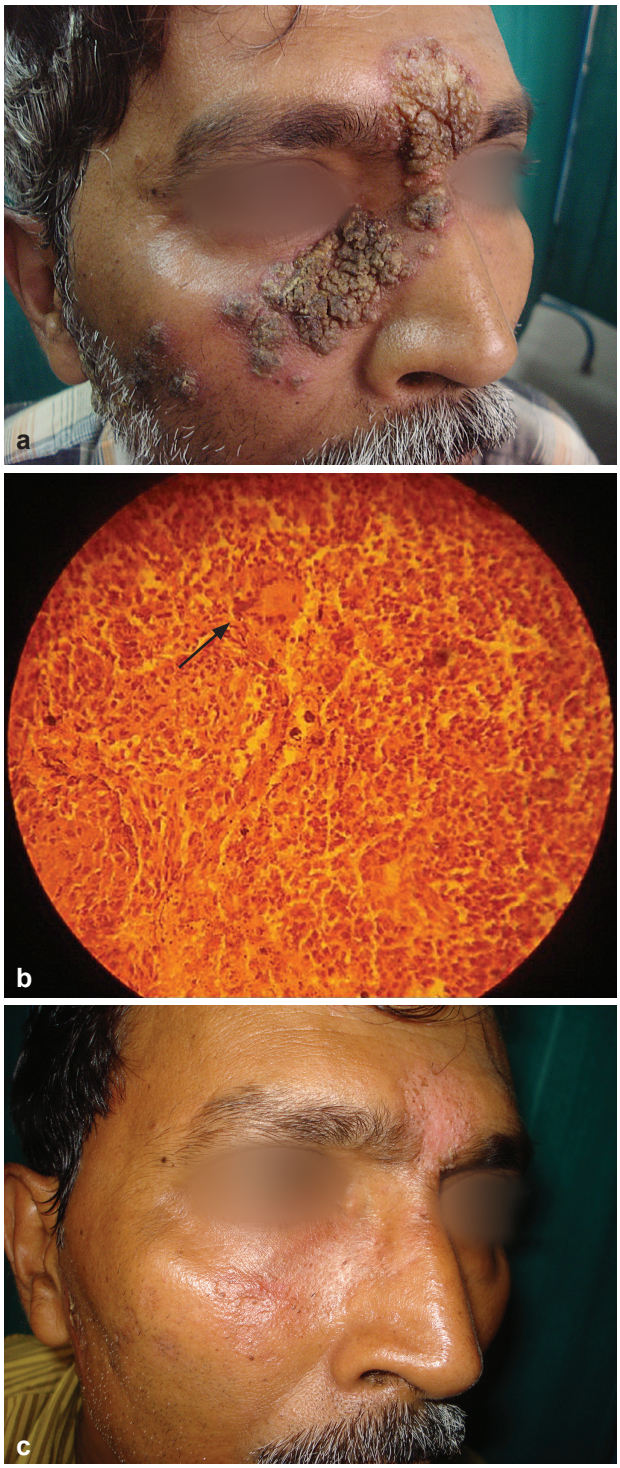

Figure 2. (a) Multiple, well defined, crusted plaques in a sporotrichoid pattern over right side of face. **(b)** Microphotograph showing tuberculoid granuloma (arrow) in the papillary dermis. (H&E x40). **(c)** The lesions resolved completely at the end of the therapy.

DISCUSSION

Lupus vulgaris, a common form of cutaneous tuberculosis, has different patterns including the plaque form, ulcerative and mutilating form, and vegetative form. However, certain uncommon forms are identified that pose a diagnostic dilemma [1]. Our patients presented with the characteristic morphologic features of lupus vulgaris (LV) in a different distribution pattern. The diagnosis was supported by laboratory investigations, histopathological examination, and an excellent response to antitubercular therapy. Both cases demonstrated a linear arrangement of lesions mimicking sporotrichosis, probably as a result of retrograde lymphatic spread of infection from the primary cutaneous site.

Sporotrichosis is a chronic granulomatous mycotic infection of the skin and subcutaneous tissue caused by the dimorphic fungus *Sporothrix schenkii*. The lymphocutaneous type presenting as an ulcerated papule with sequential proximal nodules is the most common clinical presentation. Diagnosis is established by fungal culture and demonstration of characteristic "asteroid bodies" and mixed granulomatous reaction with neutrophil foci on histopathology. Sporotrichoid skin infections refer to conditions that simulate the subcutaneous linear lymphangitic form of sporotrichosis [8]. Several cutaneous disorders show a sporotrichoid distribution. The main conditions that may resemble sporotrichosis are atypical mycobacterial infections and leishmaniasis [9]. Our report describes two cases of lupus vulgaris in a sporotrichoid pattern.

It is a paucibacillary form, cultures being negative [1]. The diagnosis can be established by histopathology, demonstrating tuberculoid granulomas in the superficial dermis. Caseation necrosis is usually sparse or absent [10]. Demonstration

of acid-fast bacilli (AFB) on microscopy and their recovery in culture on the Lowenstein-Jensen (LJ) medium or through guinea pig inoculation are also disappointing in most instances. Therefore, more specific and rapid diagnostic modalities, such as polymerase chain reaction (PCR), can be used; however, at present, the clinician has to rely on clinical and histopathologic correlation for the diagnosis [2]. We emphasize that cutaneous tuberculosis can occur in an unusual form in an immunocompetent person. Strong clinical suspicion, histopathology, and response to anti tubercular drugs are sufficient for diagnosis, especially when culture and PCR are not available or non-contributory.

REFERENCES

1. Saritha M, Parveen BA, Anandan V, et al. Atypical lupus vulgaris. Int J Dermatol 2009;48:150-3.
2. Khandpur S, Nanda S, Reddy BS. An unusual episode of lupus vulgaris masquerading as Sporotrichosis. Int J Dermatol 2001;40:336-9.
3. Jain VK, Aggarwal K, Jain S, Singh S. Hypertrophic lupus vulgaris - an unsual presentation. Indian J Dermatol 2009;54:287-9.
4. Yates VM, Rook GW. Mycobacterial Infections. In: Burns, Breathnach S, Cox N, Griffiths C, eds. Rook's Textbook of Dermatology, 7th edn. Oxford: Blackwell Scientific Publications 2004:28.1-39.
5. Dogliotti R, Leibowitz M, Smith E. Lupus vulgaris. An unusual fungating and ulcerated form in a black South African. Int J Dermatol 1979;18:749-750.
6. Kanwar AJ, Kaur S, Bansal R, et al. Lupus vulgaris following BCG vaccination. Int J Dermatol 1988; 27: 525-6.
7. Handjani F, Delir S, Sodaifi M, Kumar PV. Lupus vulgaris following bacilli Calmette-Guérin vaccination. Br J Dermatol 2001; 144: 444-5.
8. Ramesh V. Sporotrichoid cutaneous tuberculosis. Clin Exp Dermatol 2007; 32: 680-2.
9. Hay RJ, Moore MK. Mycology. In: Burns, Breathnach S, Cox N, Griffiths C, eds. Rook's Textbook of Dermatology, 7th edn. Oxford: Blackwell Scientific Publications 2004:31.1-101.
10. Lever WF, Schaumberg-Lever G. Bacterial diseases. In: Histopathology of the Skin, 7th edn. Philadelphia: JB Lippincott, 1990: 318-51.