

Parameatal urethral cyst of the glans penis: A rare entity

Mrinal Gupta, MBBS, MD, DNB ¹
Anish Gupta, MBBS ²

1. *Sudhaa Skin Centre, Jammu,
Jammu and Kashmir, India*

2. *Acharya Shri Chander College of
Medical Sciences, Jammu, Jammu
and Kashmir, India*

Corresponding Author:

*Mrinal Gupta, MBBS, MD, DNB
Sudhaa Skin Centre, 35-A, Lane No-7,
Tawi Vihar, Sidhra, Jammu (J&K), India
PIN 180019
Email: drmrinalgupta@yahoo.com*

Conflict of Interest: None to declare

Received: 9 November 2014

Accepted: 10 March 2015

Parameatal urethral cysts are a rare benign condition usually seen in males. They are usually asymptomatic but may produce symptoms like difficulty in micturition, pain during intercourse, urinary retention and distortion of the urinary stream. We report a case of parameatal urethral cyst in a 17 year old male presenting as a spherical clear fluid filled cystic lesion measuring about 0.8 cm in diameter at the external urethral meatus, causing distortion of the urinary stream and poor cosmesis. Complete surgical excision of the cyst was done and no recurrence was observed at 6 months of follow-up.

Keywords: parameatal cyst, glans penis, external urethral meatus cyst

Iran J Dermatol 2015; 18: 69-70

INTRODUCTION

Parameatal urethral cysts are a rare benign entity usually seen in males and rarely in females. They were first described by Thompson and Lantin in 1956 and since then, around 50 cases have been reported in the literature ^{1,2}. These cysts are usually asymptomatic but may produce symptoms like difficulty in voiding, urinary retention, pain during intercourse or micturition, distorted urinary stream, and poor cosmetic ². Herein, we report a case of parameatal cyst in a young male presenting with symptoms of distortion of the urinary stream and poor cosmesis.

CASE REPORT

A 17-year-old boy presented with a painless swelling over the glans penis which he noticed 1 year earlier. The swelling was asymptomatic in the beginning but it was causing distortion of the urinary stream for the last 3 months. The child had a history of needle aspiration of the lesion at another center 6 months earlier which led to the clearance of the cyst at that time, but the lesion

recurred to its present size over the a 6-month period. On examination, a smooth, spherical cystic mass about 0.8 cm in diameter was found at the external urethral meatus (Figure 1). There were no urinary symptoms other than the distorted urinary stream and poor cosmetic. There was no history of trauma or application of topical

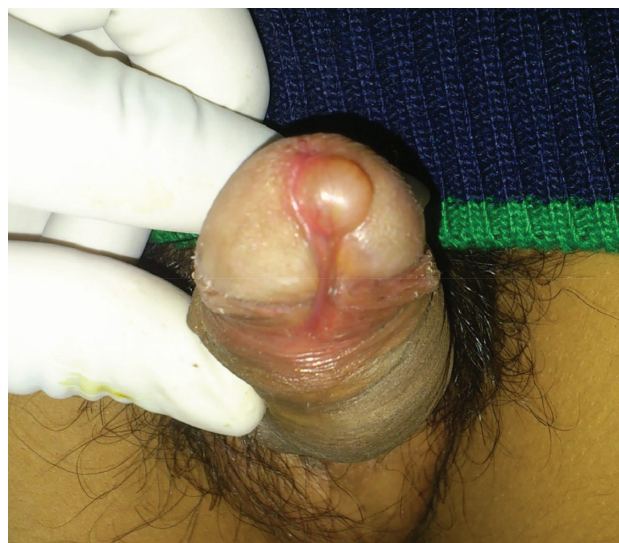

Figure 1. Parameatal urethral cyst in a 17-year-old male.

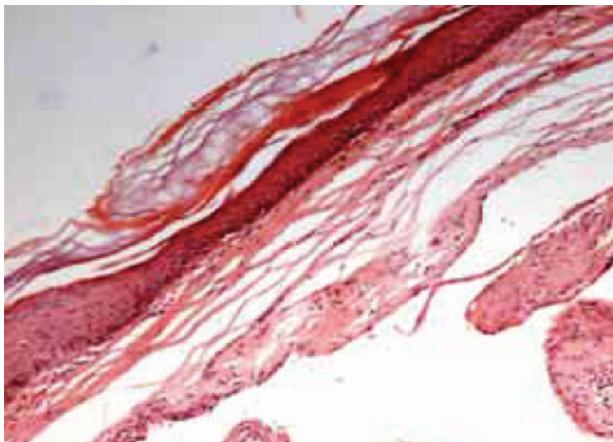


Figure 2. Histology of the excised cyst showing a monolocular cyst lined with pseudo-stratified epithelium without inflammation. (H & E, × 400)

medications. No inflammatory signs were present. On investigations, hematological counts, and liver and renal function parameters were within normal limits. Urine microscopy and urine culture also revealed no abnormality. Complete excision of the cyst under local anesthesia was performed and good cosmetic results were obtained without any urinary flow problems. No recurrence was observed at 6 months follow-up.

Histological examination of the excised cyst showed a monolocular cyst lined with pseudo-stratified epithelium with no evidence of inflammation (Figure 2).

DISCUSSION

Parameatal urethral cysts are a rare entity usually seen in boys but cases among females have also been reported³. Usually they appear spontaneously during the second decade of life but congenital and infantile onsets have also been seen². The etiology of parameatal cysts is still not completely understood. Obstruction of paraurethral ducts, either spontaneous or secondary to infection, has been postulated as one possible factor by a few authors while others believe that parameatal cysts occur in the process of delamination or separation of the foreskin from the glands^{2,4,5}. Ichianagi *et al.*⁶, detected the presence of prostate specific antigen (PSA) in the cells of parameatal cysts, thus giving credibility to the hypothesis that these cysts originate from the accessory male sex glands

in the penile urethra. Soyer *et al.*³, reported two cases of parameatal cysts in newborn females, which were associated with vaginal bleeding and breast enlargement, indicating the possible role of estrogens in their development.

These cysts are usually small, measuring up to 1 cm in diameter. They usually occur on one side of the urinary meatus but bilateral cases have also been reported. Usually the parameatal cysts are asymptomatic but may rarely present with symptoms like difficulty in voiding, urinary retention, pain during intercourse or micturition, distorted urinary stream, and poor cosmesis. If the cyst is traumatized, it may bleed, rupture, or become infected².

Numerous treatment modalities like needle aspiration, marsupialisation, and decapping have been described for their management but complete surgical excision is the treatment of choice owing to lower chances of recurrence and better cosmetic results. Histologically, the cyst wall may be lined with columnar, squamous, or transitional epithelium which varies according to the urethral segment of origin of the lesion^{2,7}.

In conclusion, a parameatal cyst is a benign, usually asymptomatic condition diagnosed on physical examination in which complete surgical excision provides good cosmetic results without recurrence.

REFERENCES

1. Lantin PM, Thompson IM. Parameatal cysts of the glans penis. *J Urol* 1956;76:753-5.
2. Lal S, Ankur A. Parameatal cyst: a presentation of rare case and review of literature. *J Clin Diagn Res* 2013;7:1757-8.
3. Soyer T, Aydemir E, Atmaca E. Paraurethral cysts in female newborns: role of maternal estrogens. *J Pediatr Adolesc Gynecol* 2007;20:249-51.
4. Yoshida K, Nakame Y, Negishi T. Parameatal urethral cysts. *Urology*. 1985;36:490-1.
5. Hill JT, Ashken MH. Parameatal urethral cysts: a review of 6 cases. *Br J Urol* 1977;49:323-5.
6. Ichianagi N, Shibata T, Matsumura T, et al. Immunohistochemical identification of prostate-specific antigen in a parameatal urethral cyst of the glans penis. *Br J Urol* 1998;81:170-1.
7. Aggarwal K, Gupta S, Jain VK, Goel A. Parameatal urethral cyst. *Indian J Dermatol Venereol Leprol* 2008;74:430.