

Cutaneous Infection by *Fusarium Solani* in an Addict Man with Active Hepatitis C

Seyed Amin Mossavi- Ayatollahi, MD¹

Saeedeh Farajzadeh, MD²

Ali Reza Fekri, MD²

Behrooz Vares, MD²

Sahba Fekri²

1- Mycology Department, Medical University, Kerman Medical University, Kerman, Iran

2- Dermatology Department, Afzalipour Hospital, Kerman University of Medical Sciences, Kerman, Iran

Corresponding author:

Saeedeh Farajzadeh, MD

Dermatology Department, Medical University, Kerman Medical University

Email: safaderm@yahoo.com

Received: April 29, 2008

Accepted: February 9, 2009

Abstract

We describe a 31-year-old man, a known case of hepatitis C infection for 11 years, who presented with a chronic non-healing large deep ulcer on the dorsum of the right foot for five months. *Fusarium solani* infection was confirmed by skin biopsy and culture. The biopsy specimen showed an unusually extensive dermal invasion with fungal hyphae. The patient's response to oral itraconazole 100 mg/day for 3 months was excellent. Closed monitoring of liver enzymes was done before and during the treatment course. (*Iran J Dermatol* 2009;12 (Suppl): S12-S15)

Keywords: *Fusarium Solani*, Hepatitis C, Cutaneous Infection

Case Report

A 31-year-old opium addict labour man from Iranshahr, southeast of Iran, was visited at the dermatology clinic of Afzalipour hospital with a non-healing ulcer on the dorsum of his right foot since 5 months ago. The lesion started as a small

reddish papule at the site of a previous insect bite and gradually became ulcerated. The ulcer was irresponsive to usual topical disinfectants and different oral antibiotics. He was a known case of hepatitis C for 11 years but was not on any anti-hepatitis medication. He started smoking opium when he was 16 but he was not an intra-venous drug user.

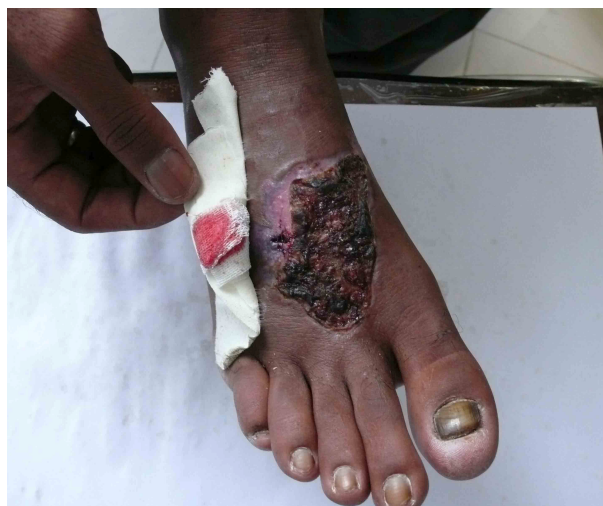

Figure 1a. Foot ulcer due to *fusarium* sp. before treatment

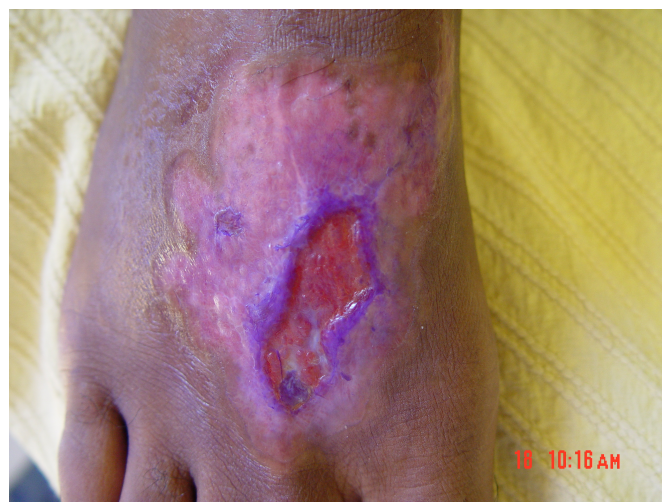

Figure 1b. The same ulcer after two months of itraconazole therapy.

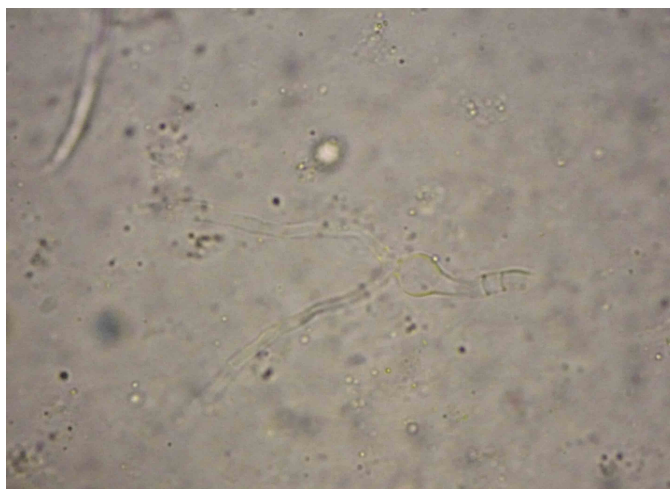

Figure 2. The 40x microscopy view of the mycelium of hyaline hyphomycetes (*Fusarium.sp*) which was separated from the wound exudates (Bar shows 4 μ m).

Skin examination revealed a 7 × 5.5 cm erythematous indurated ulcerated oozing plaque with undermined edges on the dorsum of the right foot (Figure 1). No lymphedema, regional lymphadenopathy and hepatosplenomegaly was noted. The results of routine laboratory tests, including complete blood counts, blood chemistry, serum glucose, immunoglobulin, C3 and C4, and nitroblue tetrazolium test, were all within normal levels. Liver enzymes showed mild elevation (AST: 47 IU/L, ALT: 53 IU/L, Total Bilirubin: 1.5 mg /dl) and INR=1. HCV-Ab and PCR examination for HCV were both positive and HBS-Ag and HBS-Ab and anti HIV-Ab were all negative. Liver biopsy was not performed due to patient's refusal. Chest X-ray and X-rays of foot bones showed normal findings.

Ultrasound evaluation of the liver revealed nothing abnormal. Smear for leishman body was negative and serial routine cultures for microbial strains were negative too. Skin biopsy was performed to rule out cutaneous leishmaniasis, cutaneous tuberculosis, sporotrichosis, and pyoderma gangrenosum. Skin biopsy specimen revealed a chronic inflammatory granulomatous response with no leishman bodies. Periodic Acid-Schiff staining showed some hyphae sparsely distributed in the epidermis and dermis.

Mycological studies via direct smear revealed many hyaline hyphae and unicellular fungal elements (Figure 2). Gram staining showed hyphae of more than 1 mm in diameter and reproductive structures represented by microconidia and chlamydospore-like structures, suggesting a presumptive diagnosis of non-aspergillus hyalohyphomycosis. A biopsy sample was cultured for fungi on Sabouraud agar without cycloheximide

and was incubated at 25°C in air for 4 days on which whitish gray cottony colonies suggestive of *Fusarium* spp grew (Figure 3). Successive subcultures performed on potato dextrose agar in the dark showed sickle shaped multiseptated macroconidia; and one to two-celled microconidia formed from unbranched phialides, conidiophores, and chlamydospores typical of *Fusarium solani*.

According to these findings, the diagnosis of local deep cutaneous infection by *F. solani* was confirmed in this patient.

Upon consultation with a gastroenterologist, itraconazole 100 mg daily PO with close monitoring of liver enzymes started for the patient. Two months after receiving itraconazole, the size of the ulcer and the amount of induration dramatically decreased and by the end of the 3rd month, scar formation was noted (Figure 1a). Diluted potassium permanganate soaks were applied for cleaning the ulcer. Two months after the last dose of itraconazole, a pinkish hypopigmented scar was noted at the site of the previous ulcer. Although mycologic culture of the post-treatment biopsy specimen was not performed, the patient was followed up for 8 months with no clinical signs of recurrence.

Discussion

The genus *Fusarium* includes about 200 species¹. Of those, *F. solani*²⁻⁴, *F. oxysporum*², and *F. moniliforme*⁵ are the most frequently identified organism. *F. solani* is the most common species in *Fusarium* infection and was also the causative organism in our case. Other common infections including cutaneous infections caused by *Fusarium* species can appear in both immunocompromised

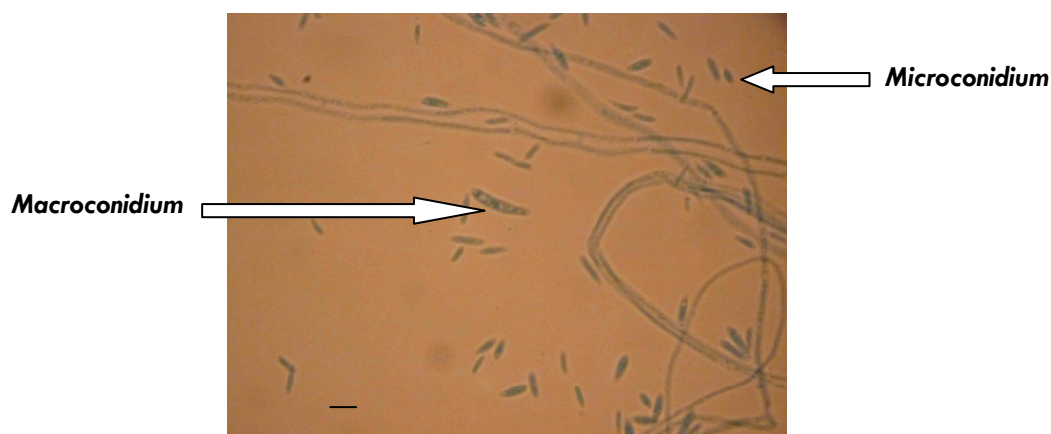


Figure 3. The 40x microscopy view of microconidia and macroconidia of *fusarium*. The bar shows 4 μ m.

and healthy hosts, and can cause colonization, superficial infections and deep cutaneous or subcutaneous and disseminated infections⁶. Disseminated infections mostly occur in immunocompromised hosts such as bone marrow transplant recipients with malignant disorders, renal transplant recipients and patients with chronic granulomatous diseases. Although colonization of skin ulcers, burn eschars and superficial infections of nails and corneal layer are relatively frequent in healthy hosts, deep cutaneous, subcutaneous, and disseminated infections are extremely rare.

Hepatitis C can occur either alone or in conjunction with hepatitis B and HIV infection in some intravenous drug users. Some of the patients with chronic hepatitis B infection may show signs of secondary immunodeficiency⁷. The high frequency of the impairment of immunocompetent cells seen in chronic hepatitis B has been well established as was the appearance of different-temperature autolymphocytotoxins in response to the infection of mono-nuclears in all the disease stages^{7,8}. No immunological disorders in conjunction with chronic hepatitis C infection have been reported, although this virus can penetrate into lymphocytes. Our patient showed no abnormal immunological parameters.

In most cases of local or disseminated diseases in immunocompromised hosts, the organism appears to gain entry through a defective barrier resulting from a surgical or other type of wound, or after an insect bite^{9,10}.

In our case, the patient denied history of any trauma at the onset of the disease except for an insect bite and although he was a known case of hepatitis C, no apparent immunologic deficiency was found. The small erosions due to scratching of the skin may have served as a portal of entry for

the *fusarium* infection. In addition, the patient's apparently intact immune system may have contributed to the localization of the infection.

The characteristic lesion of the disseminated *fusarium* infection in an immunocompromised host is multiple red or gray macules with a central ulceration or black eschars. This lesion causes thrombosis of dermal vessels by fusarial hyphae, subsequent extravasation of erythrocytes, and consequent focal dermal necrosis and epidermal ulceration¹¹. These lesions are present in 60% to 85% of patients and usually appear early in the course of infection^{9,10}. In contrast, a localized skin lesion caused by a deep infection in a healthy host is a slowly enlarging extensive ulcer with cellulitis, or granuloma – like infiltrated erythematous plaques^{9,10}. Such lesions cannot be easily distinguished from those of other deep – seated mycoses such as sporotrichosis or cutaneous leishmaniasis in endemic areas. It is important to make an accurate diagnosis by performing biopsy and cultures.

Antifungal agents such as ketoconazole, fluconazole, amphotericin B, and itraconazole have been used in the treatment of *fusarium* infection¹²⁻¹⁴. However, some of the patients subsequently undergo extensive surgery to stop further progression of the lesion^{15,16}. It has also been reported that continuous local heat therapy with a chemical pocket warmer is effective for various deep fungal infections such as sporotrichosis¹⁷, chromomycosis¹⁸ and *F. solani*^{2,8,19}. We chose itraconazole for treating our patient because of its low liver toxicity. Our patient was a known case of hepatitis C infection with a minimal rise in liver enzyme levels but no signs of liver cirrhosis. Low dose oral Itraconazole (100 mg daily for 3 months) started for the patient and no rise in liver enzymes

from baseline was noted during treatment and after 8 months of follow-up. The patient refused liver biopsy and completely tolerated itraconazole.

The ulcer was completely cured by the end of treatment and left a hypopigmented scar. The patient was followed-up for 8 months. No sign of relapse was noted in the follow-up period after discontinuation of itraconazole.

References

1. Cho CT, Vats TS, Lowman JT, Brandsberg JW, Tosh FE. *Fusarium solani* infection during treatment for acute leukemia. *J Pediatr* 1973; 83:1028-31.
2. Uchiyama N, Shindo Y, Mikoshiba H, Saito H. Cutaneous infection caused by *Fusarium solani* and *Fusarium oxysporum*. *J Dermatol* 1987;14: 471-5.
3. Leu HS, Lee AY, Kuo TT. Recurrence of *Fusarium solani* abscess formation in an otherwise healthy patient. *Infection* 1995; 23:303-5.
4. Nuovo MA, Simmonds JE, Chacho MS, McKittrick JC. *Fusarium solani* osteomyelitis with probable nosocomial spread. *Am J Clin Pathol* 1988;90:738-41.
5. Young NA, Kwon-Chung KJ, Kubota TT, Jennings AE, Fisher RI. Disseminated infection by *Fusarium moniliforme* during treatment for malignant lymphoma. *J Clin Microbiol* 1978;7:589-94.
6. Pereiro M, Abalde MT, Zulaica A, Caeiro JL, et al. Chronic infection due to *Fusarium oxysporum* mimicking lupus vulgaris: case report and review of cutaneous involvement in fusariosis. *Acta Derm Venereol* 2001;81:51-3.
7. Gol'zand IV, Egorov VB, Popova IA. Characteristics of secondary immunologic deficiency in children with chronic hepatitis B and the methods of its correction. *Ter Arkh* 1989;61:72-6.
8. Lauwasser M, Shands JW Jr. Depressed mitogen responsiveness of lymphocytes at skin temperature. *Infect Immun* 1979;24:454-9.
9. Bodey GP, Boktour M, Mays S, Duvic M, et al. Skin lesions associated with *Fusarium* infection. *J Am Acad Dermatol* 2002;47:659-66.
10. Bushelman SJ, Callen JP, Roth DN, Cohen LM. Disseminated *Fusarium solani* infection. *J Am Acad Dermatol* 1995;32:346-51.
11. Maderazo EG, Woronick CL, Albano SD, Breau SP, Pock RM. Inappropriate activation, deactivation, and probable autooxidative damage as a mechanism of neutrophil locomotory defect in trauma. *J Infect Dis* 1986;154:471-7.
12. Ooi SP, Chen TT, Huang TH, Chang HS, Hsieh HY. Granuloma annulare-like skin lesion due to *Fusarium roseum*: therapy with ketoconazole. *Arch Dermatol* 1987;123:167-8.
13. Abramowsky CR, Quinn D, Bradford WD, Conant NF. Systemic infection by *Fusarium* in a burned child; the emergence of a saprophytic strain. *J Pediatr* 1974;84:561-4.
14. Wheeler MS, McGinnis MR, Schell WA, Walker DH. *Fusarium* infection in burned patients. *Am J Clin Pathol* 1981;75:304-11.
15. Hiemenz JW, Kennedy B, Kwon-Chung KJ. Invasive fusariosis associated with an injury by a stingray barb. *J Med Vet Mycol* 1990;28:209-13.
16. Attapattu MC, Anandakrishnan C. Extensive subcutaneous hyphomycosis caused by *Fusarium oxysporum*. *J Med Vet Mycol* 1986;24:105-11.
17. Mackinnon JE, Conti-Diaz LA. The effect of temperature on sporotrichosis. *Sabouraudia* 1962;2:56-9.
18. Yanase K, Yamada M. Pocket warmer therapy of chromomycosis. *Arch Dermatol* 1978;114:1095.
19. Kottapalli B, Wolf-Hall CE, Schwarz P, Schwarz J, Gillespie J. Evaluation of hot water and electron beam irradiation for reducing *Fusarium* infection in malting barley. *J Food Prot* 2003;66:1241-6.